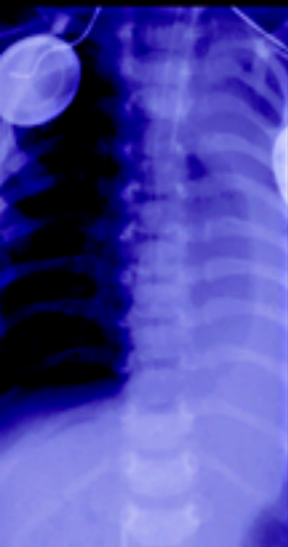


# A-Z of Chest Radiology

Rakesh Misra  
Andrew Planner and  
Mangerira Uthappa



CAMBRIDGE

Medicine

## **A–Z of Chest Radiology**

*A–Z of Chest Radiology* provides a comprehensive, concise, easily accessible radiological guide to the imaging of acute and chronic chest conditions. Organised in A–Z format by disorder, each entry gives easy access to the key clinical features of a disorder.

An introductory chapter guides the reader in how to review chest X-rays accurately. This is followed by a detailed discussion of over 60 chest disorders, listing appearances, differential diagnoses, clinical features, radiological advice and management. Each disorder is highly illustrated to aid diagnosis; the management advice is concise and practical.

*A–Z of Chest Radiology* is an invaluable pocket reference for the busy clinician as well as an aid-mémoire for revision in higher exams in both medicine and radiology.

**Andrew Planner** is a Specialist Registrar in Radiology at John Radcliffe Hospital, Oxford.

**Mangerira C. Uthappa** is a Consultant Radiologist in the Department of Radiology at Stoke Mandeville Hospital, Buckinghamshire Hospitals NHS Trust.

**Rakesh R. Misra** is a Consultant Radiologist in the Department of Radiology at Wycombe Hospital, Buckinghamshire Hospitals NHS Trust.



# A–Z of Chest Radiology

**Andrew Planner**, BSc, MB ChB, MRCP, FRCR

Specialist Registrar in Radiology  
John Radcliffe Hospital, Oxford

**Mangerira C. Uthappa**, BSc, MB BS, FRCS, FRCR

Consultant Radiologist, Stoke Mandeville Hospital  
Buckinghamshire Hospitals NHS Trust

**Rakesh R. Misra**, BSc (Hons), FRCS, FRCR

Consultant Radiologist, Wycombe Hospital  
Buckinghamshire Hospitals NHS Trust

CAMBRIDGE UNIVERSITY PRESS

Cambridge, New York, Melbourne, Madrid, Cape Town, Singapore, São Paulo

Cambridge University Press

The Edinburgh Building, Cambridge CB2 8RU, UK

Published in the United States of America by Cambridge University Press, New York

[www.cambridge.org](http://www.cambridge.org)

Information on this title: [www.cambridge.org/9780521691482](http://www.cambridge.org/9780521691482)

© Cambridge University Press 2007

This publication is in copyright. Subject to statutory exception and to the provision of relevant collective licensing agreements, no reproduction of any part may take place without the written permission of Cambridge University Press.

First published in print format 2007

ISBN-13 978-0-511-33544-0 eBook (NetLibrary)

ISBN-10 0-511-33544-X eBook (NetLibrary)

ISBN-13 978-0-521-69148-2 paperback

ISBN-10 0-521-69148-6 paperback

Cambridge University Press has no responsibility for the persistence or accuracy of urls for external or third-party internet websites referred to in this publication, and does not guarantee that any content on such websites is, or will remain, accurate or appropriate.

For my late father, Charles – a brilliant man! **A. C. P.**

Dedicated to my late father Major M. M. Chinnappa for providing support and inspiration. **M. C. U.**

Dedicated to the next generation; my beautiful children, Rohan, Ela and Krishan. **R. R. M.**



# CONTENTS

<i>List of abbreviations</i>	<i>page x</i>
<b>Part I</b> Fundamentals of CXR interpretation – ‘the basics’	<b>I</b>
Quality assessment	1
Patient-dependent factors	3
Review of important anatomy	7
Lungs and pleura	11
Diaphragms	13
Bones and soft tissues	14
A brief look at the lateral CXR	16
<b>Part II</b> A–Z Chest Radiology	<b>19</b>
Abscess	22
Achalasia	26
Alveolar microlithiasis	28
Aneurysm of the pulmonary artery	30
Aortic arch aneurysm	32
Aortic rupture	36
Asbestos plaques	38
Asthma	42
Bochdalek hernia	46
Bronchiectasis	48
Bronchocele	52
Calcified granulomata	54
Carcinoma	56
Cardiac aneurysm	60
Chronic obstructive pulmonary disease	62
Coarctation of the aorta	66
Collapsed lung	68
Consolidated lung	76



Diaphragmatic hernia – acquired	82
Diaphragmatic hernia – congenital	84
Embolic disease	86
Emphysematous bulla	90
Extrinsic allergic alveolitis	92
Flail chest	96
Foregut duplication cyst	100
Foreign body – inhaled	102
Foreign body – swallowed	104
Goitre	106
Haemothorax	108
Heart failure	110
Hiatus hernia	114
Idiopathic pulmonary fibrosis	118
Incorrectly sited central venous line	122
Kartagener syndrome	124
Lymphangioliomyomatosis	126
Lymphoma	128
Macleod’s syndrome	132
Mastectomy	134
Mesothelioma	136
Metastases	138
Neuroenteric cyst	142
Neurofibromatosis	144
Pancoast tumour	148
Pectus excavatum	152
Pericardial cyst	154
Pleural effusion	156
Pleural mass	162
Pneumoconiosis	164
Pneumoperitoneum	168
Pneumothorax	170
Poland’s syndrome	174
Post lobectomy/post pneumonectomy	176

Progressive massive fibrosis	180
Pulmonary arterial hypertension	182
Pulmonary arteriovenous malformation	184
Sarcoidosis	186
Silicosis	190
Subphrenic abscess	192
Thoracoplasty	194
Thymus – malignant thymoma	196
Thymus – normal	200
Tuberculosis	202
Varicella pneumonia	206
Wegener’s granulomatosis	208
Westermarck’s sign	210

## ABBREVIATIONS

ABC	Airways, breathing and circulation
ABPA	Allergic bronchopulmonary aspergillosis
ACE	Angiotensin converting enzyme
c-ANCA	Cytoplasmic anti neutrophil cytoplasmic antibodies
p-ANCA	Perinuclear anti neutrophil cytoplasmic antibodies
AP	Antero-posterior
ARDS	Adult respiratory distress syndrome
$\alpha$ 1-AT	Alpha-1 antitrypsin
AVM	Arteriovenous malformation
BAC	Broncho-alveolar cell carcinoma
BiPAP	Bilevel positive airway pressure
BOOP	Bronchiolitis obliterating organising pneumonia
CCAM	Congenital cystic adenomatoid malformation
CNS	Central nervous system
COP	Cryptogenic organising pneumonia
COPD	Chronic obstructive pulmonary disease
CT	Computed tomography
3D-CT	3-Dimensional computed tomography
CVA	Cerebrovascular accident
CXR	Chest X-ray
DIP	Desquamative interstitial pneumonitis
EAA	Extrinsic allergic alveolitis
Echo	Echocardiography
ENT	Ear, nose and throat
FB	Foreign body
FEV <sub>1</sub>	Forced expiratory volume in 1 s
FVC	Forced vital capacity
GI	Gastrointestinal
GOJ	Gastro-oesophageal junction
HD	Hodgkin's disease
HRCT	High-resolution computed tomography
HU	Hounsfield unit
IHD	Ischaemic heart disease
IV	Intravenous
IVC	Inferior vena cava
LAM	Lymphangiomyomatosis
LCH	Langerhans' cell histiocytosis
LIP	Lymphocytic interstitial pneumonitis
LV	Left ventricle

M, C & S	Microscopy, culture and sensitivity
MRA	Magnetic resonance angiography
MRI	Magnetic resonance imaging
NBM	Nil by mouth
NF1	Neurofibromatosis type 1
NF2	Neurofibromatosis type 2
NGT	Nasogastric tube
NHL	Non-Hodgkin's lymphoma
NSAID	Non-steroidal Antiinflammatory drug
NSCLC	Non small cell lung cancer
NSIP	Non-specific interstitial pneumonitis
OB	Obliterative bronchiolitis
OGD	Oesophago-gastro duodenoscopy
PA	Postero-anterior
$p\text{CO}_2$	Partial pressure of carbon dioxide
PCP	Pneumocystis pneumonia
PDA	Patent ductus arteriosus
PE	Pulmonary embolus
PEEP	Positive end expiratory pressure ventilation
PET	Positron emission tomography
PMF	Progressive massive fibrosis
$p\text{O}_2$	Partial pressure of oxygen
PPH	Primary pulmonary hypertension
PUO	Pyrexia of unknown origin
RA	Rheumatoid arthritis
RA	Right atrium
RBILD	Respiratory bronchiolitis interstitial lung disease
R-L shunt	Right to left shunt
RTA	Road traffic accident
RV	Right ventricle
<i>S. aureus</i>	<i>Staphylococcus aureus</i>
SCLC	Small cell lung cancer
SOB	Shortness of breath
SVC	Superior vena cava
T <sub>1</sub>	T <sub>1</sub> weighted magnetic resonance imaging
T <sub>2</sub>	T <sub>2</sub> weighted magnetic resonance imaging
TB	Tuberculosis
TIA	Transient ischaemic attack
TOE	Trans-oesophageal echocardiography
UIP	Usual interstitial pneumonitis
US	Ultrasound
$\dot{V}/\dot{Q}$	Ventilation/perfusion scan
VSD	Ventricular septal defect



# FUNDAMENTALS OF CXR INTERPRETATION – ‘THE BASICS’

## PART

# I

• QUALITY ASSESSMENT	1
• PATIENT-DEPENDENT FACTORS	3
• REVIEW OF IMPORTANT ANATOMY	7
• LUNGS AND PLEURA	11
• DIAPHRAGMS	13
• BONES AND SOFT TISSUES	14
• A BRIEF LOOK AT THE LATERAL CXR	16

When interpreting a CXR it is important to make an assessment of whether the x-ray is of diagnostic quality. In order to facilitate this, first pay attention to two radiographic parameters prior to checking for pathology; namely the *quality* of the film and *patient-dependent factors*. A suboptimal x-ray can mask or even mimic underlying disease.

## Quality assessment

### ***Is the film correctly labelled?***

This may seem like an obvious statement to make. However, errors do occur and those relating to labelling of the radiograph are the most common.

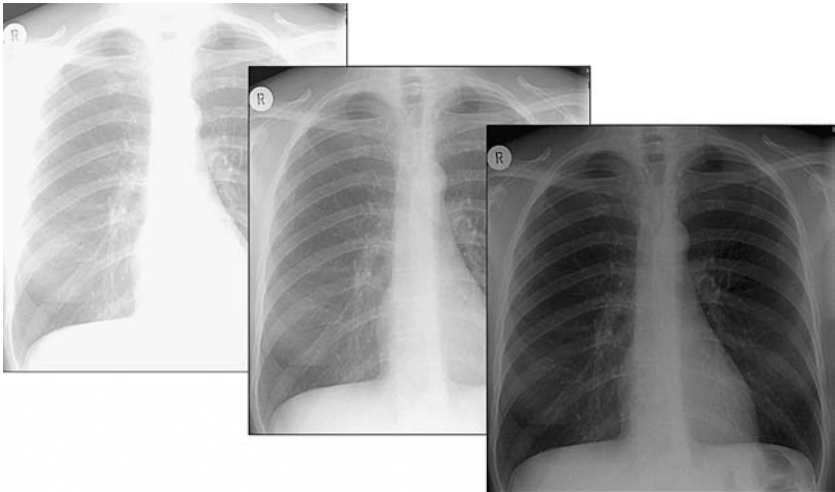
What to check for?

- Does the x-ray belong to the correct patient? Check the patient's name on the film.
- Have the left and right side markers been labelled correctly, or does the patient really have dextrocardia?
- Lastly has the projection of the radiograph (PA vs. AP) been documented?

## Assessment of exposure quality

Is the film penetrated enough?

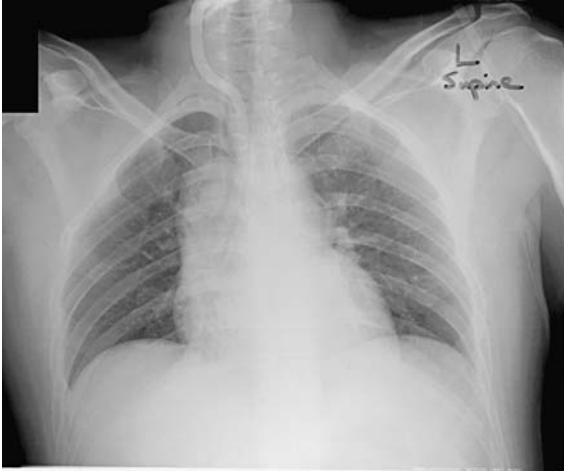- On a high quality radiograph, the vertebral bodies should just be visible through the heart.
- If the vertebral bodies are not visible, then an insufficient number of x-ray photons have passed through the patient to reach the x-ray film. As a result the film will look ‘whiter’ leading to potential ‘overcalling’ of pathology.
- Similarly, if the film appears too ‘black’, then too many photons have resulted in overexposure of the x-ray film. This ‘blackness’ results in pathology being less conspicuous and may lead to ‘undercalling’.



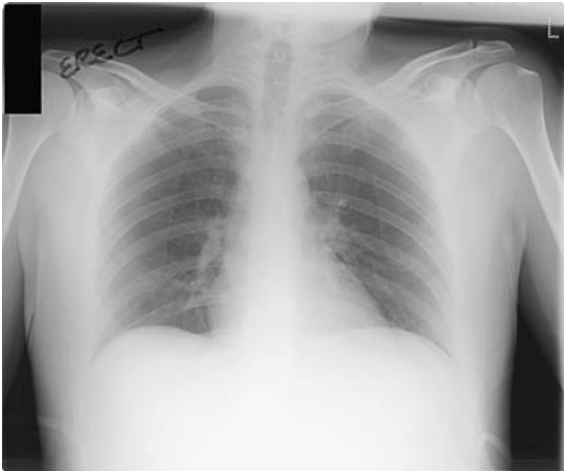The effect of varied exposure on the quality of the final image.

## Is the film PA or AP

- Most CXRs are taken in a PA position; that is, the patient stands in front of the x-ray film cassette with their chest against the cassette and their back to the radiographer. The x-ray beam passes through the patient from back to front (i.e. PA) onto the film. The heart and mediastinum are thus closest to the film and therefore not magnified.
- When an x-ray is taken in an AP position, such as when the patient is unwell in bed, the heart and mediastinum are distant from the cassette and are therefore subject to x-ray magnification. As a result it is very difficult to make an accurate assessment of the cardiomedastinal contour on an AP film.



The cardiomeastinal contour is significantly magnified on this AP film. This needs to be appreciated and not overcalled.



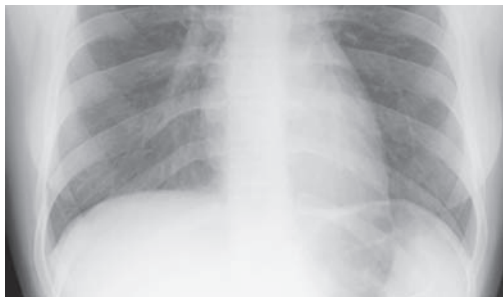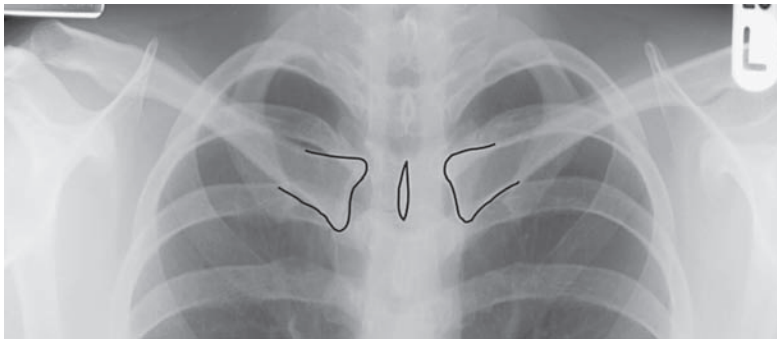
On the PA film, taken only an hour later, the mediastinum appears normal.

## Patient-dependent factors

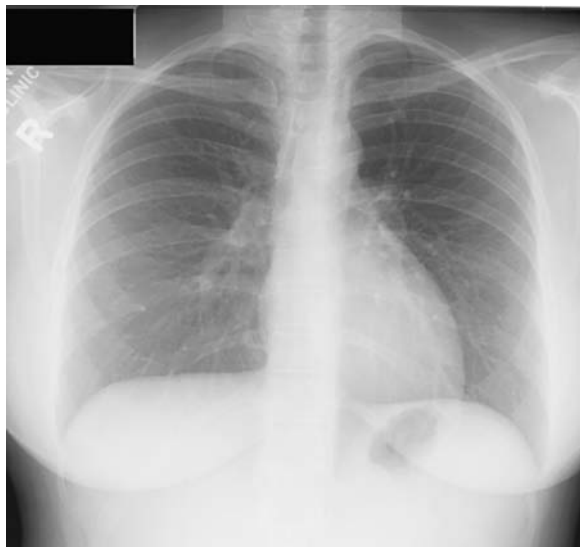### ***Assessment of patient rotation***

- Identifying patient rotation is important. Patient rotation may result in the normal thoracic anatomy becoming distorted; cardiomeastinal structures, lung parenchyma and the bones and soft tissues may all





A well centred x-ray. Medial ends of clavicles are equidistant from the spinous process.



This patient is rotated to the left. Note the spinous process is close to the right clavicle and the left lung is ‘blacker’ than the right, due to the rotation.

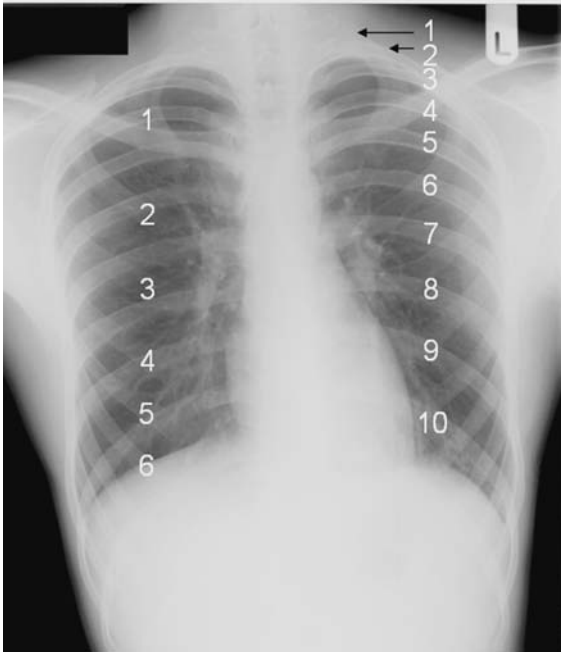appear more, or less, conspicuous. To the uninitiated, failure to appreciate this could easily lead to ‘overcalling’ pathology.

- On a high-quality CXR, the medial ends of both clavicles should be equidistant from the spinous process of the vertebral body projected between the clavicles. If this is not the case then the patient is rotated, either to the left or to the right.
- If there is rotation, the side to which the patient is rotated is assessed by comparing the densities of the two hemi-thoraces. *The increase in blackness of one hemi-thorax is always on the side to which the patient is rotated,* irrespective of whether the CXR has been taken PA or AP.

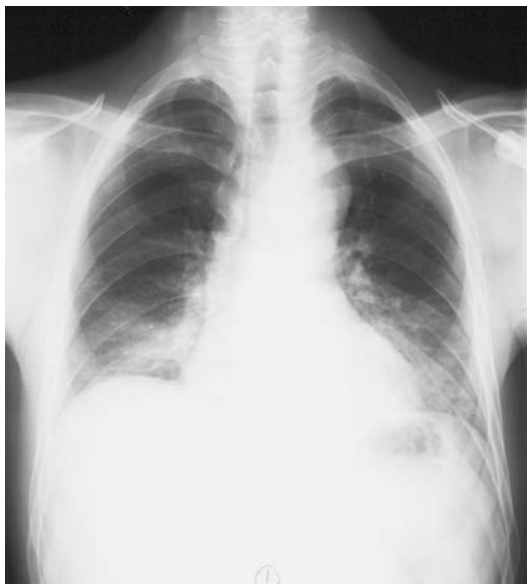### **Assessment of adequacy of inspiratory effort**

Ensuring the patient has made an adequate inspiratory effort is important in the initial assessment of the CXR.

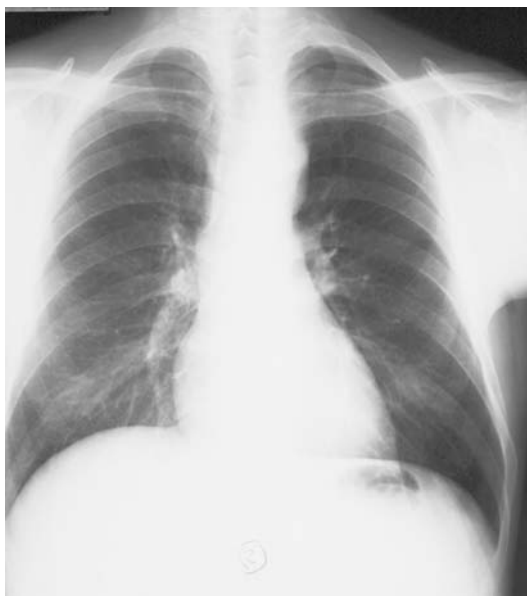- Assessment of inspiratory adequacy is a simple process.
- It is ascertained by counting either the number of visible anterior or posterior ribs.
- If six complete anterior or ten posterior ribs are visible then the patient has taken an adequate inspiratory effort.
- Conversely, fewer than six anterior ribs implies a poor inspiratory effort and more than six anterior ribs implies hyper-expanded lungs.



Six complete anterior ribs (and ten posterior ribs) are clearly visible.



An example of poor inspiratory effort. Only four complete anterior ribs are visible. This results in several spurious findings: cardiomegaly, a mass at the aortic arch and patchy opacification in both lower zones.



Same patient following an adequate inspiratory effort. The CXR now appears normal.

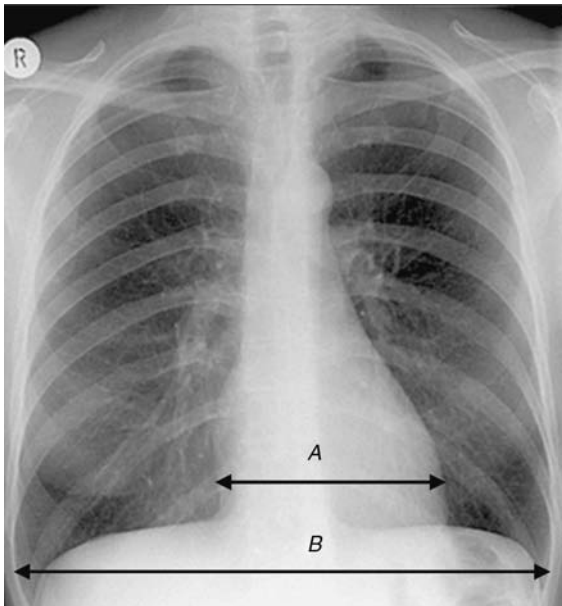
- If a poor inspiratory effort is made or if the CXR is taken in expiration, then several potentially spurious findings can result:
  - apparent cardiomegaly
  - apparent hilar abnormalities
  - apparent mediastinal contour abnormalities
  - the lung parenchyma tends to appear of increased density, i.e. ‘white lung’.
- Needless to say any of these factors can lead to CXR misinterpretation.

## Review of important anatomy

### *Heart and mediastinum*

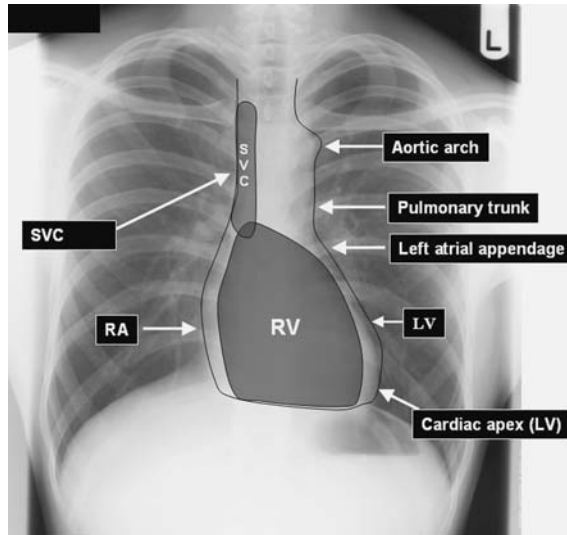
#### *Assessment of heart size*

- The cardiothoracic ratio should be less than 0.5.
- i.e.  $A/B < 0.5$ .
- A cardiothoracic ratio of greater than 0.5 (in a good quality film) suggests cardiomegaly.



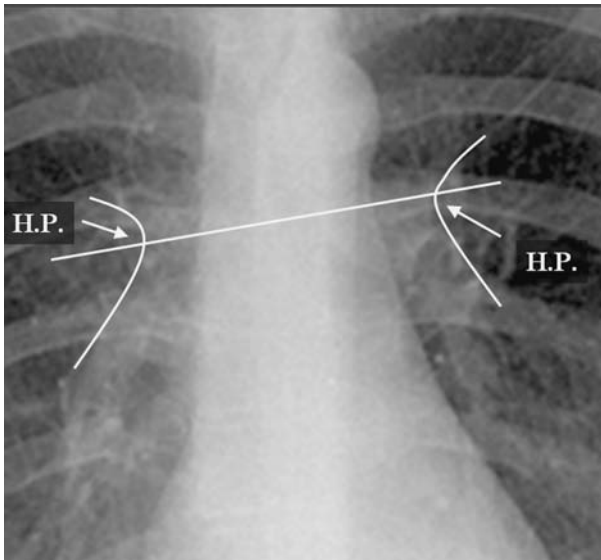
*Assessment of cardiomediastinal contour*

- **Right side:**
  - SVC
  - RA
- **Anterior aspect:**
  - RV
- **Cardiac apex:**
  - LV
- **Left side:**
  - LV
  - Left atrial appendage
  - Pulmonary trunk
  - Aortic arch.



### Assessment of hilar regions

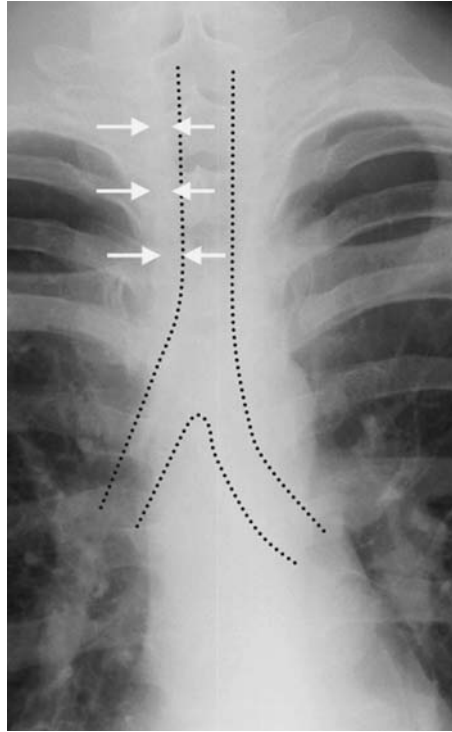
- Both hilar should be concave. This results from the superior pulmonary vein crossing the lower lobe pulmonary artery. The point of intersection is known as the *hilar point (HP)*.
- Both hilar should be of similar density.
- The left hilum is usually superior to the right by up to 1 cm.



### Assessment of the trachea

- The trachea is placed usually just to the right of the midline, but can be pathologically pushed or pulled to either side, providing indirect support for an underlying abnormality.
- The right wall of the trachea should be clearly seen as the so-called right para-tracheal stripe.

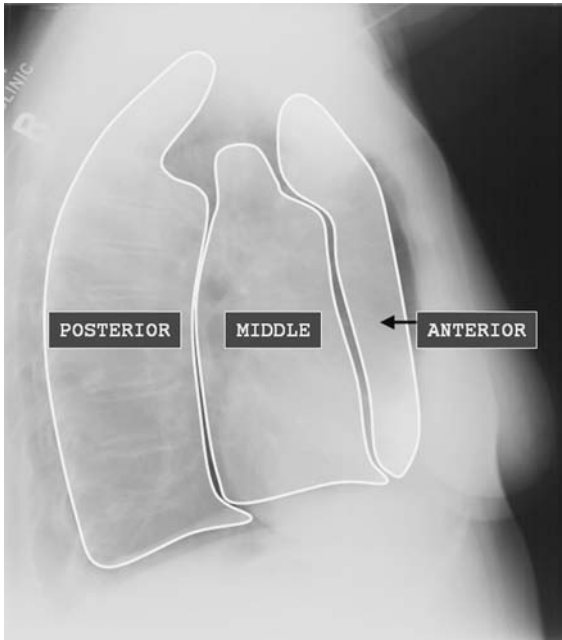
- The para-tracheal stripe is visible by virtue of the silhouette sign: air within the tracheal lumen and adjacent right lung apex outline the soft-tissue-density tracheal wall.
- Loss or thickening of the para-tracheal stripe intimates adjacent pathology.
- The trachea is shown in its normal position, just to the right of centre. The right para-tracheal stripe is clearly seen.



### *Evaluation of mediastinal compartments*

It is useful to consider the contents of the mediastinum as belonging to three compartments:

- *Anterior mediastinum*: anterior to the pericardium and trachea.
- *Middle mediastinum*: between the anterior and posterior mediastinum.
- *Posterior mediastinum*: posterior to the pericardial surface.



## Lungs and pleura

### ***Lobar anatomy***

There are three lobes in the right lung and two in the left. The left lobe also contains the lingula; a functionally separate ‘lobe’, but anatomically part of the upper lobe.

#### ***Right lung***

- Upper lobe
- Middle lobe
- Lower lobe.

#### ***Left lung***

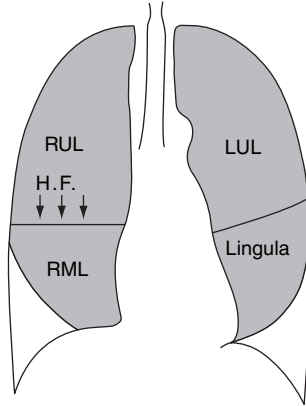
- Upper lobe; this contains the lingula
- Lower lobe.



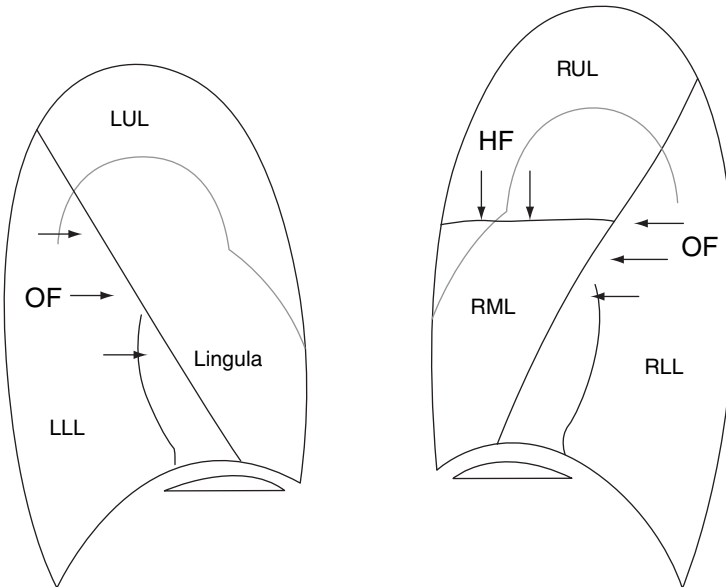
## Pleural anatomy

There are two layers of pleura: the parietal pleura and the visceral pleura.

- The parietal pleura lines the thoracic cage and the visceral pleura surrounds the lung.
- Both of these layers come together to form reflections which separate the individual lobes. These pleural reflections are known as *fissures*.
- On the right there is an oblique and horizontal fissure; the right upper



Lobar and pleural anatomy – frontal view.



Lobar and pleural anatomy – left lateral view.

Lobar and pleural anatomy – right lateral view.

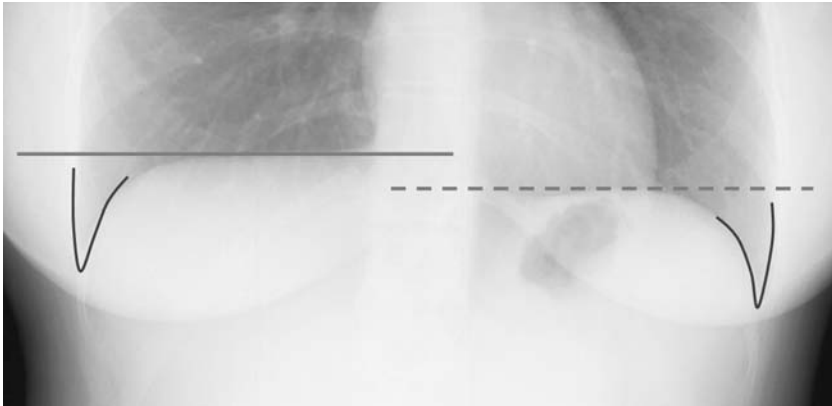
lobe sits above the horizontal fissure (HF), the right lower lobe behind the oblique fissure (OF) and the middle lobe between the two.

- On the left, an oblique fissure separates the upper and lower lobes.

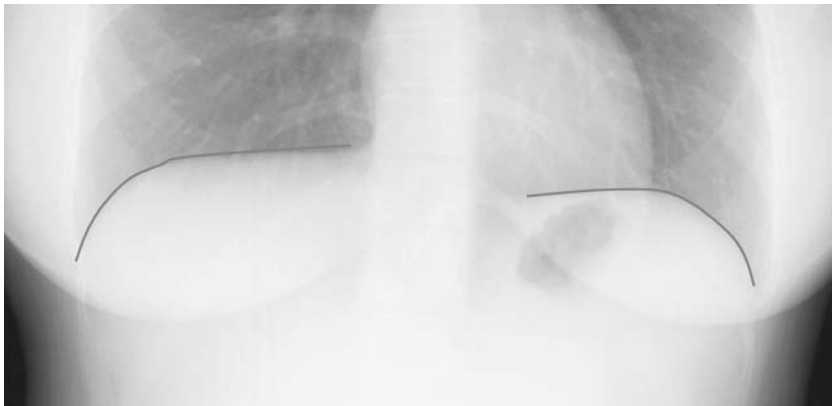
## Diaphragms

### **Assessment of the diaphragms**

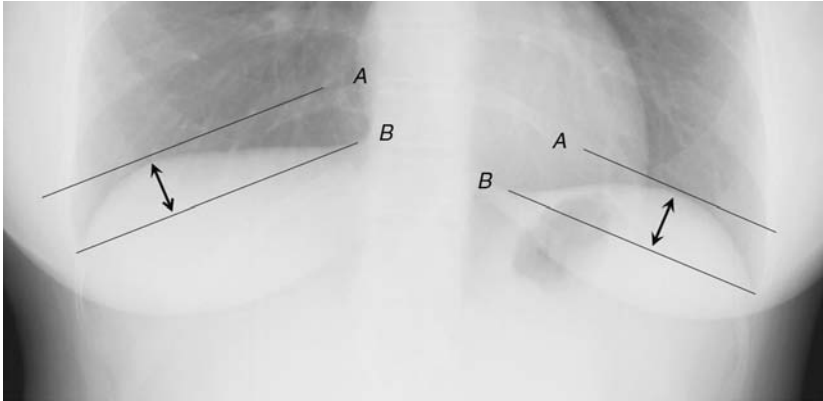
- Carefully examine each diaphragm. The highest point of the right diaphragm is usually 1–1.5 cm higher than that of the left. Each costophrenic angle should be sharply outlined. The outlines of both



The right hemidiaphragm is ‘higher’ than the left. Both costophrenic angles are sharply outlined.



The outlines of both hemidiaphragms should be clearly visible.



Assess for diaphragmatic flattening. The distance between A and B should be at least 1.5 cm.

hemidiaphragms should be sharp and clearly visible along their entire length (except the medial most aspect of the left hemidiaphragm).

- The ‘curvature’ of both hemidiaphragms should be assessed to identify diaphragmatic flattening. The highest point of a hemidiaphragm should be at least 1.5 cm above a line drawn from the cardiophrenic to the costophrenic angle.

## Bones and soft tissues

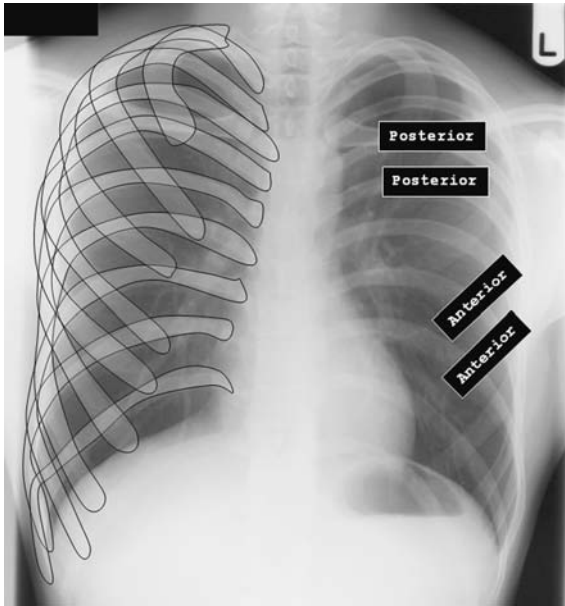
### *Assessment of bones and soft tissues*

This is an area often overlooked. When assessing a CXR, there is a tendency to routinely look at the ‘heart and lungs’, and skirt over the bones and soft tissues.

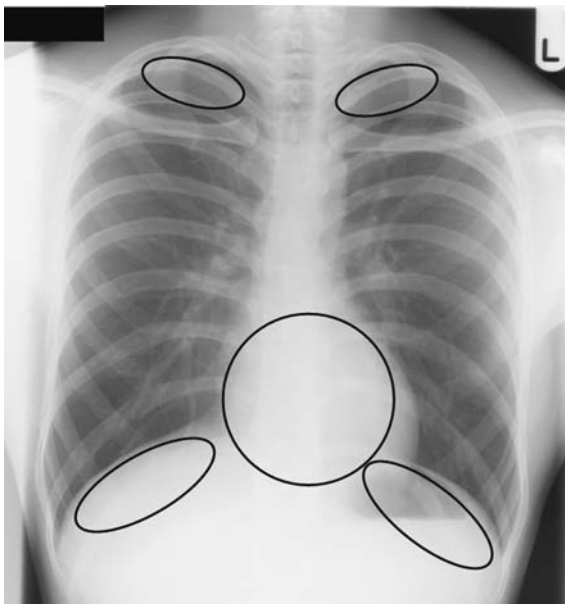
It is important to scrutinise every rib (from the anterior to posterior), the clavicles, vertebrae and the shoulder joints (if they are on the film). Similarly, look carefully at the soft tissues for asymmetry; a typical finding in cases following mastectomy. It can be surprisingly difficult to ‘see’ objects that are missing. If the ‘bones and soft tissues’ are not given their due consideration then vital information may not be appreciated.

After scrutinising the bones and soft tissues, remember to look for pathology in the ‘hidden areas’.

- The lung apices
- Look ‘behind’ the heart
- Under the diaphragms.



Remember to scrutinise every rib, (from the anterior to posterior), the clavicles, vertebrae and the shoulders.



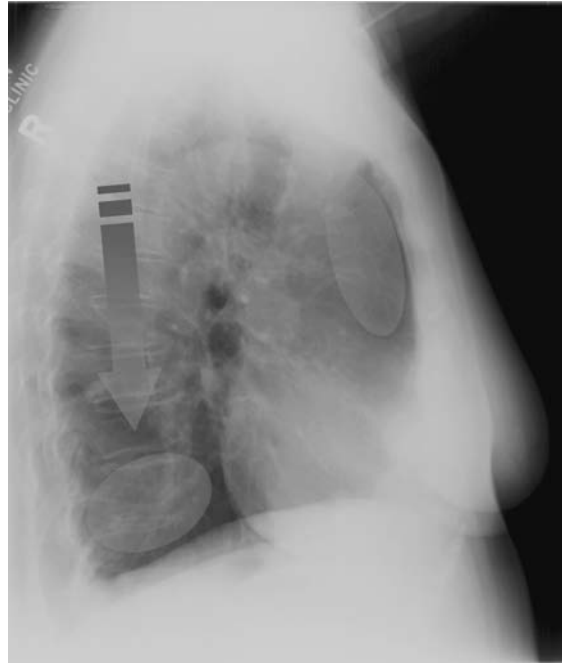
The ‘hidden’ areas.

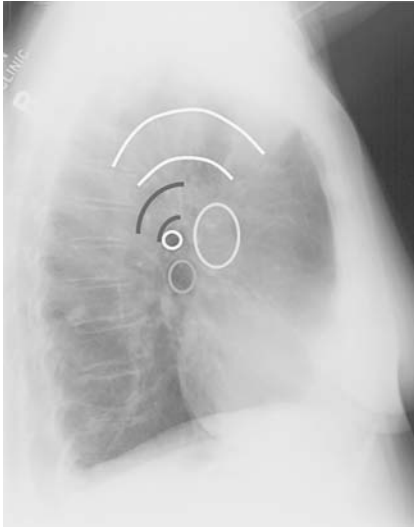
## A brief look at the lateral CXR

### *Important anatomy relating to the lateral CXR*

#### *Key points*






- There should be a decrease in density from superior to inferior in the posterior mediastinum.
- The retrosternal airspace should be of the same density as the retrocardiac airspace.





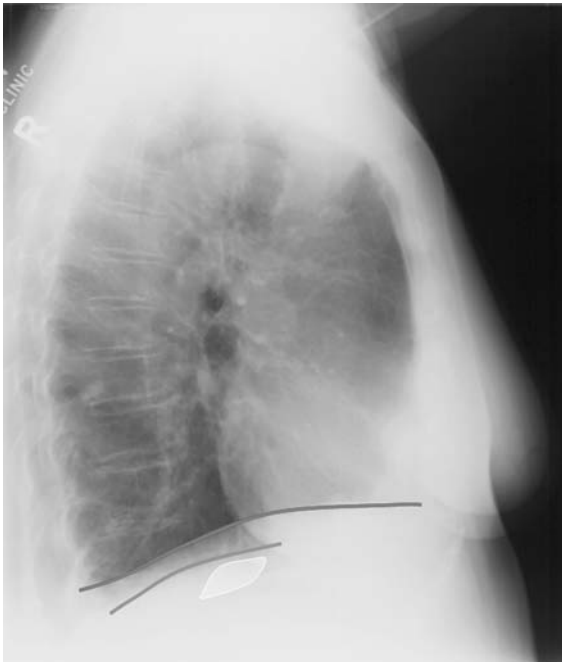
**Key points**

**Central hilar structures**

-  = Pulmonary trunk
-  = Right upper lobe bronchus
-  = Left upper lobe bronchus
-  = Left pulmonary artery
-  = Aortic arch

***Diaphragms***

The right hemidiaphragm is usually ‘higher’ than the left. The outline of the right can be seen extending from the posterior to anterior chest wall. The outline of the left hemidiaphragm stops at the posterior heart border. Air in the gastric fundus is seen below the left hemidiaphragm.



## Understanding the silhouette sign

The silhouette sign, first described by Felson in 1950, is a means of detecting and localising abnormalities within the chest.

In order for any object to appear radiographically distinct on a CXR, it must be of a different radiographic density to that of an adjacent structure. Broadly speaking only four different radiographic densities are detectable on a plain radiograph: air, fat, soft tissue and bone (i.e. calcium). If two soft tissue densities lie adjacent to each other, they will not be visible separately (e.g. the left and right ventricles). If however two such densities are separated by air, the boundaries of both will be seen. The silhouette sign has applications elsewhere in the body too; gas is outlined within bowel lumen separate from soft tissue bowel wall, renal outlines are visible due to the presence of perinephric fat between the kidneys and surrounding soft tissues.

The silhouette sign has two uses:

- It can localise abnormalities on a frontal CXR without the aid of a lateral view. For example, if a mass lies adjacent to, and obliterates the outline of, the aortic arch, then the mass lies posteriorly against the arch (which represents the posteriorly placed arch and descending aorta). If the outline of the arch and of the mass are seen separately, then the mass lies anteriorly.
- The loss of the outline of the hemidiaphragm, heart border or other structures suggests that there is soft tissue shadowing adjacent to these, such as lung consolidation. (*See Section 2 for various examples of lung consolidation*).

# A-Z CHEST RADIOLOGY

PART



• ABSCESS	22
• ACHALASIA	26
• ALVEOLAR MICROLITHIASIS	28
• ANEURYSM OF THE PULMONARY ARTERY	30
• AORTIC ARCH ANEURYSM	32
• AORTIC RUPTURE	36
• ASBESTOS PLAQUES	38
• ASTHMA	42
• BOCHDALEK HERNIA	46
• BRONCHIECTASIS	48
• BRONCHOCELE	52
• CALCIFIED GRANULOMATA	54
• CARCINOMA	56
• CARDIAC ANEURYSM	60
• CHRONIC OBSTRUCTIVE PULMONARY DISEASE	62
• COARCTATION OF THE AORTA	66
• COLLAPSED LUNG	68
• CONSOLIDATED LUNG	76
• DIAPHRAGMATIC HERNIA – ACQUIRED	82
• DIAPHRAGMATIC HERNIA – CONGENITAL	84
• EMBOLIC DISEASE	86
• EMPHYSEMATOUS BULLA	90
• EXTRINSIC ALLERGIC ALVEOLITIS	92



• FLAIL CHEST	96
• FOREGUT DUPLICATION CYST	100
• FOREIGN BODY – INHALED	102
• FOREIGN BODY – SWALLOWED	104
• GOITRE	106
• HAEMOTHORAX	108
• HEART FAILURE	110
• HIATUS HERNIA	114
• IDIOPATHIC PULMONARY FIBROSIS	118
• INCORRECTLY SITED CENTRAL VENOUS LINE	122
• KARTAGENER SYNDROME	124
• LYMPHANGIOLEIOMYOMATOSIS	126
• LYMPHOMA	128
• MACLEOD’S SYNDROME	132
• MASTECTOMY	134
• MESOTHELIOMA	136
• METASTASES	138
• NEUROENTERIC CYST	142
• NEUROFIBROMATOSIS	144
• PANCOAST TUMOUR	148
• PECTUS EXCAVATUM	152
• PERICARDIAL CYST	154
• PLEURAL EFFUSION	156
• PLEURAL MASS	162
• PNEUMOCONIOSIS	164
• PNEUMOPERITONEUM	168
• PNEUMOTHORAX	170
• POLAND’S SYNDROME	174
• POST LOBECTOMY/POST PNEUMONECTOMY	176
• PROGRESSIVE MASSIVE FIBROSIS	180

• PULMONARY ARTERIAL HYPERTENSION	182
• PULMONARY ARTERIOVENOUS MALFORMATION	184
• SARCOIDOSIS	186
• SILICOSIS	190
• SUBPHRENIC ABSCESS	192
• THORACOPLASTY	194
• THYMUS – MALIGNANT THYMOMA	196
• THYMUS – NORMAL	200
• TUBERCULOSIS	202
• VARICELLA PNEUMONIA	206
• WEGENER'S GRANULOMATOSIS	208
• WESTERMARK'S SIGN	210

# Abscess

## Characteristics

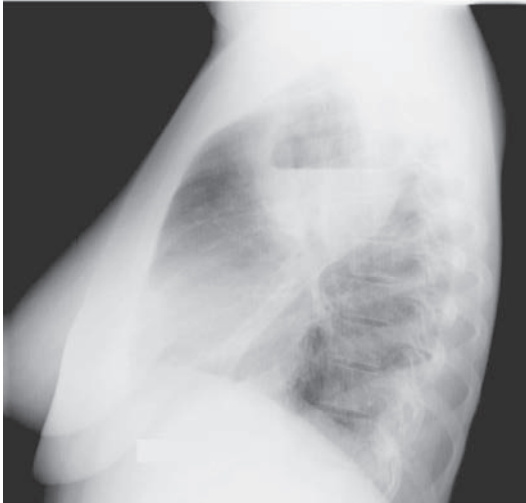
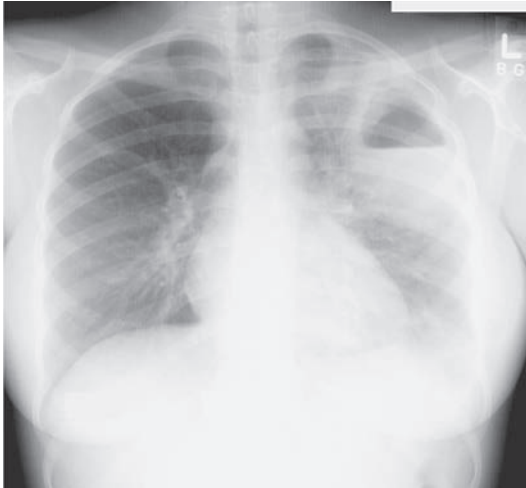
- Cavitating infective consolidation.
- Single or multiple lesions.
- Bacterial (*Staphylococcus aureus*, *Klebsiella*, *Proteus*, *Pseudomonas*, TB and anaerobes) or fungal pathogens are the most common causative organisms.
- ‘Primary’ lung abscess – large solitary abscess without underlying lung disease is usually due to anaerobic bacteria.
- Associated with aspiration and/or impaired local or systemic immune response (elderly, epileptics, diabetics, alcoholics and the immunosuppressed).

## Clinical features

- There is often a predisposing risk factor, e.g. antecedent history of aspiration or symptoms developing in an immunocompromised patient.
- Cough with purulent sputum.
- Swinging pyrexia.
- Consider in chest infections that fail to respond to antibiotics.
- It can run an indolent course with persistent and sometimes mild symptoms. These are associated with weight loss and anorexia mimicking pulmonary neoplastic disease or TB infection.

## Radiological features

- Most commonly occur in the apicoposterior aspect of the upper lobes or the apical segment of the lower lobe.
- **CXR** may be normal in the first 72 h.
- **CXR** – a cavitating essentially spherical area of consolidation usually >2 cm in diameter, but can measure up to 12 cm. There is usually an air-fluid level present.
- Characteristically the dimensions of the abscess are approximately equal when measured in the frontal and lateral projections.
- **CT** is important in characterising the lesion and discriminating from other differential lesions. The abscess wall is thick and irregular and may contain locules of free gas. Abscesses abutting the pleura form acute angles. There is no compression of the surrounding lung. The abscess does not cross fissures. It is important to make sure no direct communication with the bronchial tree is present (bronchopleural fistula).



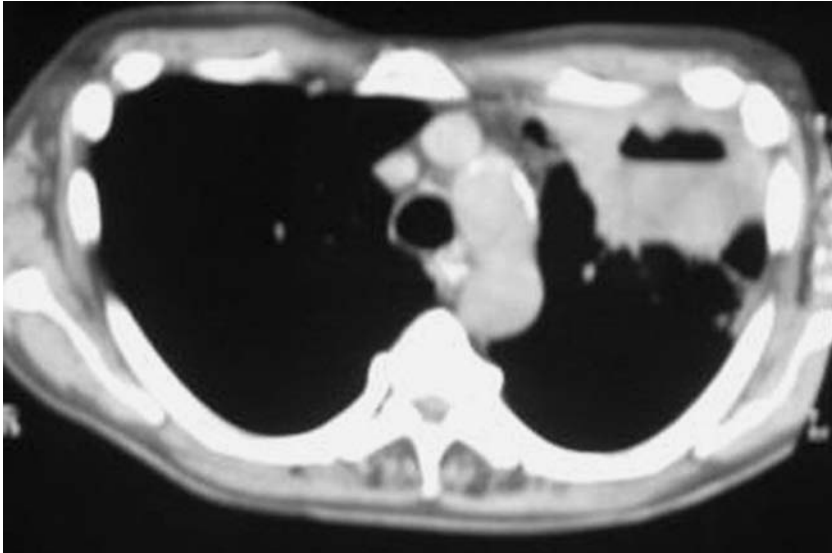
**Lung abscess** – frontal and lateral views. Cavitating lung abscess in the left upper zone.

## Differential diagnosis

- **Bronchopleural fistula** – direct communication with bronchial tree. Enhancing split pleural layers on CT.
- **Empyema** - enhancing split pleural layers, forming obtuse margins with the lung on CT.
- **Primary or secondary lung neoplasms** (e.g. squamous cell carcinomas) – these lesions can run a slow indolent course. Failure to respond to antibiotic therapy should alert the clinician to the diagnosis.
- **TB** (usually reactivation) – again suspected following slow response to treatment. Other findings on the CT may support old tuberculous infection such as lymph node and/or lung calcification. Lymphadenopathy, although uncommon, may be present on the CT scans in patients with lung abscesses. It is therefore not a discriminating tool for differentiating neoplasms or TB infection.

## Management

- Sputum – M, C & S.
- Protracted course of antibiotics is usually a sufficient treatment regime.
- Physiotherapy may be helpful.
- Occasionally percutaneous drainage may be required.
- Lastly, some lesions failing to respond to treatment and demonstrating soft tissue growth or associated with systemic upset (e.g. weight loss) may need biopsy. This is done to exclude underlying neoplasm (e.g. squamous cell carcinoma).



**Lung abscess – CT** (different patient). CT clearly defines the cavitating abscess in the left upper lobe.



# Achalasia

## Characteristics

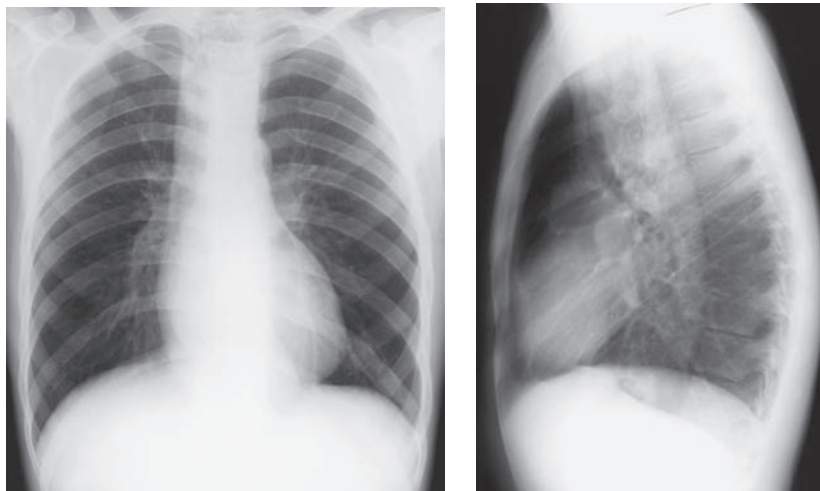
- Achalasia or megaesophagus is characterised by failure of organised peristalsis and relaxation of the lower oesophageal sphincter.
- Primary or idiopathic achalasia is due to degeneration of Auerbach's myenteric plexus.
- Rarely associated with infections, e.g. Chagas' disease (*Trypanosoma cruzi*) present in South American countries.
- Secondary or pseudoachalasia occurs due to malignant infiltration destroying the myenteric plexus from a fundal carcinoma or lymphoma.
- Oesophageal carcinoma occurs in 2–7% of patients with long-standing achalasia.

## Clinical features

- Primarily a disease of early onset – aged 20–40 years.
- Long slow history of dysphagia, particularly to liquids.
- The dysphagia is posturally related. Swallowing improves in the upright position compared to lying prone. The increased hydrostatic forces allow transient opening of the lower oesophageal sphincter.
- Weight loss occurs in up to 90%.
- There is an increased risk of aspiration. Patients can present with chest infections or occult lung abscesses.
- Malignant transformation rarely occurs in long-standing cases and should be suspected with changes in symptoms, e.g. when painful dysphagia, anaemia or continued weight loss develop.

## Radiological features

- **CXR** – an air–fluid level within the oesophagus may be present projected in the midline, usually in a retrosternal location, but can occur in the neck. Right convex opacity projected behind the right heart border, occasionally a left convex opacity can be demonstrated. Mottled food residue may be projected in the midline behind the sternum. Accompanying aspiration with patchy consolidation or abscess formation is demonstrated in the apical segment of the lower lobes and/or the apicoposterior segments of the upper lobe.
- **Barium swallow** – a dilated oesophagus beginning in the upper one-third. Absent primary peristalsis. Erratic tertiary contractions. 'Bird beak' smooth tapering at the gastro-oesophageal junction (GOJ) with delayed sudden opening at the GOJ. Numerous tertiary contractions can be present in a non-dilated early oesophageal achalasia (vigorous achalasia).



**Achalasia.** An additional soft tissue density line is seen parallel to the right mediastinal contour. The gastric fundus bubble is absent. On the lateral view, the entire oesophagus is dilated and is of increased density due to contained debris.

## Differential diagnosis

- The key differential lies with **malignant pseudoachalasia**. This condition occurs in an older age group (>50) with more rapid onset of symptoms (<6 months). Clinical suspicion should merit an OGD ± a CT scan to look closely for neoplastic change, particularly submucosal or extramural disease.
- **Diffuse oesophageal spasm** can produce similar clinical symptoms. Barium swallow and oesophageal manometry help discriminate this condition from achalasia.

## Management

- Diagnosis includes a barium swallow and pressure measurements from oesophageal manometry.
- Oesophageal dilatation is the standard form of treatment and repeated therapies may be necessary.
- Botulinum toxin injection can be effective, but has a short-lived action (<6 months).
- Surveillance for oesophageal carcinoma should be considered.
- Surgical intervention: laparoscopic Heller's cardiomyotomy.



# Alveolar microlithiasis

## Characteristics

- Very rare disease of unknown aetiology characterised by multiple tiny calculi deposited throughout the alveoli.
- 50% familial tendency.
- Equal sex incidence (M = F).
- Often asymptomatic.
- Peak incidence between ages 30 and 50 years, but probably starts earlier in life.

## Clinical features

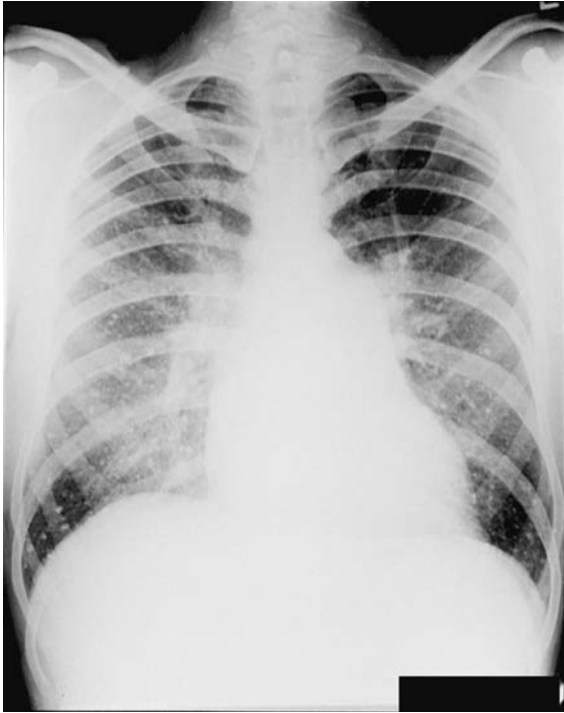- Majority have mild symptoms or are asymptomatic (70%).
- Disease progression is variable.
- Exertional dyspnoea is the commonest symptom and the majority of patients remain clinically stable throughout life following the onset of symptoms.
- Cyanosis and clubbing can occur. A minority develop pulmonary fibrosis and subsequent cor pulmonale.
- Normal serum calcium and phosphorus.

## Radiological features

- **CXR** – multiple dense very fine sand-like micronodulations (<1 mm). The changes are diffuse and present throughout both lungs. Fibrosis can occur with further changes, including bullae most marked in the lung apices. Chronic cases may be associated with enlargement of the pulmonary arteries in keeping with secondary pulmonary hypertension.
- **Bone scan** – avid uptake of tracer throughout the lungs.

## Differential diagnosis

- The main differential diagnosis lies between multiple healed calcified granulomata, particularly following a viral infection and inorganic pneumoconiosis, e.g. heavy metal inhalation. In practice the size of the nodules in these lesions coupled with the antecedent history should alert the clinician to the correct diagnosis.



**Alveolar microlithiasis.** Multiple tiny nodules of high density scattered throughout both lungs.

## Management

- No specific therapeutic options. Follow-up in symptomatic patients with assessment of pulmonary function in those who develop fibrosis and pulmonary insufficiency.
- No advantage to family screening in identified cases.

# Aneurysm of the pulmonary artery

## Characteristics

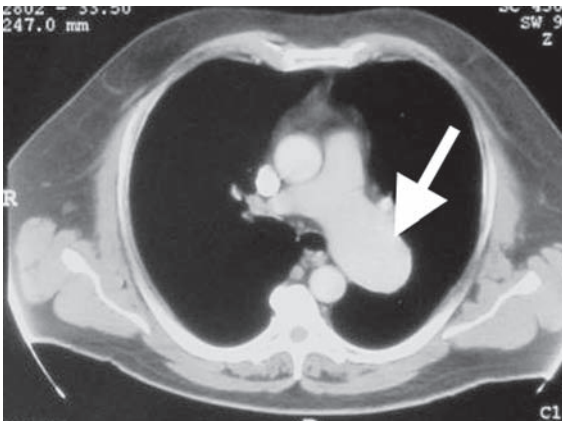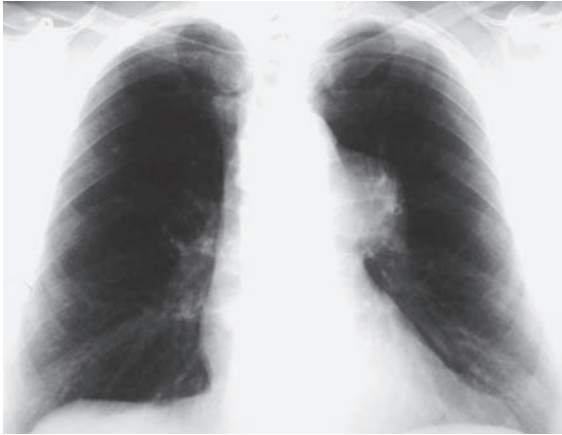- Permanent dilatation of the main and/or segmental pulmonary arterial branches which can be congenital or acquired.
- **Congenital** – rare condition seen in adolescent females with dilatation of the main pulmonary artery. Patients are usually asymptomatic with only a soft ejection systolic murmur detectable. No significant complications. The diagnosis is made after excluding other acquired conditions.
- **Acquired**
  - Infections (e.g. TB, known as Rasmussen aneurysm, where there is mycotic inflammatory necrosis causing dilatation of the arterial wall).
  - Collagen vascular disorders (e.g. Marfan's syndrome).
  - Inflammatory (e.g. Takayasu's arteritis).
  - Behçet's disease. Segmental artery dilatation is a feature of Hughes–Stovin syndrome.
  - Post trauma – blunt (RTA), or direct (following arterial instrumentation).
  - Post stenotic dilatation in pulmonary valvular stenosis.
  - Thromboembolic disease.
  - Associated with primary bronchial neoplasm.

## Clinical features

- Clinical presentation depends on the underlying cause and location of the aneurysm.
- Congenital lesions are uncommon and asymptomatic.
- Acquired lesion – most commonly present with haemoptysis. Rupture may complicate the clinical picture and is frequently fatal.
- In many cases diagnosis is incidental following investigations for the underlying primary disease.

## Radiological features

- **CXR** – isolated main pulmonary artery dilatation in the aortopulmonary window with normal lungs is a rare radiological finding. More commonly the aneurysm lies within an ill-defined area of consolidation and is difficult to fully appreciate.
- **Contrast-enhanced CT** scanning allows clearer appreciation of the size, location and extent of the arterial aneurysm(s).
- **CT** also allows for further assessment of the underlying cause. An increasing focal lung mass raises the possibility of aneurysm. Lack of an arterial wall and a history of trauma support the diagnosis of a false aneurysm of the pulmonary artery.



**Pulmonary artery aneurysm.** Left hilar mass which is of similar density to the right hilum. Note that vessels can be seen through the mass. CT confirms the diagnosis (arrow).

## Differential diagnosis

- The main differential lies within the varying underlying causes listed above.

## Management

- Management is dependent on identifying the abnormalities, correlating with the clinical history, and excluding the various different conditions.
- Sputum culture, echocardiography, cardiac catheterisation and arterial wall biopsy may all play a role in the diagnostic pathway.
- Treatment options are targeted first at the correct management of the cause.
- Surgical repair of the aneurysm and the use of endovascular stent grafts are rarely used strategies, but potentially offer definitive treatment.

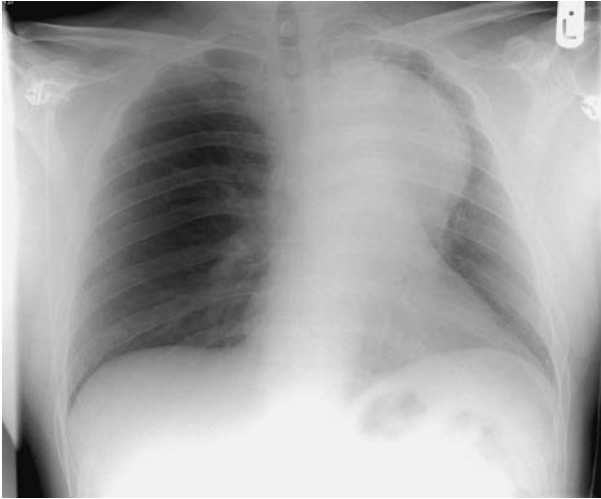
# Aortic arch aneurysm

## Characteristics

- Permanent localised dilatation of the thoracic aorta. The average diameter of the normal thoracic aorta is  $<4.5$  cm. This is the commonest mediastinal vascular abnormality. Most are fusiform dilatations (some are saccular), associated with degenerative atherosclerosis with a mean age at diagnosis of 65.
- Dissecting aortic aneurysms or intramural haematomas are a specific form of thoracic aneurysm. Again, associated with hypertension and degenerative atherosclerosis, a split in the aortic wall allows blood to track between the intimal and adventitial layers of the aorta. They can occur following trauma. This can produce widening of the aorta and a very high risk of rupture. Slow flow in the false lumen can result in ischaemia and infarction to end organs supplied by the thoracic and ultimately the abdominal aorta. It can be graded by the Stanford classification into **type A** (ascending aorta and arch – 2/3) and **type B** descending aorta distal to major vessels (1/3).
- Other rarer causes include congenital causes, infection (mycotic aneurysms, e.g. bacteria or syphilis), connective tissue disorders (e.g. cystic medial necrosis in Marfan's syndrome), inflammatory diseases (e.g. Takayasu's) and dilatation post aortic valvular stenosis. These occur in a younger age group.
- The size of the aneurysm increases with age.
- The risk of rupture increases with aneurysm size.

## Clinical features

- This is commonly found incidentally on routine CXRs in asymptomatic patients.
- The patients may present with substernal, back and/or shoulder pains which can often be severe.
- Rarely patients may present with stridor, hoarse voice or dysphagia from the aneurysm compressing local mediastinal structures.
- Aortic dissection is associated with aortic regurgitation and cardiac failure, heart murmurs and differential blood pressure measurements in the arms. In addition dissecting aneurysms can produce ischaemia and infarction to end organs (e.g. stroke, renal failure, ischaemic bowel).
- Rupture of the aneurysm is almost always fatal with patients presenting with collapse and hypotension from hypovolaemic shock.



**Aortic arch aneurysm.**

## Radiological features

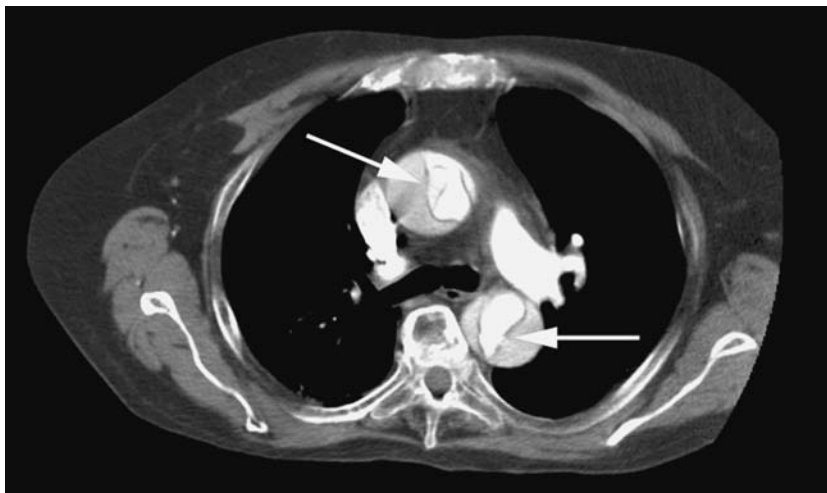
- **CXR** – a soft tissue mediastinal mass in the region of the aorta, measuring 4–10 cm. Wide tortuous aorta >4.5 cm. Curvilinear calcifications outlining the aortic wall. Left pleural effusions, left apical cap or left lower lobe collapse.
- **CT** – above findings ± extensive mural thrombus present within the aortic wall. In early aortic dissections the aortic wall may be thickened and of slightly increased attenuation. A dissection flap may be demonstrated with a double channel to the aorta. High attenuation lies within the false lumen, which is usually present in the superior aspect of the aortic arch. Contrast-enhanced CT demonstrates the differential flow within the two or more lumens. There may also be evidence of a haemopericardium with retrograde dissection back to the heart.
- **MRI** – contrast-enhanced MRA is a very good alternative to characterising the site and extent of aortic aneurysm, particularly dissecting aneurysms.
- **Transoesophageal echocardiography** – very sensitive in characterising aortic aneurysms and in particular the cardiac involvement in dissecting aneurysms.
- **Angiography** – the true and false lumens demonstrated may be of normal, reduced or enlarged calibre.
- **Rupture** may be associated with high attenuation fluid in the mediastinum and pleural space.

## Differential diagnosis

- The differential diagnosis, other than the different types of aortic aneurysm already described, is **chronic aortic pseudoaneurysm**. This occurs in 2.5% of patients who survive the initial trauma of acute aortic transection. There is focal aortic dilatation with disruption of the aortic wall. Blood is contained by adventia and connective tissue only. The pseudoaneurysm increases in size with time and is at risk of rupture.

## Management

- Aneurysm repair is considered in all patients when the aneurysmal size increases beyond 6 cm.
- Both surgical and endovascular stent grafting are successful treatment options.
- Surgical mortality is as high as 10%.
- Control of risk factors such as hypertension.
- Surveillance of aneurysms >5 cm.
- Dissecting aneurysms are a surgical emergency. ABC first line, then assessment and grading of the dissection. In particular 3D CT reformats are very helpful for completely assessing the extent and branch artery involvement. Early surgery considered in type A dissections.
- Non-surgical survival rates are lower than 10%.



**Type A aortic dissection.** Dissection 'flaps' can be seen in both the ascending and descending aorta (arrows).



# Aortic rupture

## Characteristics

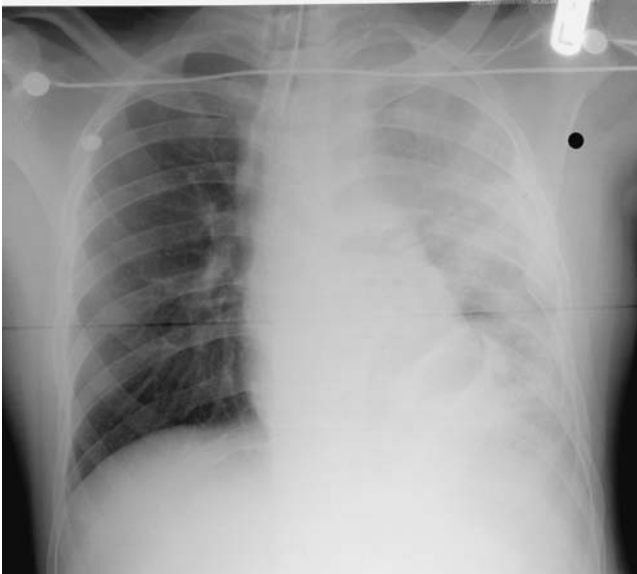- Blood leakage through the aortic wall.
- **Spontaneous rupture.** Hypertension and atherosclerosis predispose to rupture. There may be an underlying aneurysm present, but rupture can occur with no preformed aneurysm.
- **Traumatic rupture** or transection following blunt trauma. Follows deceleration injury (RTA). Over 80% die before arrival at hospital. The weakest point, where rupture is likely to occur, is at the aortic isthmus, which is just distal to the origin of the left subclavian artery.
- The rupture may be revealed or concealed.

## Clinical features

- There is often an antecedent history of a known aneurysm or appropriate trauma (e.g. RTA).
- Patients may be asymptomatic particularly if the rupture is small and intramural.
- Most cases present with severe substernal pain radiating through to the back. Patients may be breathless, hypotensive, tachycardic or moribund.

## Radiological features

- **CXR** – look for widening of the mediastinum on CXRs. It is very rare to see aortic rupture in a patient with a normal CXR. Other features on the CXR include loss of the aortic contour, focal dilatation of the aorta and a left apical cap (blood tracking up the mediastinal pleural space). Signs of chest trauma – rib fractures (1st and 2nd), haemopneumothorax and downward displacement of a bronchus.
- **Unenhanced CT** – may show crescentic high attenuation within a thickened aortic wall only (intramural haematoma, at risk of imminent dissection or rupture). Rupture is associated with extensive mediastinal blood. A pseudoaneurysm may be present. There may be injuries to major branching vessels from the aorta.
- **Angiography** or **transoesophageal echocardiography** – may be helpful to confirm small intimal tears of the aortic wall. However, contrast-enhanced **MRA** is a sensitive alternative investigation to standard invasive angiography.



**Aortic rupture.** The outline of the aortic arch is ill-defined and there is tracheal deviation to the right. Generalised increase in density of the left hemithorax – secondary to haemorrhage. Note additional injuries: rib fractures and diaphragmatic rupture.

### Differential diagnosis

- The differential diagnosis for a widened mediastinum on a frontal CXR includes lymphadenopathy, tumours and simple aneurysms. Further assessment, usually with urgent CT imaging, may be required in the first instance if there is any suspicion of thoracic aortic injury.

### Management

- ABC – this is a surgical emergency.
- Appropriate imaging and full characterisation of the aortic rupture and, in cases of trauma, other accompanying injuries.
- Early surgical repair. In cases that are considered a high operative risk, patients are considered for aortic stent grafting.
- In patients who survive there is a long-term small risk of chronic pseudoaneurysm formation.

# Asbestos plaques

## Characteristics

- Asbestos-related pleural plaques represent focal areas of fibrotic response in the visceral pleura to previous exposure to inhaled asbestos fibres at least 8–10 years before. Classically, they calcify (approximately 50%). Both the presence of plaques and their calcification increase with time. They spare the costophrenic angles and lung apices. In their own right they have no malignant potential; however, in some patients, asbestos exposure can lead to pulmonary fibrosis, lung cancer and mesothelioma.

## Clinical features

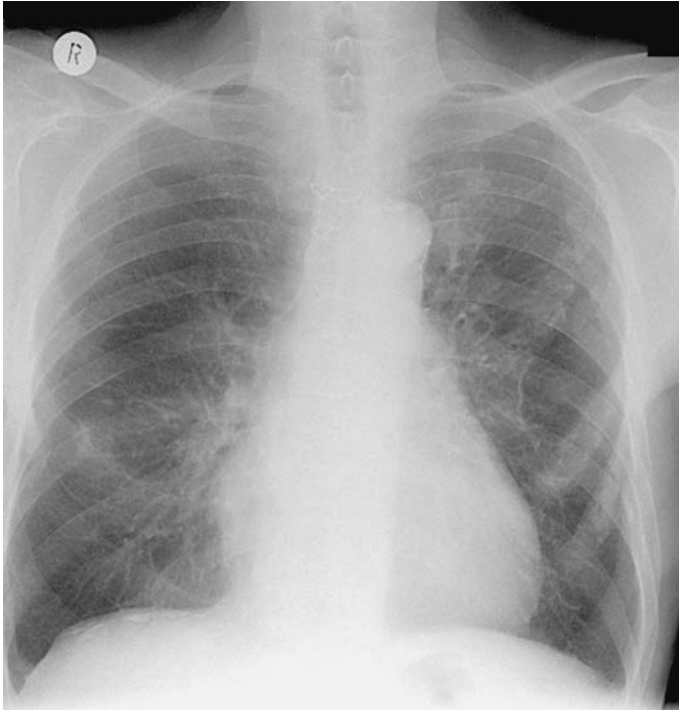
- Asbestos plaques are asymptomatic. Any chest symptoms should alert the clinician to the potential complications of asbestos exposure.

## Radiological features

- **CXR** – focal areas of pleural thickening (<1 cm). They are usually bilateral and may be multiple. Plaques are more visible when they calcify and calcified plaques have a thicker peripheral edge than central portion. When they are seen en-face they have an irregular ‘holly leaf’ appearance. Non-calcified plaques seen en-face can give a patchy density to the lungs. There should be no lymphadenopathy.
- They are associated with rounded atelectasis or pseudotumours. On the **CXR** these look like peripherally based round nodules mimicking lung neoplasms. On **CT** imaging they demonstrate a rounded area of lung abutting an area of pleural thickening, with a swirl of vessels (tail) leading to the peripheral-based lesion. They are completely benign and should be recognised to avoid further invasive investigations.
- Occasionally the pleural thickening can be diffuse, restricting lung function and mimicking mesothelioma.

## Differential diagnosis

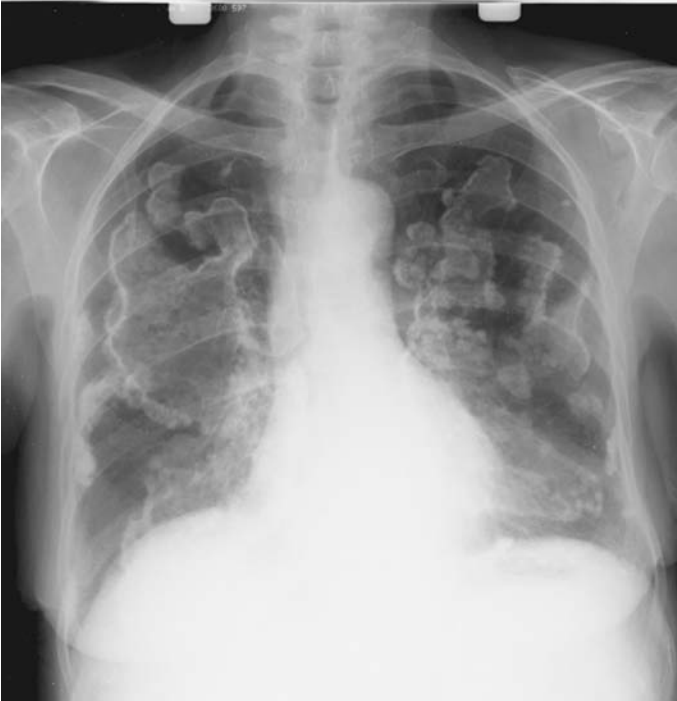- There are few conditions which have a similar appearance.
- Previous history of TB or haemorrhagic pleural effusions can give a similar picture (more often unilateral).
- Exposure to amiodarone and a very rare condition of idiopathic pleural fibrosis can also produce these findings.



**Asbestos plaques.** Right diaphragmatic pleural calcification seen. Additional ill-defined pleural calcification also present in the left mid zone.

## Management

- No active management.
- Need to exclude complications of asbestos exposure with a supportive clinical history and possibly further imaging (CT scan).
- Consider follow-up, particularly if chest symptoms persist and the patient is a smoker. Pulmonary asbestosis (fibrosis secondary to asbestos exposure) increases the risk of lung cancer 40-fold if the patient is also a smoker.
- Consideration for industrial financial compensation.



**Asbestos plaques.** Extensive calcified pleural plaques are seen in both lungs.

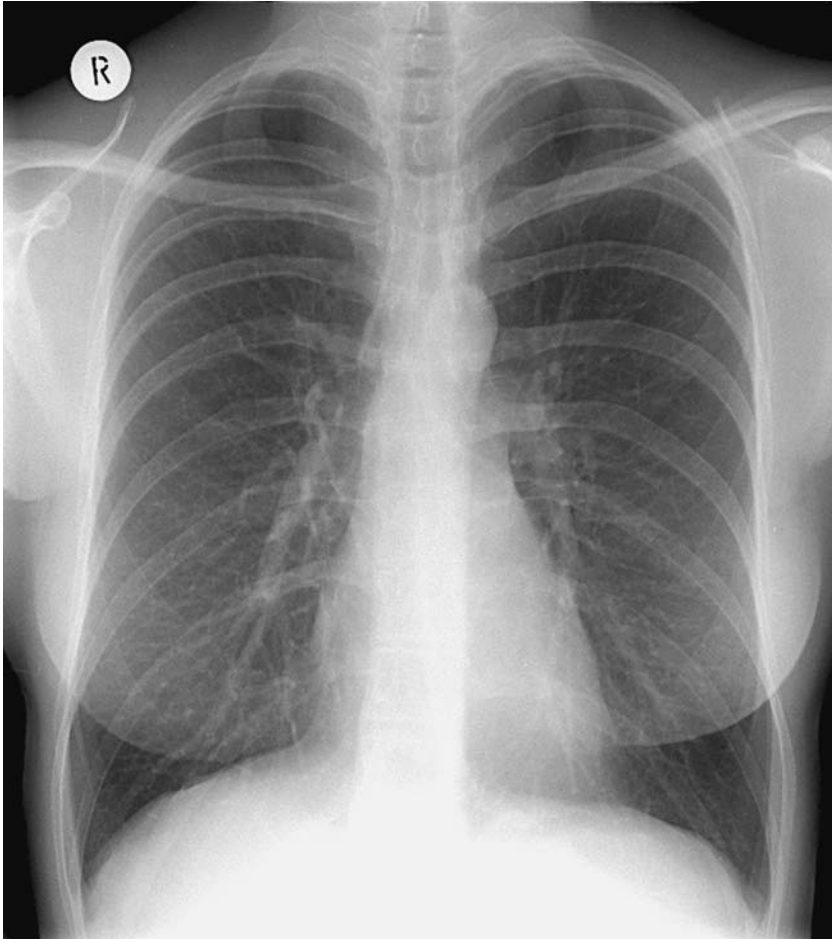
# Asthma

## Characteristics

- Asthma is characterised by a triad of airway inflammation, reversible airway obstruction, and hyper-reactivity of the airways to a variety of stimuli.
- Functionally the disease is characterised by wide variations, over short periods of time, in resistance to air flow in intrapulmonary airways. This increase in airway resistance is reversible, particularly with bronchodilators.
- Intrinsic asthma – no definite precipitating cause. Young and middle-age onset.
- Extrinsic or atopic asthma – immediate type 1 hypersensitivity reaction to specific antigen or allergen (e.g. pollens or chemicals). Removal of the stimulus produces a clinical improvement.

## Clinical features

- Attacks of breathlessness, chest tightness and wheeze. Often severe and requiring ventilatory support.
- Occasionally, mild symptoms such as a persistent cough predominate.
- The patient is hypoxic with low  $pO_2$  and usually a low  $pCO_2$ . A high  $pCO_2$  is a sinister sign heralding severe fatigue and respiratory failure.
- There is reduced forced vital capacity (FVC) and forced expiratory volume in 1 s ( $FEV_1$ ). These improve following the administration of bronchodilators.
- The residual lung volume and total lung capacity are increased due to air trapping.



**Asthma.** The lungs are hyperinflated; there is bilateral diaphragmatic flattening; 7 anterior and 11 posterior ribs are visible; lungs are otherwise clear.



## Radiological features

- Early in the disease the radiology may be entirely normal. Chronic asthma is associated with a number of distinct radiographic changes.
- **CXR** – lungs are hyperinflated with flattened hemidiaphragms of limited excursion. There is bronchial wall thickening ( $>1$  mm). This is a more marked finding in children and in adults with infection. There is also hilar enlargement due to a combination of lymphadenopathy and pulmonary hypertension.
- **CT** may confirm thickened bronchi, but also areas of mosaic perfusion on ‘lung windows’. These represent variable alternate areas of air trapping set against normally perfused and aerated lung.
- Always look for complications of asthma:
  - Pneumothorax or rarely pneumomediastinum.
  - Consolidation secondary to pulmonary infection.
  - Mucus plugging and subsequent lobar or segmental lung collapse.
  - In 2% allergic bronchopulmonary aspergillosis (ABPA) – dilated central bronchiectasis, with mucus plugging, associated with eosinophilia.

## Differential diagnosis

- The radiological features are similar to those of cystic fibrosis.
- However the clinical mimics of asthma are important to differentiate. They can often be diagnosed with imaging and should be considered, particularly in atypical cases.
- Inhaled foreign body (particularly in children). Look for compatible history and asymmetric air trapping. CT imaging or bronchoscopy should be considered.
- Left heart failure. Look carefully for early interstitial pulmonary oedema.
- Tracheobronchial stenosis – tracheal narrowing will be visible on the CXR.
- Hypersensitivity pneumonitis – look for ground glass change and centrilobular nodules on CT.
- Post infectious bronchiolitis – air trapping on HRCT.

## Management

- ABC.
- Bronchodilators – inhaled and nebulised (e.g. salbutamol).
- Inhaled steroids  $\pm$  oral/IV steroids.
- Antibiotics.
- Physiotherapy.
- Early consideration for ventilatory support.
- Maintenance inhalers and good technique to prevent attacks.

# Bochdalek hernia

## Characteristics

- Congenital anomaly with defective fusion of the posterolateral pleuro-peritoneal layers.
- 85–90% on the left, 10–15% on the right. Usually unilateral lying posteriorly within the chest.
- Hernia may contain fat or intra-abdominal organs.
- In neonates the hernia may be large and present in utero. This is associated with high mortality secondary to pulmonary hypoplasia (60%).
- Small hernias are often asymptomatic containing a small amount of fat only. They have a reported incidence up to 6% in adults.

## Clinical features

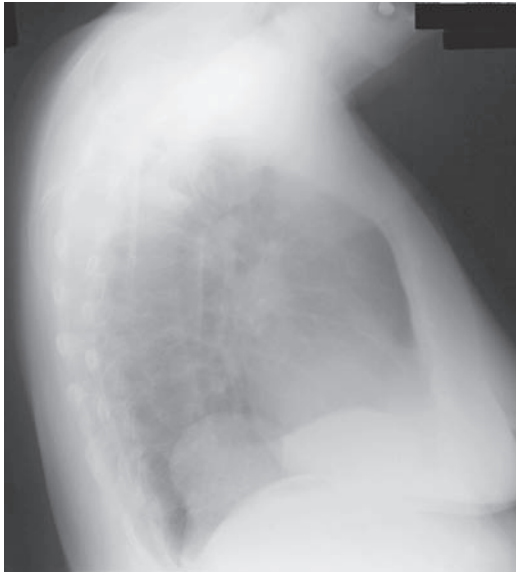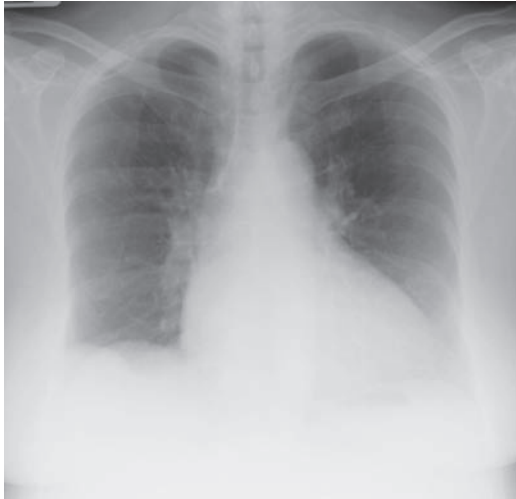- Large hernias are diagnosed antenatally with US.
- Neonates may present with respiratory distress early in life. Early corrective surgery is recommended.
- Smaller hernias are usually asymptomatic with incidental diagnosis made on a routine CXR.
- Occasionally solid organs can be trapped within the chest compromising the vascular supply. Patients report localised pains and associated organ-related symptoms, e.g. change in bowel habit.

## Radiological features

- **CXR** – a well-defined, dome-shaped soft tissue opacity is seen midway between the spine and the lateral chest wall. This may ‘come and go’. There may be loops of bowel or gas-filled stomach within the area. The ipsilateral lung may be smaller with crowding of the bronchovascular markings and occasionally mediastinal shift. An NG tube may lie curled in the chest.
- **CT** – small hernia are difficult to demonstrate even on CT. Careful inspection for a fatty or soft tissue mass breaching the normal smooth contour of the posterior diaphragm.

## Differential diagnosis

- In neonates, both congenital cystic adenomatoid malformation (CCAM) and pulmonary sequestration may have similar features. Cross-sectional imaging with CT ± MRI utilising 2D reformats is often very helpful.
- In adults, the plain film findings mimic pulmonary neoplasms, bronchogenic cysts and infections (± cavitation).



**Bochdalek hernia.** An apparent mass is present at the right lung base on the frontal radiograph. This is seen herniating through the posterior aspect of the right hemi-diaphragm on the lateral view; 10–15% of Bochdalek hernias occur on the right.

### Management

- Large hernias in neonates require early surgical repair. They may also require respiratory support.
- In adults no active management is required in asymptomatic individuals.

# Bronchiectasis

## Characteristics

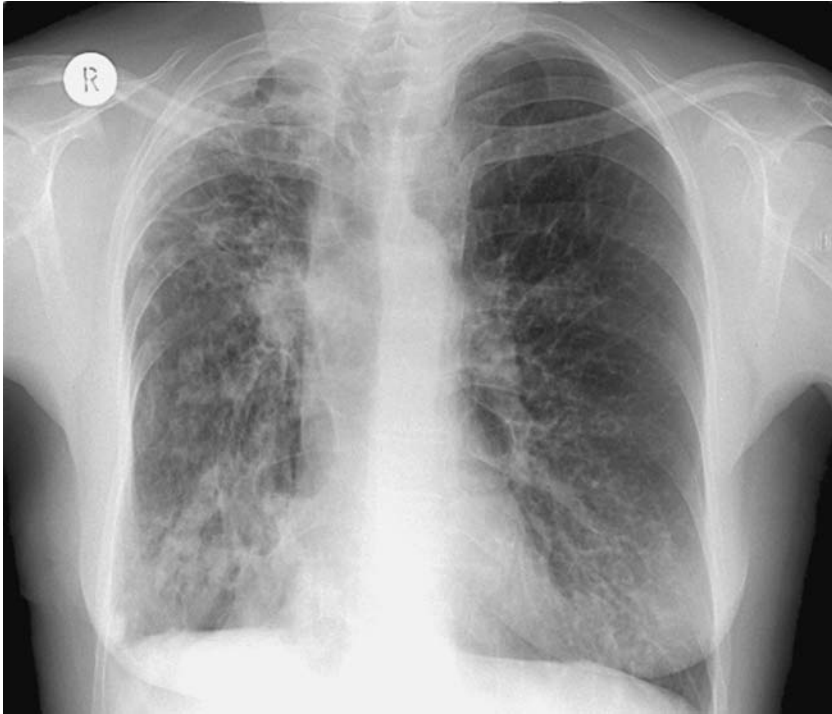
- Localised irreversible dilatation of bronchi often with thickening of the bronchial wall.
- **Congenital** – structural (bronchial atresia); abnormal mucociliary transport (Kartagener’s); abnormal secretions (cystic fibrosis) or secondary to impaired immune system.
- **Acquired**
  - Post childhood infections.
  - Distal to bronchial obstruction (mucus plug, foreign body, neoplasm).
  - ‘Traction bronchiectasis’ secondary to pulmonary fibrosis.
- Types of bronchiectasis
  - Cylindrical or tubular (least severe type).
  - Varicose.
  - Saccular or cystic (most severe type).

## Clinical features

- Most common presentation is in children.
- Increasing breathlessness.
- Chronic cough with excess sputum secretion.
- Haemoptysis.
- Recurrent chest infections with acute clinical exacerbations.

## Radiological features

- Posterobasal segments of lower lobes most commonly affected.
- Bilateral in 50%.
- **CXR** – dilated, thick-walled bronchi giving cystic and tram-lining appearance particularly in the lower lobes. There may be volume loss and overt ‘honeycombing’.
- There may be associated areas of infective consolidation and pleuro-parenchymal distortion.
- **HRCT** – lack of bronchial wall tapering is the most consistent feature. ‘Signet ring’ sign demonstrating a dilated bronchus adjacent to a smaller normal-calibre artery. The dilated bronchus extends out towards the pleura (<1 cm). Mucus plugging present.



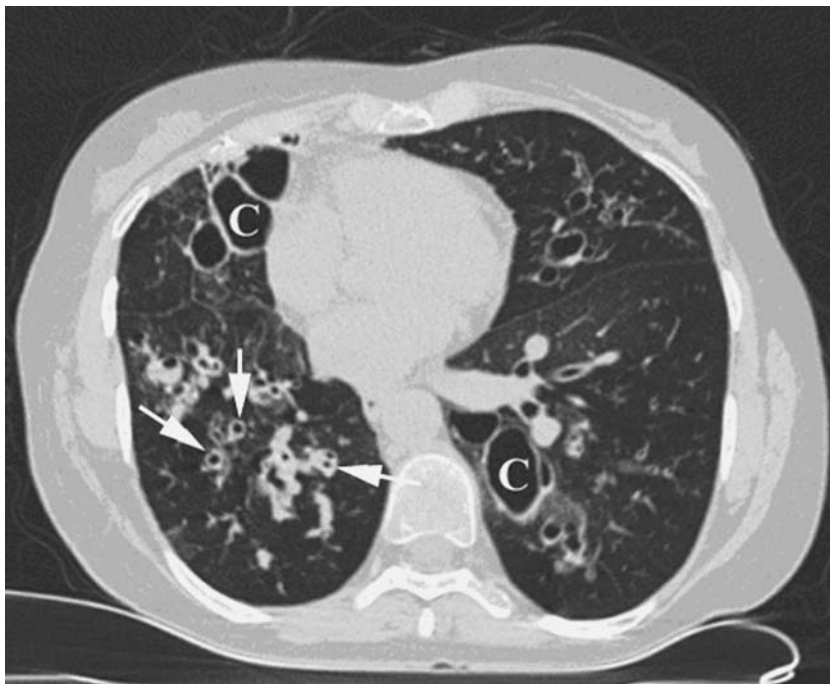**Bronchiectasis.** There is widespread bronchial wall abnormality in both lungs, but particularly in the right lung. In the right lower zone, there is marked bronchial wall thickening (remember that the normal bronchial wall should be 'pencil line' thin) with 'tram lines' visible.

## Differential diagnosis

- Bronchiectasis may be difficult to appreciate on plain films and even sometimes on CT.
- The main differential on plain films and CT lies with the honeycombing seen in advanced pulmonary fibrosis.
- On CT, bullous emphysema can mimic cystic bronchiectasis. However, expiratory films confirm air trapping in emphysema and a degree of airway collapse in bronchiectasis.

## Management

- Regular postural physiotherapy with mucus drainage.
- Early use of antibiotics, sometimes with long-term prophylactic regimes.
- Bronchodilators may help in acute infective attacks associated with bronchospasm.



**Bronchiectasis (HRCT).** Widespread cystic dilatation of the bronchi (C), predominantly in the middle and left lower lobes. Note the marked bronchial wall thickening and several 'signet rings' (arrows) in the right lower lobe.



# Bronchocele

## Characteristics

- Mucoïd impaction from accumulated inspissated secretions within the bronchial lumen. Usually associated with bronchial dilatation.
- Associated with bronchial obstruction – neoplasm, adenoma and atresia.
- Associated without bronchial obstruction – asthma, cystic fibrosis and infection.

## Clinical features

- Variable symptoms including shortness of breath, cough, purulent sputum and haemoptysis. Some patients may be asymptomatic (e.g. bronchial atresia).
- There may be history of chronic illness.

## Radiological features

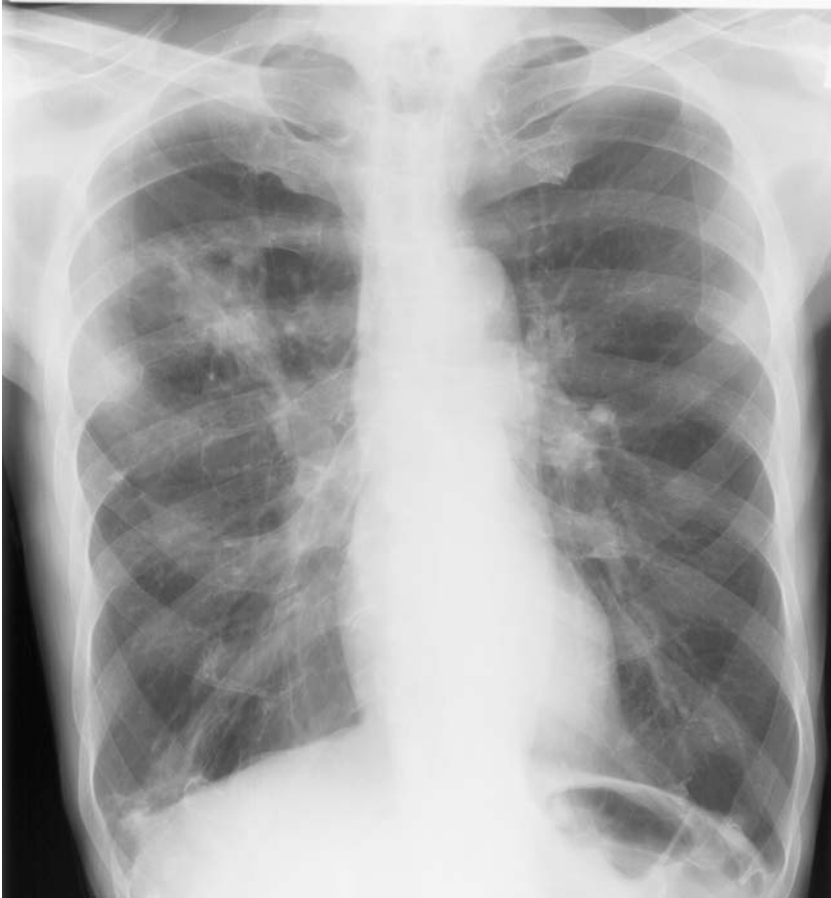- **CXR** – the lesion may be solitary or multiple, often measuring in excess of 1 cm in diameter with branching ‘fingers’ extending towards the periphery, the so-called gloved finger shadow. There may be air trapping and lucency distal to the bronchocele. Sometimes the obstructing lesion produces lung collapse, making it impossible to identify the bronchocele on CXRs.
- **CT** – confirms the plain film changes with dilated mucus-filled bronchi ± distal air trapping. The CT is very good for identifying obstructing neoplastic masses and demonstrating bronchoceles in a region of lung collapse.

## Differential diagnosis

- The different potential causes of bronchoceles. A good clinical history coupled with cross-sectional imaging is usually diagnostic.

## Management

- Removal of the obstructing lesion may be necessary. Bronchoscopy is a useful way of removing large mucus plugs and obtaining a tissue diagnosis from neoplastic masses.
- Non-obstructing lesions require physiotherapy and antibiotic administration.



**Bronchocele.** Right upper lobe bronchocele.

# Calcified granulomata

## Characteristics

- Solitary or multiple calcified nodules within the lung. They are often small, widespread and punctate. Solitary granulomata, particularly post TB infection, can be large up to several centimetres in diameter.
- They represent a chronic healed immune reaction, within the lung, to the initial stimulus.
- Post infective causes – TB, post varicella pneumonia.
- Non-infectious causes – inhalation of organic and inorganic chemicals.

## Clinical features

- Patients often asymptomatic.
- Previous history of infection or exposure to inhalational chemical.
- Can develop a non-productive cough and shortness of breath.
- Small risk of a pneumothorax.

## Radiological features

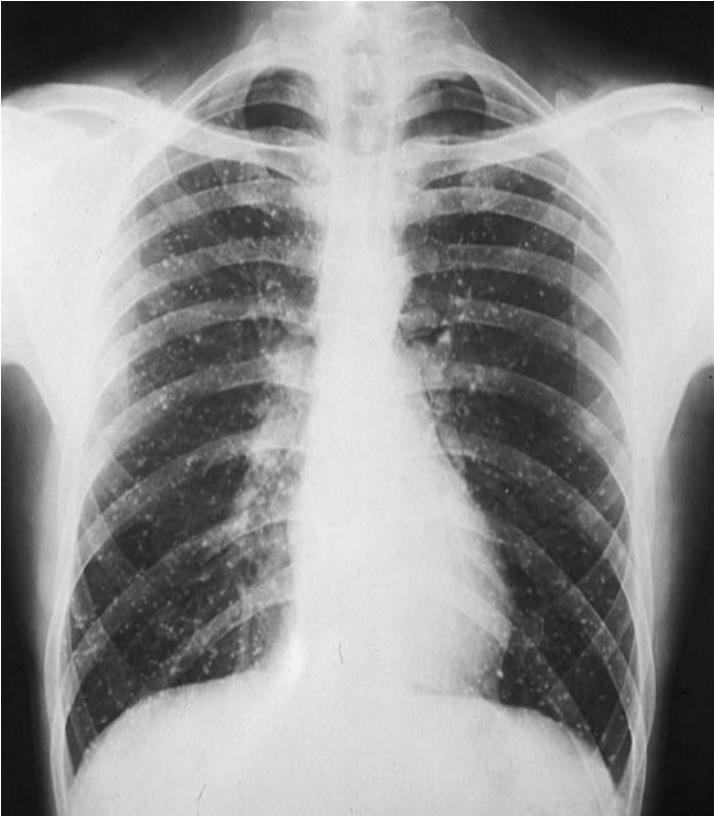- **CXR** – dense calcified sharply margined pulmonary nodules. They can be solitary, multiple, localised or widespread. Distribution may correlate with the underlying cause, e.g. previous TB in the upper lobes.
- There is no growth in size of the calcified nodules over time.

## Differential diagnosis

- Calcified lung metastases (e.g. breast, thyroid, osteosarcoma, ovarian, testicular and mucinous tumours). They can be multiple or solitary. They are often larger in size with an antecedent history supporting the primary neoplasm. Importantly they enlarge over time.
- ALWAYS COMPARE WITH OLD FILMS.
- If concerned repeat the CXR at an interval period in time.

## Management

- No active management required.
- No surveillance necessary.



**Calcified granulomata.** Multiple calcified nodules scattered throughout both lungs.

# Carcinoma

## Characteristics

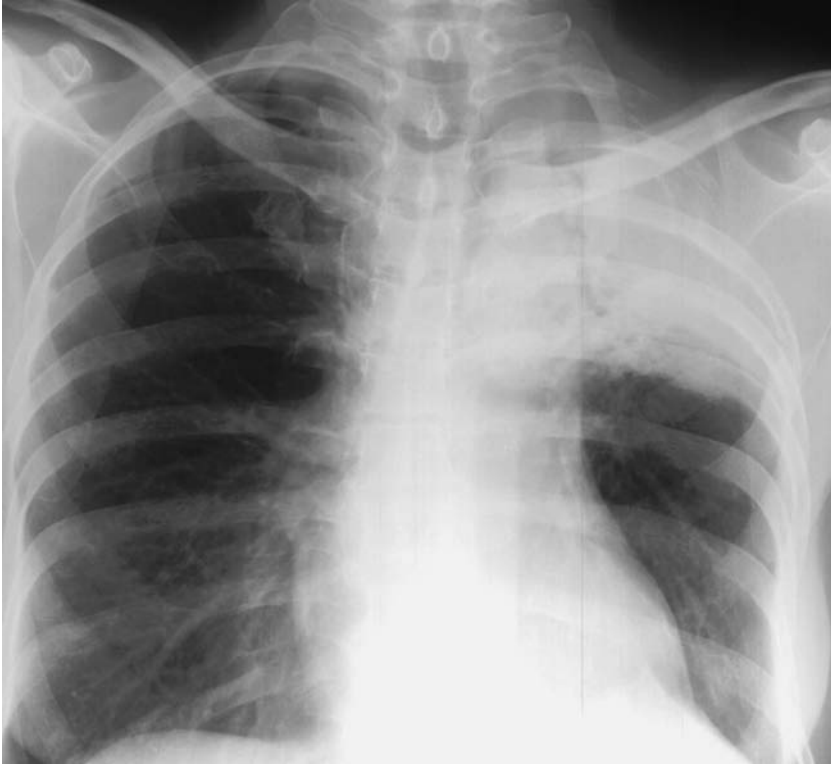- Primary lung cancer represents the leading cause of cancer deaths in both males and females, and is the commonest cancer in males.
- Strong association with smoking, exposure to industrial chemicals (e.g. asbestos).
- Age of onset usually  $> 40$ , but beware aggressive forms in a younger age group.
- Three main subtypes
  - Small cell (most aggressive) (SCLC).
  - Non-small cell (squamous, large cell and adenocarcinoma) (NSCLC).
  - Bronchoalveolar cell carcinoma (BAC).
- Clinical management depends on disease extent (staging) and importantly tumour type.

## Clinical features

- May be asymptomatic – identified on routine CXR.
- Any of the following symptoms, cough, SOB, wheeze and/or haemoptysis, raises the possibility of tumour presence.
- Chest pain, dysphagia or a hoarse voice from local extension of the tumour.
- Systemic upset – anorexia, cachexia, clubbing.
- Associated with metastatic spread – headaches, bone pain.
- Associated paraneoplastic syndromes with hormone release (Cushing's, acromegaly, gynaecomastia).

## Radiological features

- **CXR** – solitary peripheral mass. Central in 40%. The mass can be smooth or irregular in outline and can cavitate. Satellite nodules may be present. There may be hilar, paratracheal and/or mediastinal lymphadenopathy. Direct spread may result in rib destruction and extrathoracic extension. There may be distant rib metastases.
- Other **CXR** presentations include patchy consolidation that fails to respond to antibiotics (commonly BAC), pleural effusions, bronchoceles and lung collapse, which may be partial or complete (lobar/segmental).
- **CT** allows characterisation of the mass and full staging of the cancer
  - Size and location of the tumour.
  - Presence of lymphadenopathy.
  - Presence of metastases (bone, adrenals and liver).



**Carcinoma with rib destruction.** Dense opacification of the left upper lobe with associated destruction of the left second and third anterior ribs.

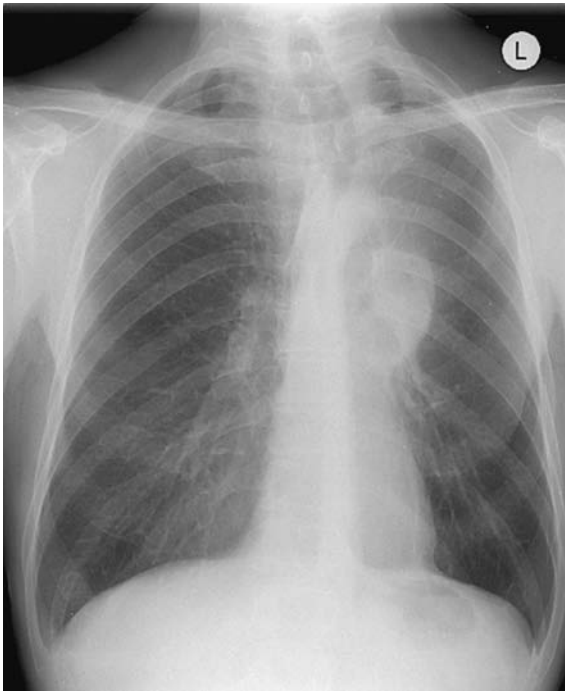
- **PET/CT** – increased uptake of FDG tracer in primary cancer and metastases. Sensitive tool for staging tumours and discriminating ambiguous mass lesions.

## Differential diagnosis (solitary pulmonary nodule)

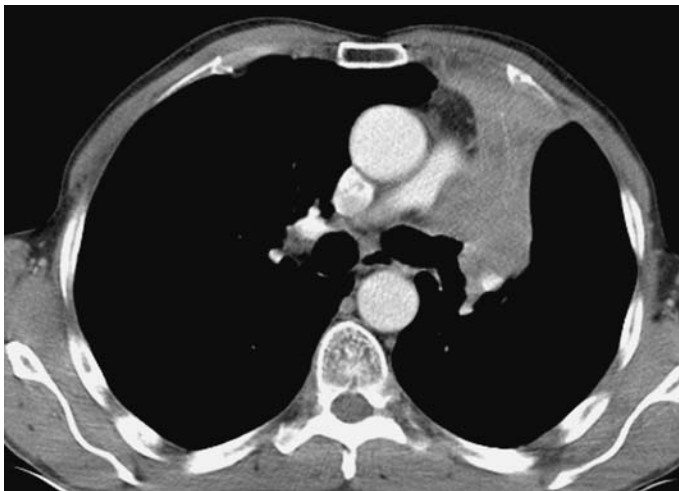
- Neoplasms – lymphoma, carcinoid, hamartoma and solitary metastasis.
- Inflammatory
  - Infective – granuloma, pneumonia or abscess.
  - Non-infective – rheumatoid arthritis, sarcoid, Wegener's.
- Congenital – arteriovenous malformation, pulmonary sequestration.
- Miscellaneous – pulmonary infarct, rounded atelectasis.

## Management

- Compare with old films – beware slow-growing squamous cell carcinomas.
- Tissue diagnosis is important – either with bronchoscopy or percutaneous biopsy (>90% sensitivity) of the primary tumour or metastatic deposit.
- Full tumour staging.
- Consideration for surgical resection (potentially curative) and/or chemoradiotherapy.
- Palliative treatment of symptoms (pain and hypercalcaemia).
- Screening has not shown any benefit in the early detection and treatment of lung cancer.



**Left hilar carcinoma – CXR.** Left hilar mass resulting in left upper lobe collapse.



**Left hilar carcinoma – CT.** CT confirms segmental collapse of the left upper lobe, secondary to an obstructing carcinoma at the left hilum.



# Cardiac aneurysm

## Characteristics

- A true aneurysm is a circumscribed non-contractile outpouching of the left ventricle.
- Although there is a very rare congenital form, the majority occur as a complication of myocardial infarction. It rarely ruptures, but patients are at risk of arrhythmias and thromboembolic events that occur from clot formation within the aneurysm.
- A pseudoaneurysm, or false cardiac aneurysm, occurs acutely following trauma or a myocardial infarction, with a focal left ventricular rupture, localised haematoma and a high risk of delayed rupture and death.

## Clinical features

- Most are asymptomatic and go without any problems.
- There is an association with arrhythmias, thromboembolic events and rarely cardiac failure.

## Radiological features

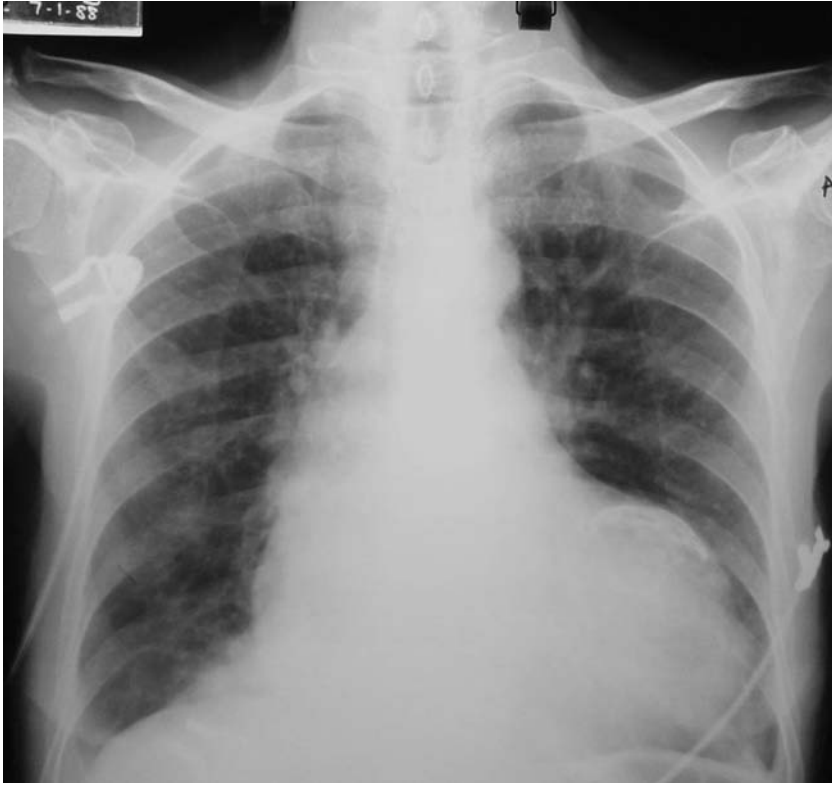- **CXR** – localised bulge in the left heart border. There is often a thin peripheral rim of calcification within the ventricular wall.
- **Echocardiography** – paradoxical movement of the left ventricular wall in systole is diagnostic. The aneurysm may contain thrombus.

## Differential diagnosis

- Previous TB pericarditis, with a background of ischaemic heart disease, can have a very similar appearance on a frontal CXR. A lateral view may show absence of the localised posterior LV aneurysm. Echocardiography allows accurate characterisation of both pathologies.

## Management

- No active treatment necessary.
- Occasionally anticoagulation for mural thrombus formation is needed.



**Calcified cardiac aneurysm.** Note the localised bulge in the left heart border, with curvilinear calcification in the left ventricular wall.

# Chronic obstructive pulmonary disease

## Characteristics

- General term encompassing a spectrum of conditions including chronic bronchitis and emphysema.
- Characterised by chronic resistance to expiratory airflow from infection, mucosal oedema, bronchospasm and bronchoconstriction, due to reduced lung elasticity.
- Causative factors include smoking, chronic asthma, alpha-1 antitrypsin deficiency and chronic infection.

## Clinical features

- Exacerbations commonly precipitated by infection.
- Cough, wheeze and exertional dyspnoea.
- Tachypnoea, wheeze, lip pursing (a form of PEEP), use of accessory muscles.
- Cyanosis, plethora and signs of right heart failure suggest severe disease and cor pulmonale.
- Signs of hypercarbia include coarse tremor, bounding pulse, peripheral vasodilatation, drowsiness, confusion or an obtunded patient.

## Radiological features

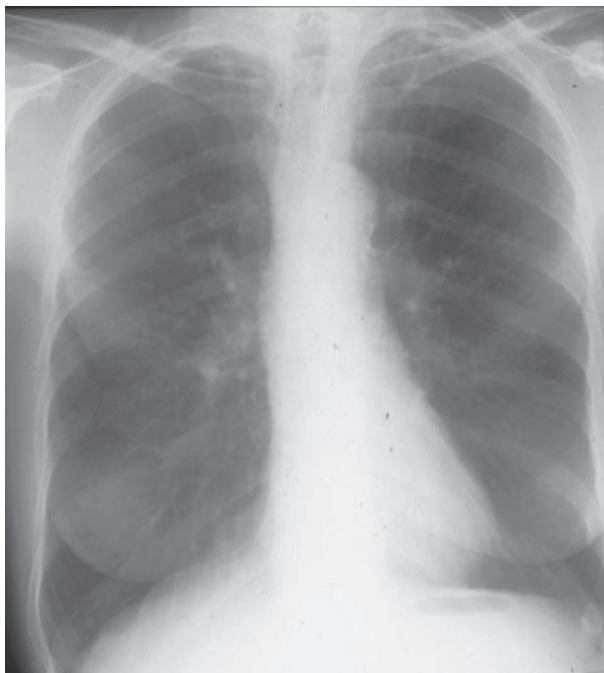- **CXR** – only moderately sensitive (40–60%), but highly specific in appearance. Is an easily accessible method of assessing the extent and degree of structural parenchymal damage.
- Assessment for complications such as pneumonia, lobar collapse/atelectasis, pneumothorax or mimics of COPD.
- **CXR** features include hyper-expanded lungs with associated flattening of both hemi-diaphragms, 'barrel-shaped chest', lung bullae, coarse irregular lung markings (thickened dilated bronchi) and enlargement of the central pulmonary arteries in keeping with pulmonary arterial hypertension.
- **REMEMBER** to look for lung malignancy/nodules; a common association.
- **CT** – quantifies the extent, type and location of emphysema and bronchial wall thickening. It may also identify occult malignancy.

## Differential diagnosis

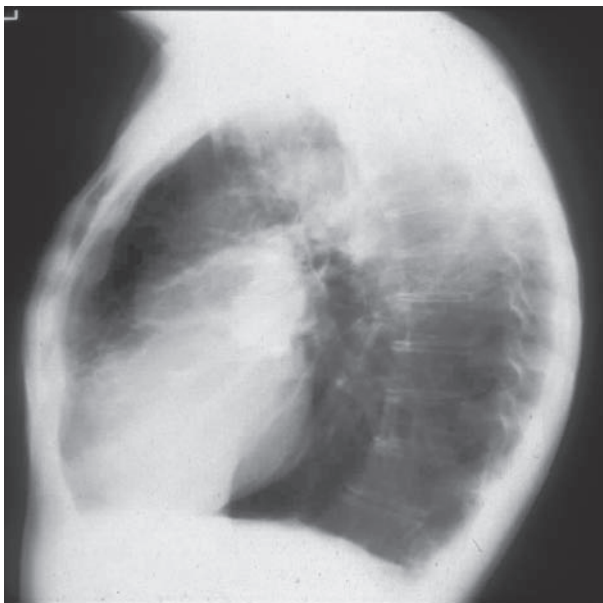- Lymphangioleiomyomatosis (LAM) and Langerhan's cell histiocytosis (LCH) can have a similar CXR and CT appearance. The clinical history and imaging together are diagnostic.
- Asthma  $\pm$  superimposed infection.
- Extrinsic allergic alveolitis.
- Viral infections.

## Management

- Supplemental oxygen tailored to keep  $pO_2 > 7.5$  kPa. Beware high concentrations of supplemental  $pO_2$ , as patients fail to expel the  $CO_2$  and develop high  $pCO_2$  levels.
- Nebulised bronchodilators (oxygen or air driven where appropriate). Adding nebulised ipratropium bromide may help.
- Consider an aminophylline or salbutamol infusion.
- Corticosteroids unless contraindicated.
- Appropriate antibiotics should be given if infection suspected.
- Ventilation or BiPAP can be considered.
- Long-term management may include
  - Long-term home oxygen.
  - Lung reduction surgery.



**Chronic obstructive pulmonary disease.** The lungs are hyperinflated with flattening of both hemidiaphragms. On the lateral view, the chest appears 'barrel-shaped' due to an increase in the retro-sternal air space.



**Fig. (cont.)**

# Coarctation of the aorta

## Characteristics

- Congenital narrowing at the junction of the aortic arch and descending aorta, secondary to a fibrous ridge protruding into the aortic lumen.
- 80% male.
- 50% associated with other congenital anomalies:
  - Bicuspid aortic valve.
  - Turner's syndrome.
  - PDA, VSD.
  - Cerebral Berry aneurysms.
- Second most common cause of cardiac failure in neonates.
- May remain undetected well into adult life.

## Clinical features

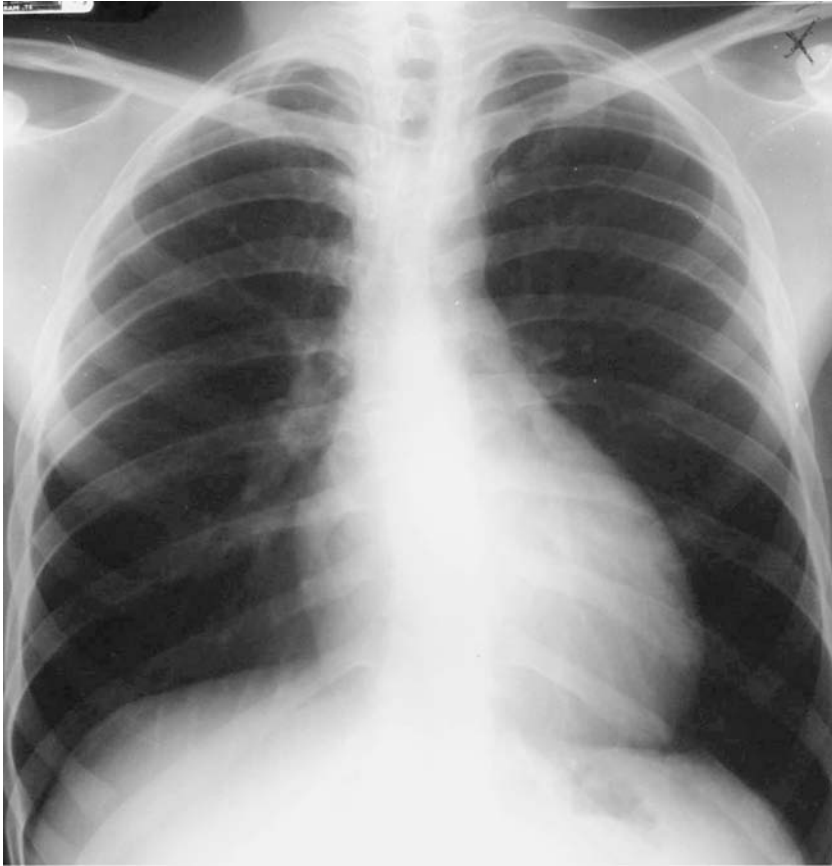- Symptomatic presentation in neonates includes tachypnoea, cyanosis and generalised oedema. Patients require urgent corrective surgery. Most cases are now identified on neonatal screening.
- Delayed presentation in adults includes hypertension, headaches, claudication, cardiac failure and renal impairment.
- Patients may have cardiac systolic heart murmurs sometimes heard over the back and 'pistol shot' femoral pulses.

## Radiological features

- Neonates – cardiomegaly and pulmonary plethora.
- Adults – **CXR**
  - Inferior rib notching (ribs 3–9), may be unilateral depending on where the right subclavian branches from the aorta. Only visible after 7 years of age.
  - Small aortic knuckle.
  - Figure-3 indentation on the left lateral wall of the aortic arch. The reverse-3 is present on barium studies.
  - Elevated left ventricular apex secondary to hypertrophy.
- **MRI** is very good at characterising the coarctation and associated cardiac anomalies.
- The extent of the stenosis is very difficult to assess on imaging.

## Differential diagnosis

- Pseudo-coarctation – no pressure gradient across a narrowing in the aortic calibre – no obstruction.



**Coarctation of aorta.** Note the rib notching and the 'figure of 3' arch of aorta

- Inflammatory conditions such as Takayasu's arteritis can have similar radiological features.
- Chronic SVC, IVC or subclavian artery obstruction may have similar radiological features.

**Management**

- Angioplasty and stenting.
- Surgical repair.
- Hypertension control.



# Collapsed lung

## Characteristics

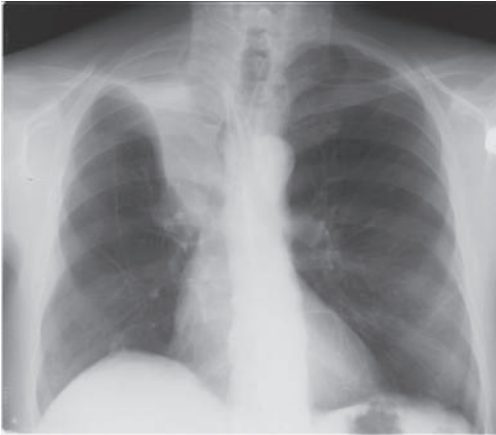- Lung collapse or atelectasis can affect the whole lung, a single lobe or a segmental component. The lobar collapses are important not to miss on imaging. They may be associated with an underlying malignancy.
- Causes are either obstructive or non-obstructive.
- Obstructive
  - Tumour which may lie outside or inside the bronchus or within the bronchial wall.
  - Foreign body.
  - Mucus plug.
  - Stricture – inflammatory, amyloidosis.
  - Bronchial rupture.
- Non-obstructive
  - Pleural effusions and pulmonary fibrosis.

## Clinical features

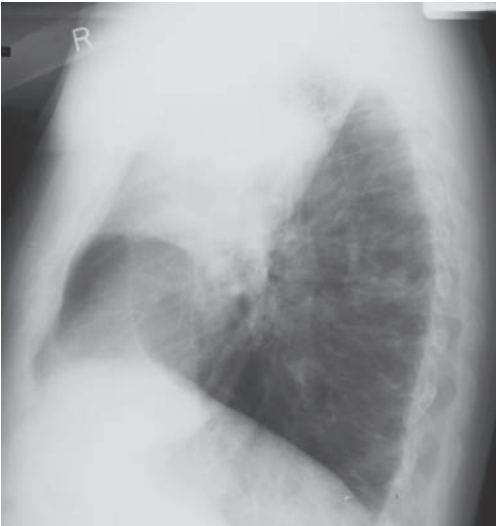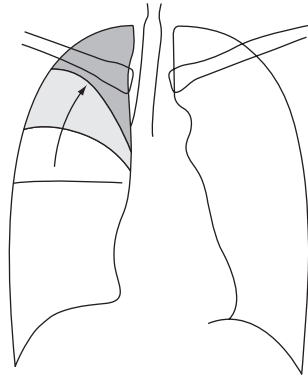
- SOB, cough, haemoptysis, purulent sputum.
- Patients may be asymptomatic.
- Patients may have symptoms related to an underlying systemic condition including weight loss, cachexia, anorexia and night sweats.

## Radiological features

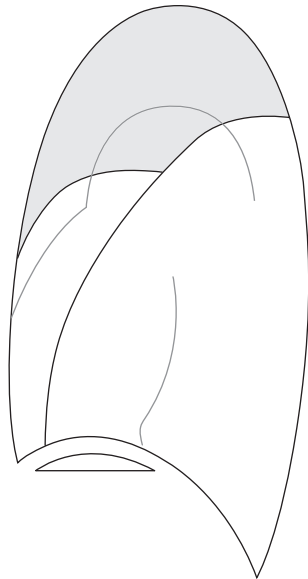
- It is important to recognise the common lobar collapses on a frontal **CXR**.
- Significantly in adults upper lobe collapse is almost always associated with primary lung malignancy (>95%).
- **Left upper lobe** – veiled opacification throughout the left hemithorax with obscuration of the left heart border. Visible left margin of the aortic arch (Luftsichel sign). Horizontal orientation and splaying of the lower lobe bronchovascular markings. Almost all cases have a proximal tumour which may only be visible on **CT** scans.
- **Left lower lobe** – reduced lung volume. Small left hilum. Triangular density behind the heart with obscuration of the medial aspect of the left hemidiaphragm. Bronchial reorientation in a vertical direction.
- **Right upper lobe** – reduced lung volume. Elevated right hilum. Triangular density abutting right medial mediastinum. A mass lesion at the right hilum may be present (Golden – S sign).
- **Right middle lobe** – obscuration of the right heart border. A **lateral CXR** may be necessary to confirm the collapse.



**RUL collapse – PA.**



**RUL collapse – Lat.**



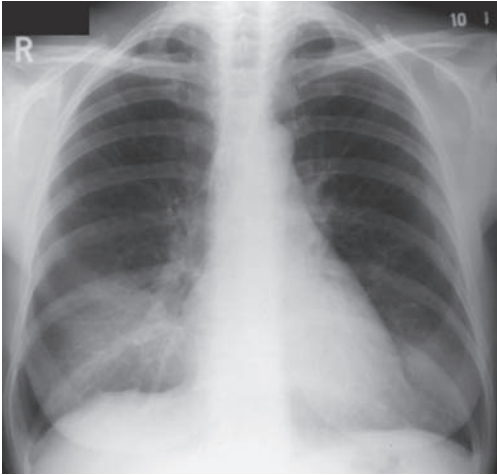
- **Right lower lobe** – Reduced lung volume. Triangular density medially at the right base obscuring the medial aspect of the right hemidiaphragm. Bronchial reorientation in a vertical direction.
- **Total lung collapse** – causes include misplaced endotracheal tube or large proximal tumour. Opacification of affected hemithorax with mediastinal shift to the collapsed lung.

## Differential diagnosis

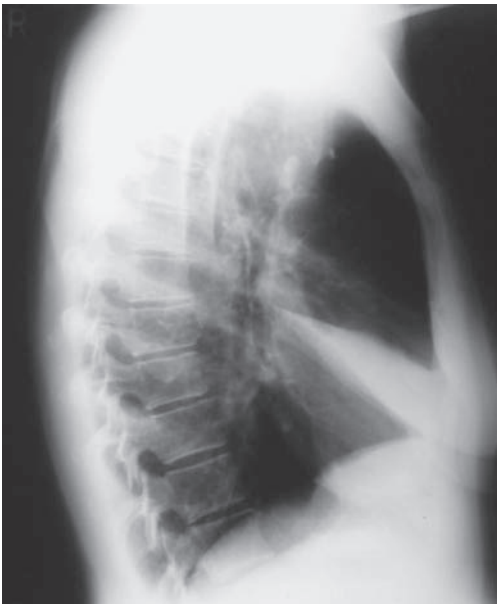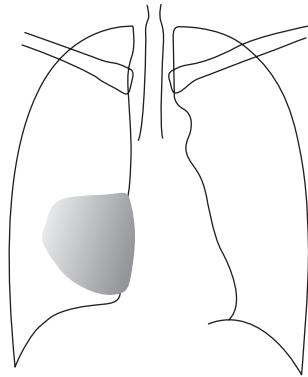
- Lobar consolidation may have similar appearances. Lateral chest films and the demonstration of lung volume loss in collapse are diagnostic.
- Hiatus hernias may mimic lower lobe collapse.
- Post pneumonectomy lungs may demonstrate volume loss and bronchial reorientation.

## Management

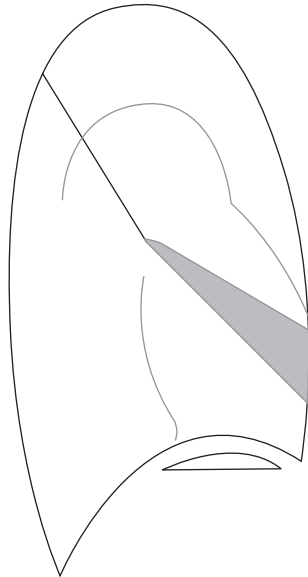
- Bronchoscopy may be both diagnostic and in some cases therapeutic.
- CT scan to confirm underlying cause.
- In malignant collapse, radiotherapy and bronchial stenting can be of benefit.

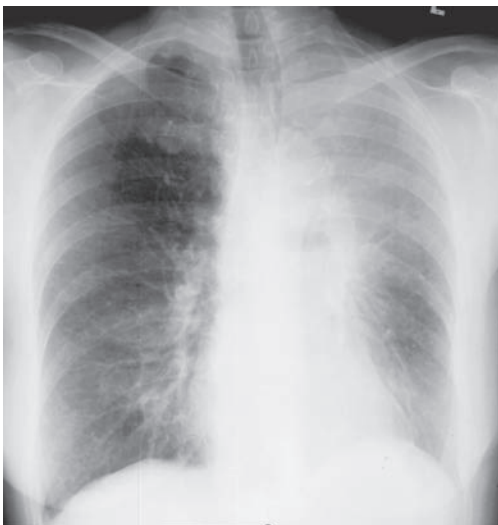

**RML collapse – PA.**

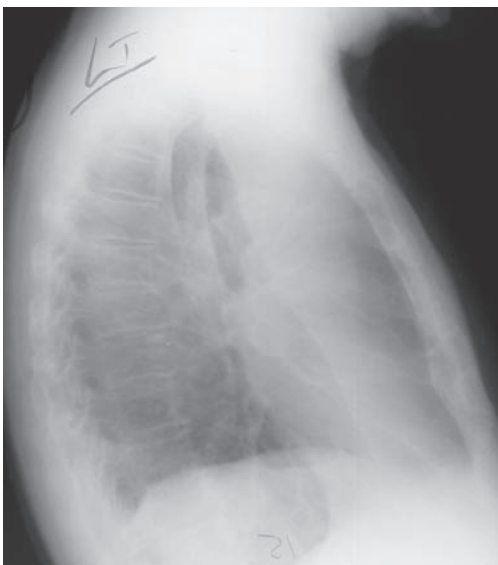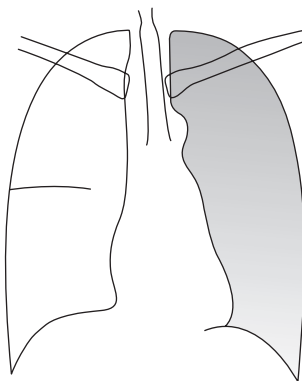


**RML collapse – Lat.**

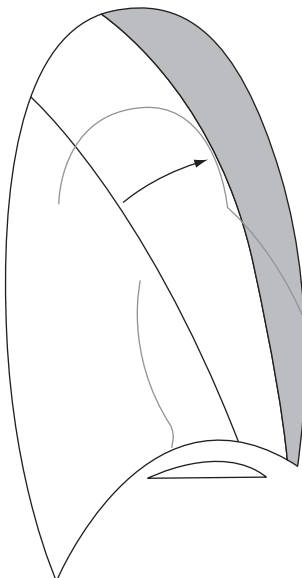


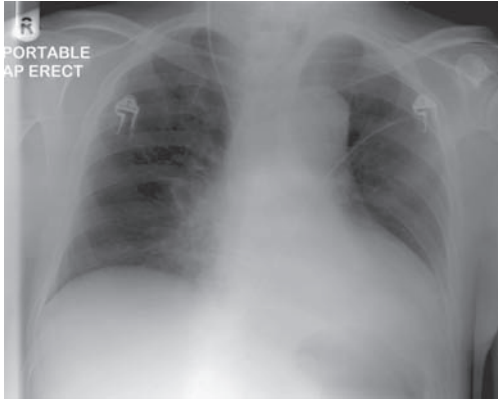


**LUL collapse – PA.**

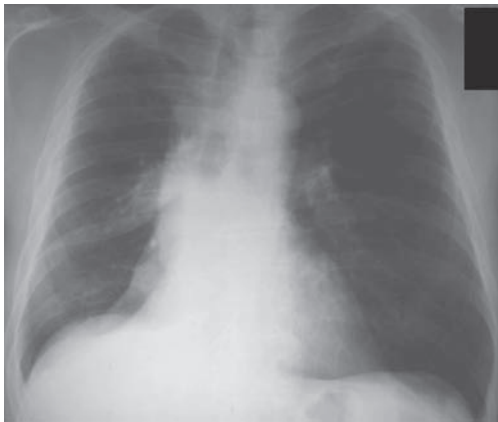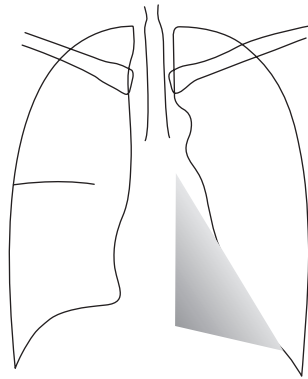


**LUL collapse – Lat.**

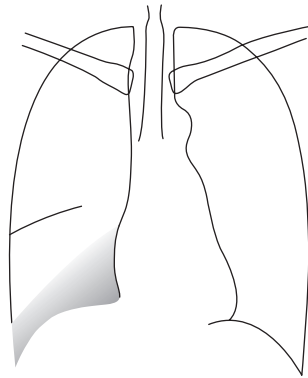


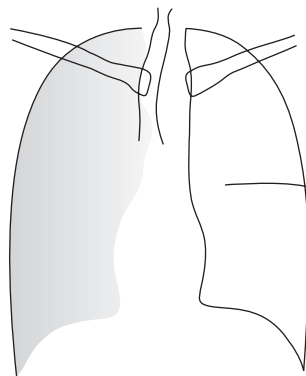
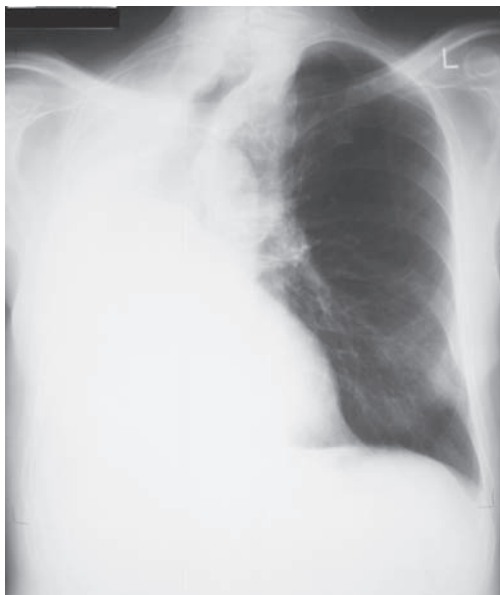


**LLL collapse – PA.**

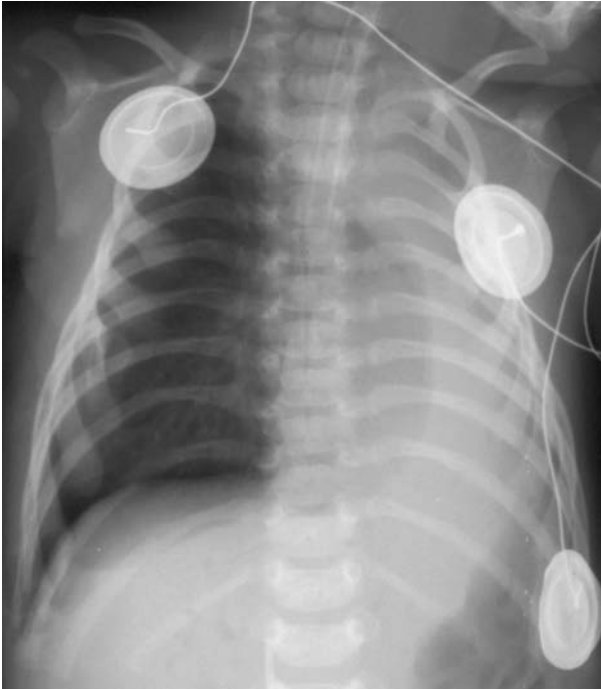

**RLL collapse – PA.**





**Total lung collapse** secondary to an obstructing bronchial carcinoma – PA.



**Total lung collapse** secondary to an incorrectly sited endotracheal tube – PA.



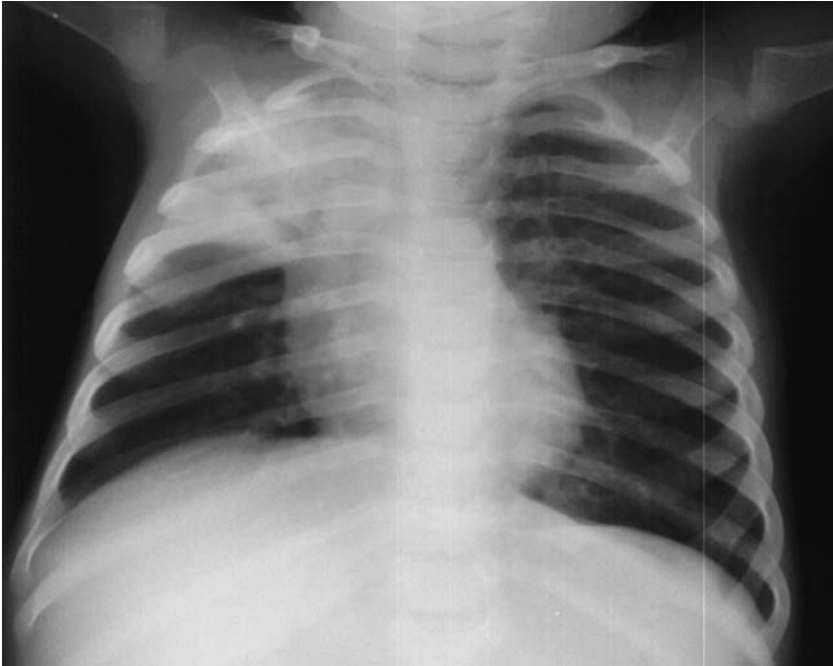
## Consolidated lung

### Characteristics

- **Infectious** or **non-infectious** causes.
- *Infectious*:
  - Incidence is increasing – due to an ageing population and the increased prevalence of immunosuppression.
  - Community acquired – *Streptococcus* (>60%), *Haemophilus*, *Mycoplasma*, *Legionella* and *Chlamydia*. Generally low mortality unless admission required.
  - Hospital acquired – increasing Gram-negative infection. Higher mortality rate than community-acquired pneumonias. Co-morbid factors are important.
  - Pneumonia should always be considered in the elderly, the immunocompromised and in pyrexia of unknown origin (PUO).
  - The prevalence of TB is increasing. *Suspect it!*
- *Non-infectious*
  - Bronchoalveolar carcinoma.
  - Lymphoma.
  - Inflammatory conditions (Wegener's granulomatosis).
  - Cryptogenic organising pneumonia.
  - Cardiac failure.
  - Sarcoid.
- Always repeat imaging in cases of consolidation at an interval period to confirm resolution. Failure to resolve should alert the clinician to a non-infectious cause.

### Clinical features

- Productive cough, dyspnoea, pleuritic chest pain, myalgia and haemoptysis may occur.
- In the immunosuppressed patient, *Pneumocystis* may present with profound hypoxia and little else on examination.
- The young patient may present with vague symptoms such as headache, abdominal pain or even diarrhoea. Confusion may be the only sign in the elderly.
- Examination may reveal coarse inspiratory crepitations. Bronchial breathing with a dull percussion note is present in less than 25%.
- Poor prognostic signs include – age >60, respiratory rate >30, profound hypotension, acute confusion, urea >7 mmol/l and a markedly low or raised white cell count.



**Right upper lobe consolidation.** Dense opacification in the right upper zone containing air bronchograms.

## Radiological features

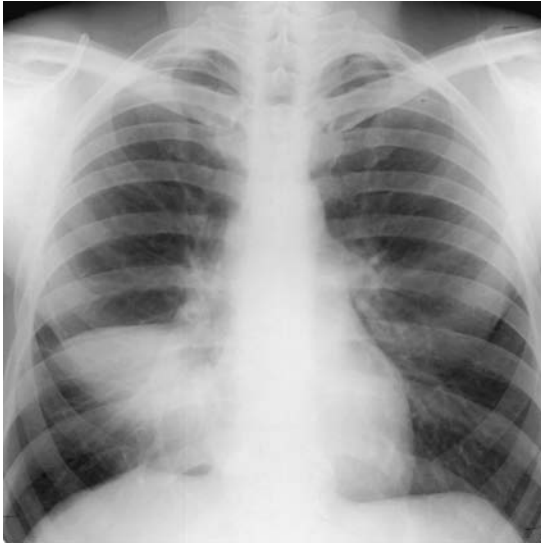- **May lag behind clinical onset and remain after resolution!**
- **CXR**
  - **Lobar pneumonia** – opacification of a lobe; usually *Streptococcus*. Air bronchograms may be present.
  - **Primary TB** – right paratracheal (40%) and right hilar adenopathy (60%) with consolidation in the mid or lower zones.
  - **Post primary TB** – ill-defined consolidation in the apical segments which may cavitate.
  - **Right middle and lower lobe pneumonia** – loss of the outline of the right heart border and the right hemidiaphragm silhouette respectively.
  - **Lingular segment pneumonia** – loss of the outline of the left heart border.
  - **Left lower lobe consolidation** – typically obliterates an arc of left hemidiaphragm. Look ‘through the heart’ for loss of diaphragmatic outline.
- FOLLOW-UP IMAGING IN ADULTS ESSENTIAL.
- FAILURE TO RESPOND TO ANTIBIOTICS MAY MEAN ANOTHER DIAGNOSIS SHOULD BE CONSIDERED.

## Differential diagnosis

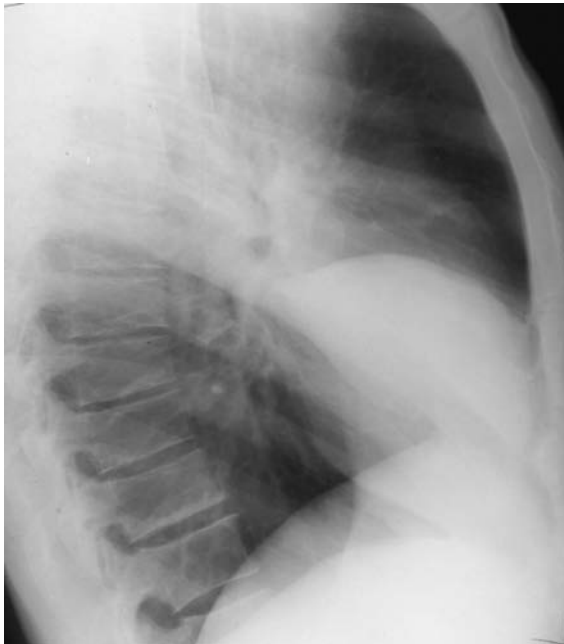- Bronchoalveolar carcinoma.
- Lymphoma.
- Inflammatory conditions (Wegener’s granulomatosis).
- Cryptogenic organising pneumonia.
- Cardiac failure.
- Sarcoid.

## Management

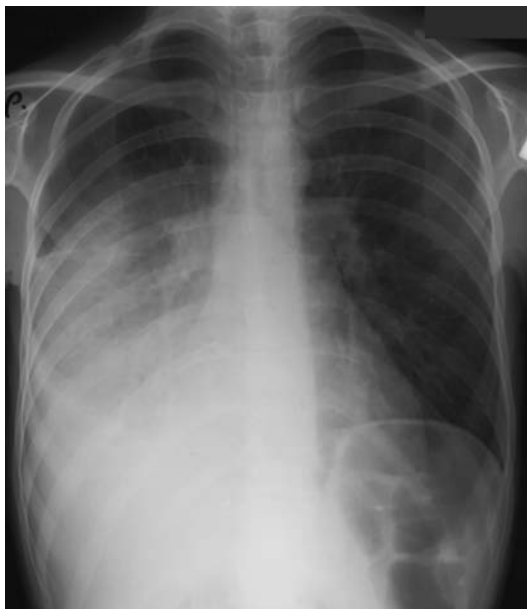- Most patients can be discharged with appropriate oral antibiotics.
- Give advice regarding deep breathing and coughing.
- A NSAID may be of benefit in patients with pleuritic pain to enable deep breathing and coughing.
- Treat the unwell patient with high flow oxygen (remember the patient with COPD is often dependent on their hypoxic drive to stimulate respiration), IV fluids, IV antibiotics ± analgesia.
- Follow-up imaging in adults.



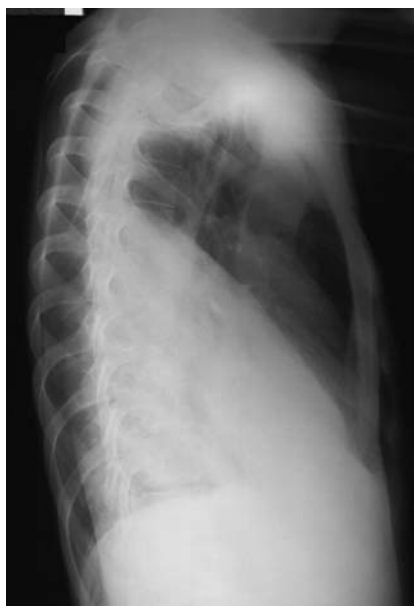**Right middle lobe consolidation – PA.** Dense opacification in the right mid zone; this abuts the horizontal fissure and effaces the right heart border.



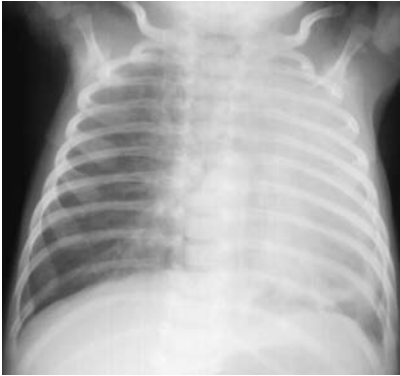**Right middle lobe consolidation – Lat.** The density lies between the horizontal and oblique fissures – the position of the middle lobe.



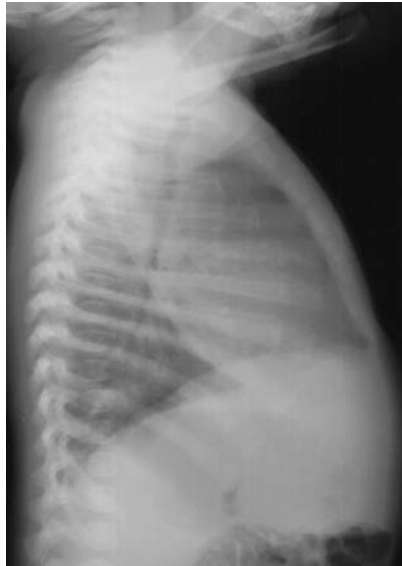**Right lower lobe consolidation – PA.** Dense opacification in the right lower zone with effacement of the outline of the right hemidiaphragm.



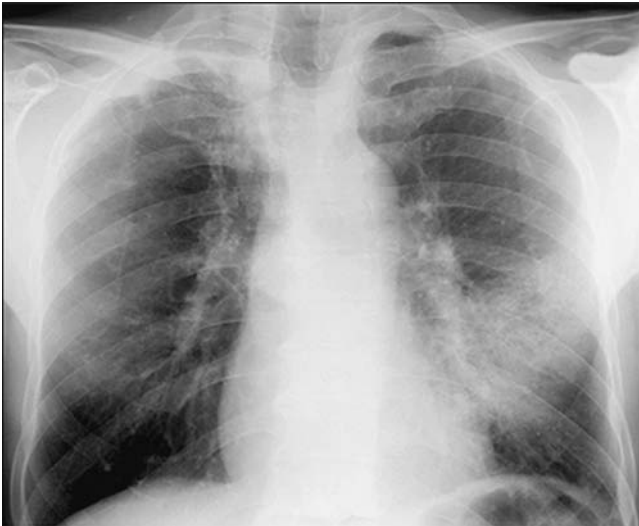**Right lower lobe consolidation – Lat.** The density lies posterior to the oblique fissure – the position of the lower lobe.



**Left upper lobe consolidation – PA.** Dense opacification of almost the entire left hemithorax. The left hemi-diaphragm remains visible.



**Left upper lobe consolidation – Lat.** The opacification is sited anterior to the oblique fissure – the position of the upper lobe.



**Lingular consolidation – PA.** Patchy effacement of the left heart border.

# Diaphragmatic hernia – acquired

## Characteristics

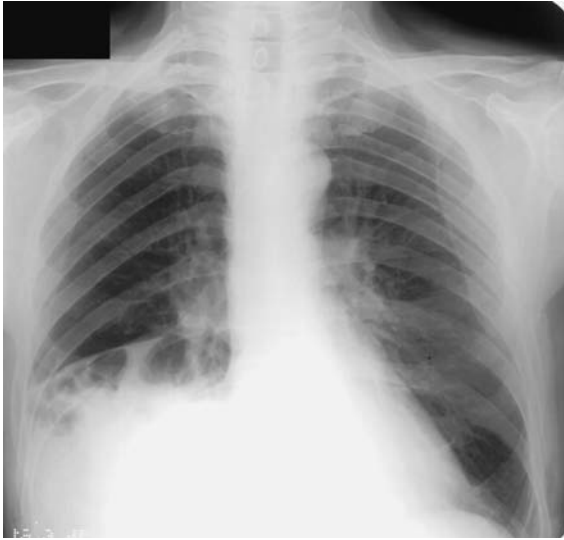
- Results from direct blunt or penetrating trauma to the chest/abdomen.
- Difficult to diagnose. Complications often present late, secondary to herniation of abdominal contents into the thoracic cavity. Visceral herniation may result in ischaemia, obstruction or perforation. Lung compression/collapse may be significant.
- More commonly affects the left side as liver is thought to protect the right.
- Postero-lateral radial tears are most commonly seen in blunt trauma.

## Clinical features

- In the acute setting features tend to be obscured by other injuries.
- Examination may reveal tachypnoea, hypotension, absence of breath sounds or bowel sounds within the chest.
- With time (months to years), symptoms are often vague with abdominal discomfort relating to herniation of abdominal viscera.
- Symptoms similar to those of peptic ulceration, gall bladder disease, dysfunctional bowel syndromes and even ischaemic heart disease may be seen.
- Rarely the patient may present with a tension viscerothorax mimicking a tension pneumothorax.
- Suspect in a patient with acute obstruction or unusual chest signs with a previous history of thoraco-abdominal trauma.

## Radiological features

- In the acute phase, unless there is visceral herniation, sensitivity is poor for all imaging modalities.
- **CXR**
  - Air-filled or solid-appearing viscus above the diaphragm. This may only be recognised following passage of a nasogastric tube.
  - Other features include mediastinal shift away from the affected side, diaphragmatic elevation, apparent unilateral pleural thickening or suspicious areas of atelectasis.
- In the non-acute setting contrast studies may be useful.
- **CT/MRI** ( $\pm 2D$  reformats) are good for demonstrating the site, size and contents of the hernia.



**Traumatic diaphragmatic hernia.** This patient sustained trauma many years earlier. Loops of bowel are seen in the lower right hemithorax having herniated through a diaphragmatic defect.

## Differential diagnosis

- The elevated hemidiaphragm may be long-standing from eventration, normal asymmetry or phrenic nerve palsy. Review of old films is very helpful.
- Lung collapse, consolidation, contusion or a pleural effusion may also be present making accurate diagnosis difficult.

## Management

- In the acute phase attend to the airway, breathing and circulation (ABCs).
- A nasogastric tube may decompress the gastrointestinal tract.
- If perforation is suspected treat sepsis early.
- Discuss urgently with the surgical team.
- Planned elective surgery for late presentations.



# Diaphragmatic hernia – congenital

## Characteristics

- Delayed fusion of the diaphragm around the 12th week in utero. There may also be delayed migration of the gut.
- Associated with other congenital anomalies.
- Majority occur on the left. Right-sided hernias are frequently fatal.
- Diagnosis is often made with US in utero. Associated with pulmonary hypoplasia.
- Intra-abdominal organs herniate through into thorax. These organs may infarct.
- Bochdalek Hernia represents a specific form of congenital hernia discussed separately in this book.

## Clinical features

- Presents in neonates with respiratory distress.
- Scaphoid abdomen.
- Older children may describe intermittent abdominal pains and/or altered bowel habit.

## Radiological features

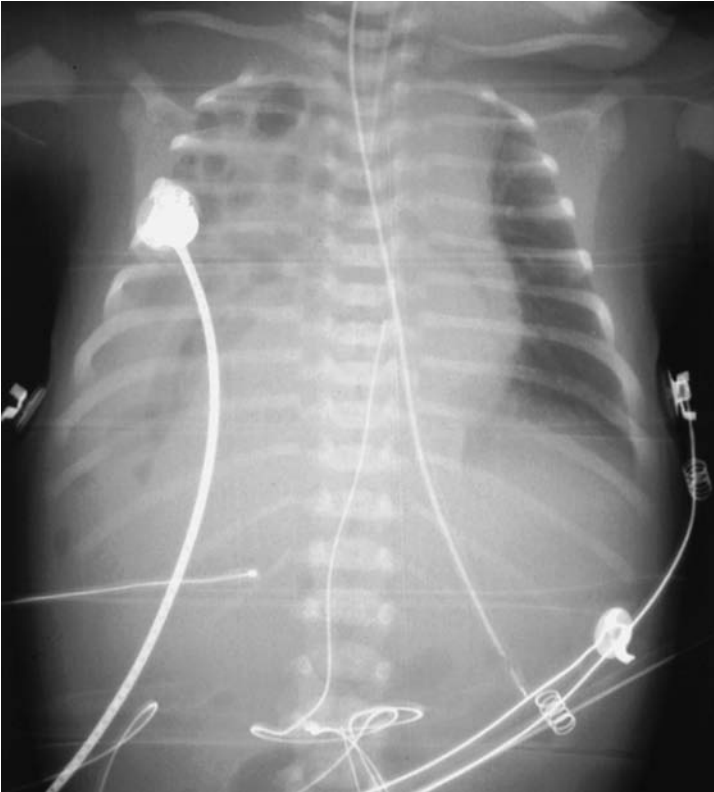
- **CXR** – small hemithorax. Opacity extending in continuity from the abdomen into the hemithorax. This may be homogeneous or contain lucent areas due to the presence of bowel. The opacity may occupy the whole lung. Pleural effusions and lung atelectasis may be present. NG tube may be curled within a stomach lying in the hemithorax. Paucity of bowel gas within the abdomen.
- **CT** and **MRI** with 2D reformats are helpful in establishing the size and location of the hernia.

## Differential diagnosis

- Congenital cystic adenomatoid malformation (CCAM) and pulmonary sequestration can have a similar appearance on a frontal CXR.
- A pleural effusion, particularly if subpulmonic, can also look like a diaphragmatic hernia in the neonate.

## Management

- ABC.
- Paediatricians present at delivery.
- Urgent surgical correction.



**Congenital diaphragmatic hernia.** This is a neonatal film. The right lung is opacified with multiple air-filled loops of bowel.

# Embotic disease

## Characteristics

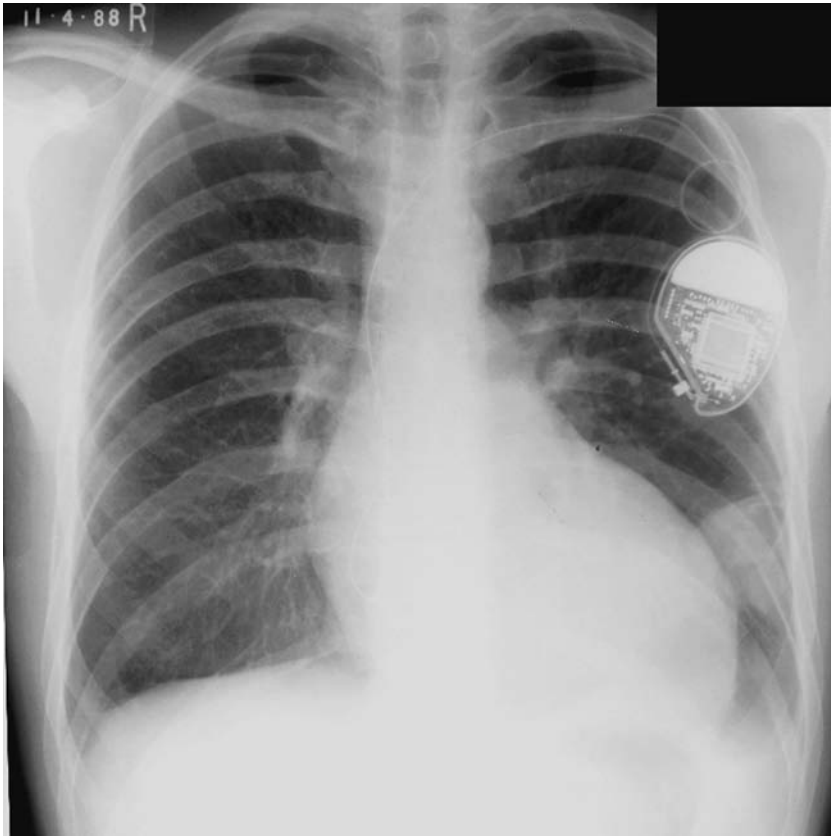- Pulmonary thromboembolism is a complication of deep vein thrombosis.
- If untreated there is a 30% mortality. If treated the mortality falls to <5%.
- Highest cause of maternal mortality in pregnancy.
- Associated with malignancy, immobility, thrombotic haematological disorders.
- D-Dimer blood test is very sensitive, but not very specific.
- Treatment is aimed at preventing further emboli.
- Patients with recurrent emboli may require long-term, sometimes lifelong, warfarin.
- Rarely emboli may represent fat emboli (following extensive lower limb/pelvic trauma) or tumour emboli. Fat embolus is rare and a distinct phenomenon. Patients present with acute SOB/collapse and dramatic CXR changes (extensive bilateral air space opacification similar to ARDS – adult respiratory distress syndrome).

## Clinical features

- SOB.
- Cough, haemoptysis.
- Pleuritic chest pain.
- Deep leg vein thrombus.
- Hypoxia.
- Hypotension, tachycardia.
- Pulmonary arterial hypertension with right heart strain and failure.
- Collapse.
- Sudden death.

## Radiological features

- **CXR** – may be normal.
- Other radiographic features of pulmonary embolic disease include:
  - Fleischner’s sign – local widening of pulmonary artery due to distension from clot.
  - Hampton’s hump – segmental pleurally based wedge-shaped opacity representing a pulmonary infarct.
  - Westermark’s sign – peripheral wedge-shaped lucency due to focal lung oligoemia.
- **Ventilation/perfusion scan** – mismatched perfusion defects.



**Pulmonary emboli.** A peripheral wedge-shaped density is seen in the left lower zone; representing a pulmonary infarct. This appearance is known as a 'Hampton's hump'.

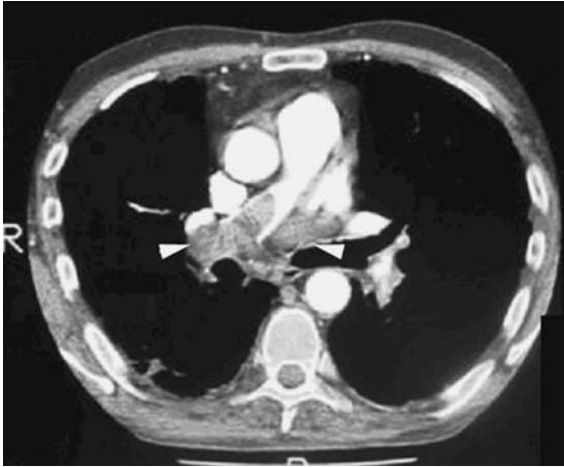- **CT scan (CTPA)** – filling defects within the pulmonary arterial tree on contrast-enhanced imaging. There may also be mosaic perfusion with reduced vasculature in the lucent areas.
- **Pulmonary angiography** – filling defects.
- **Echocardiography** – dilated right atrium with right ventricular hypertrophy and pulmonary arterial hypertension.

## Differential diagnosis

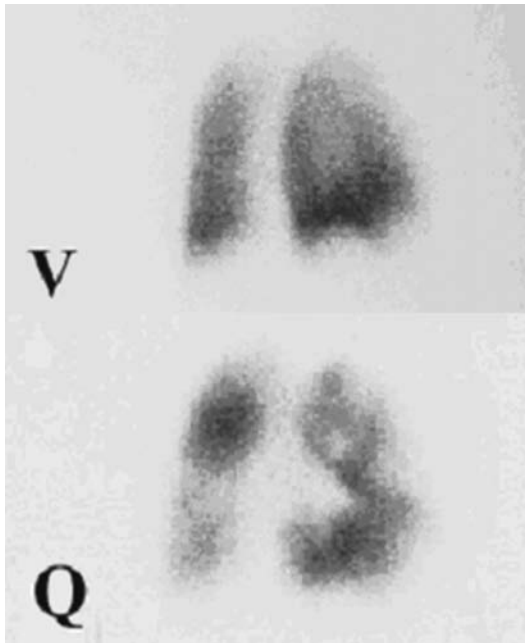
- The clinical presentation and CXR features are often non-specific and a number of conditions may mimic embolic disease (e.g. pneumothorax, infection, asthma and lung neoplasms).

## Management

- ABC.
- Oxygen.
- Anticoagulation if PE is confirmed.
- Extensive thromboemboli with hypotension and tachycardia may require treatment with thrombolysis.



**Pulmonary emboli – CTPA.** Large filling defects (arrowheads), representing emboli, are seen in the main pulmonary arteries.



**Pulmonary emboli –  $\dot{V}/\dot{Q}$ .** This demonstrates ‘ $\dot{V}/\dot{Q}$  mismatch’ – an abnormality of perfusion ( $\dot{Q}$ ) against a background of normal ventilation ( $\dot{V}$ ).

# Emphysematous bulla

## Characteristics

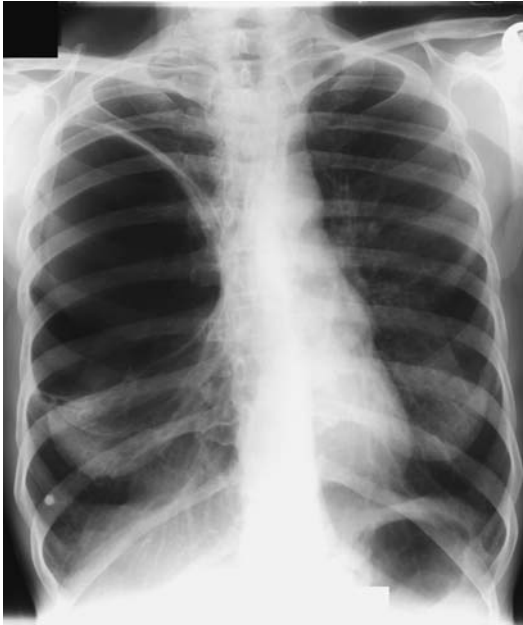- Abnormal permanent enlargement of distal air spaces with destruction of alveolar walls  $\pm$  lung fibrosis. Overlaps with chronic bronchitis to form a disease spectrum known as chronic obstructive pulmonary disease.
- Due to an imbalance between lung proteases and anti-proteases.
- A bulla is an avascular low attenuation area that is larger than 1 cm and has a thin but perceptible wall.
- Associated with smoking but other chemicals and genetic disorders predispose to the condition (e.g. alpha-1 antitrypsin deficiency).
- Three types of emphysema
  - Panacinar, centrilobular and paraseptal.
- The different types of emphysema may coexist.

## Clinical features

- May be asymptomatic, early in the disease.
- Exacerbations commonly precipitated by infection.
- Cough, wheeze and exertional dyspnoea.
- Tachypnoea, wheeze, lip pursing (a form of PEEP), use of accessory muscles (patients are referred to as pink puffers).
- Signs of hypercarbia include coarse tremor, bounding pulse, peripheral vasodilatation, drowsiness, confusion or an obtunded patient.

## Radiological features

- **CXR** – focal area of well-defined lucency outlined with a thin wall. A fluid level may indicate infection within the bulla.
- Other **CXR** features include hyperexpanded lungs with associated flattening of both hemi-diaphragms, ‘barrel-shaped chest’, coarse irregular lung markings (thickened dilated bronchi – chronic bronchitis overlaps) and enlargement of the central pulmonary arteries in keeping with pulmonary arterial hypertension.
- **REMEMBER** to look for lung malignancy/nodules; a common association.
- **CT** quantifies the extent, type and location of emphysema. It may also identify occult malignancy.



**Emphysematous bulla.** A large hypo-dense area, devoid of lung markings, is seen occupying most of the right lung. This compresses adjacent lung parenchyma.

### Differential diagnosis

- Post-infective pneumatoceles.
- Loculated pneumothorax.
- Oligaemia secondary to pulmonary emboli or hilar vascular compression.

### Management

- Emphysematous bullae form part of a spectrum of chronic obstructive pulmonary disease (see p. 62).
- Bullae in their own right usually need no active treatment. However, if severe disease, lung reduction surgery should be considered.



# Extrinsic allergic alveolitis

## Characteristics

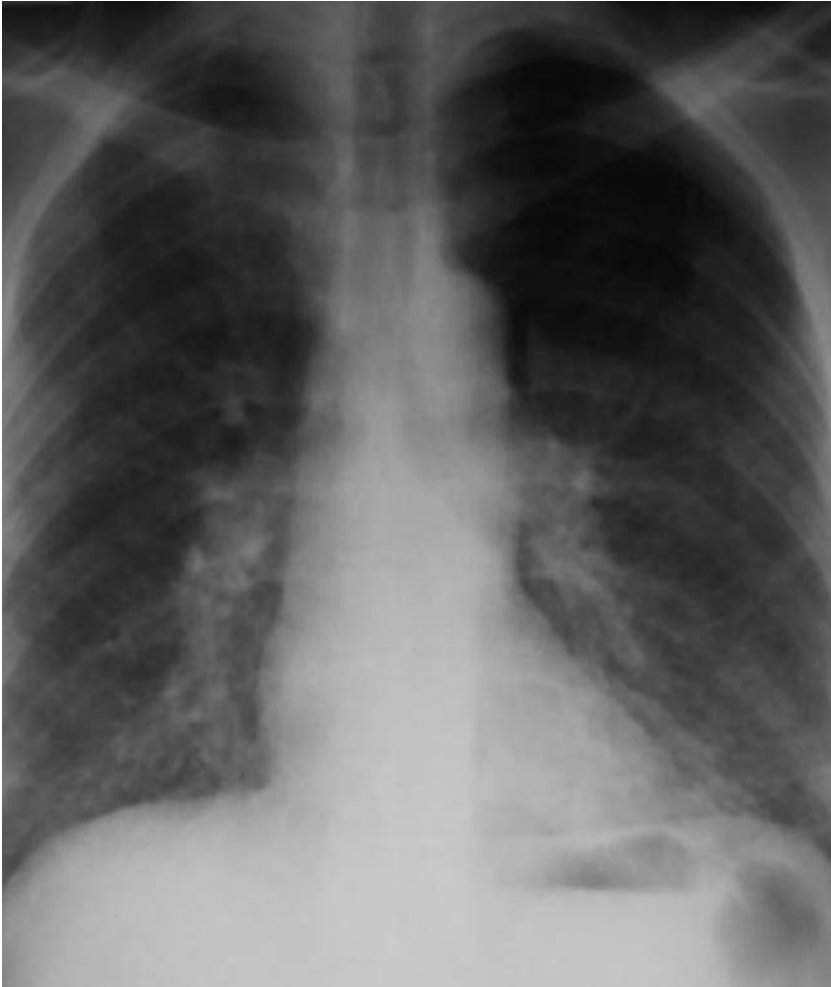- Also known as hypersensitivity pneumonitis.
- Represents an abnormal, exaggerated immune response to an inhaled organic allergen.
- Acute, subacute and chronic forms.
- Symptoms can develop after single or repeated exposures.
- Mixed type III and type IV immune reactions.
- Specific common antigens lead to specific conditions, e.g. farmer's lung (mouldy hay) and bird fancier's lung (droppings and feathers).

## Clinical features

- Diagnosis is made from a combination of clinical history, radiological features, exposure to antigen and improvement following the withdrawal of the causative antigen.
- Occurs at any age, usually middle age depending on opportunity for antigen exposure.
- 90% positive precipitating serum antigens (however, this only reflects exposure to the antigen and not definite evidence for the association of EAA).
- History may be acute, 4 h after exposure – dry cough, fever, SOB, malaise. Symptoms can resolve immediately after withdrawal of the causative antigen.
- Subacute and chronic forms – months to years to develop. Main symptom is progressive, insidious breathlessness.

## Radiological features

- Propensity for the middle lung zones, with sparing of the costophrenic angles and absolute apices.
- Radiology depends on the acute or chronic forms.
- **CXR**
  - Acute and subacute forms may be normal: patchy ground glass change and nodularity can be seen.
  - In the chronic form, fibrosis and parenchymal distortion are prominent features affecting the mid and upper zones.
- **HRCT**
  - Small round centrilobular nodules, with patchy ground glass attenuation and air trapping (mosaic perfusion).
  - Progression to the chronic form leads to interstitial thickening, honeycombing and traction bronchiectasis.



**Acute extrinsic allergic alveolitis.** A 37-year-old bird keeper, who had a 2-month history of cough, wheeze and mild SOB lasting for a few hours each day.

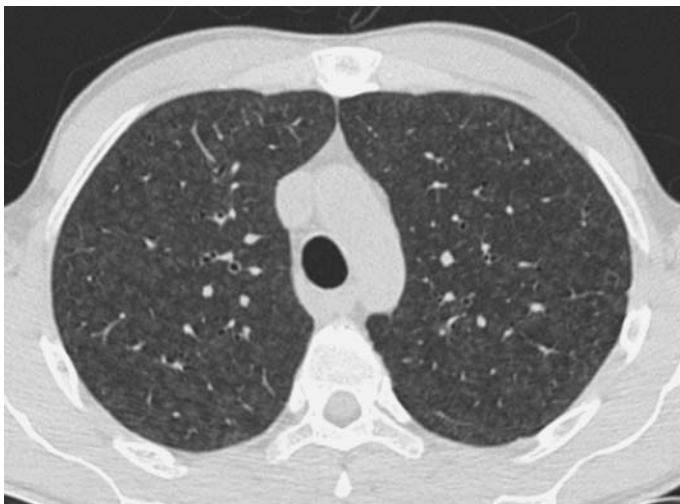There are bilateral small ill-defined ground glass nodules throughout both lungs. The features are non-specific and may represent infective changes, but the history and X-ray features are typical of a hypersensitivity pneumonitis (or acute EAA).

## Differential diagnosis

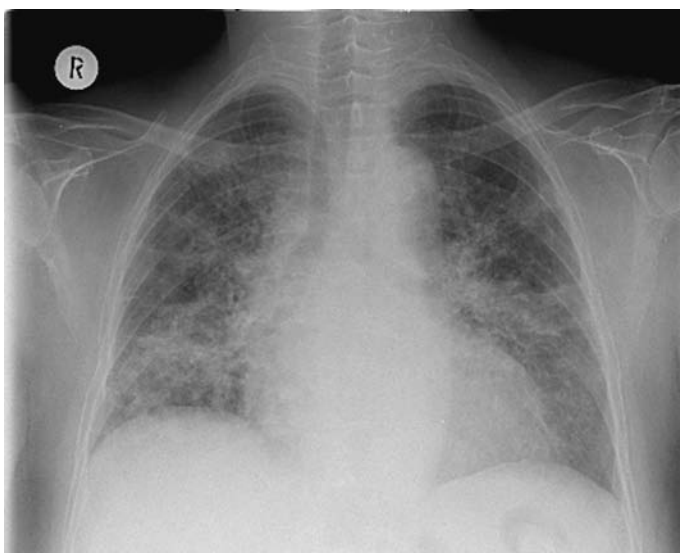
- Acute/subacute form
  - Infections, particularly TB and viral.
  - Obliterative bronchiolitis.
  - Chronic pulmonary embolic disease.
  - Early pulmonary metastatic disease.
- Chronic
  - Pulmonary fibrosis, e.g. UIP.
  - Chronic sarcoid.

## Management

- Removal of causative inhalational antigen.
- Steroids may help some individuals.



**Subacute extrinsic allergic alveolitis – HRCT.** Multiple small round centrilobular nodules throughout both lungs. Note the patchy air trapping (mosaic attenuation) within the left lung.



**Chronic extrinsic allergic alveolitis.** Fibrosis and parenchymal distortion are prominent within both mid zones and right lower zone.

# Flail chest

## Characteristics

- Occurs when there is loss of continuity of a segment of chest wall with the rest of the thoracic cage.
- Follows trauma, with two or more ribs fractured in two or more places.
- Results in disruption of normal chest wall movements, and paradoxical movement may be seen.
- Always consider underlying lung injury (pulmonary contusion).
- The combination of pain, decreased or paradoxical chest wall movements and underlying lung contusion are likely to contribute to the patient's hypoxia.
- High association with other accompanying traumatic injuries.

## Clinical features

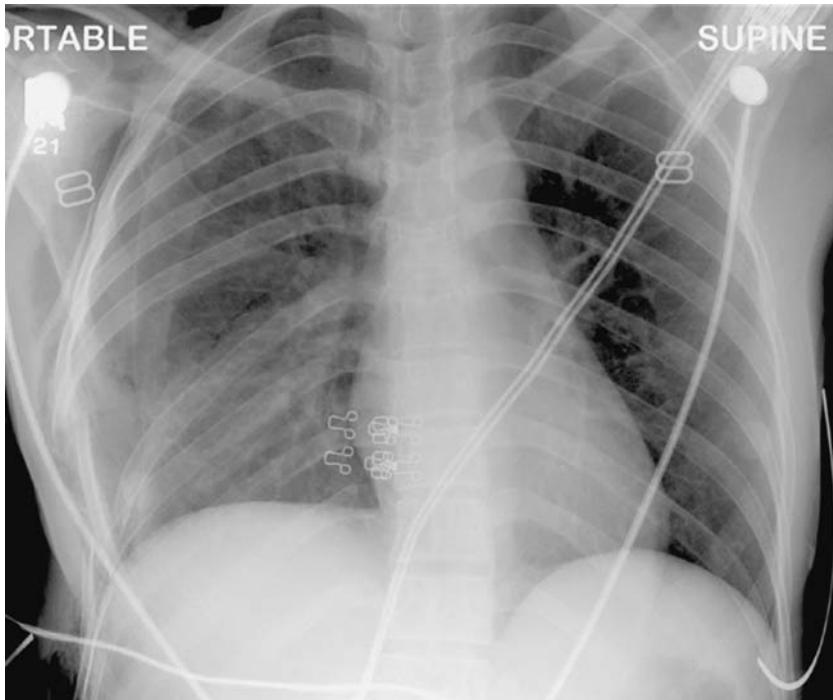
- Dyspnoea and hypoxia.
- Tachycardia.
- Cyanosis.
- Tachypnoea.
- Hypotension.
- Chest wall bruising  $\pm$  palpable abnormal movement or rib crepitus.
- The degree of hypoxia often depends on the severity of the underlying pulmonary contusion.

## Radiological features

- **CXR**
  - Multiple rib fractures.
  - Costochondral separation may not be evident.
  - Air space shadowing may be seen with pulmonary contusion (often absent on initial films).
  - There may be a pneumothorax, haemopneumothorax or lung collapse.

## Differential diagnosis

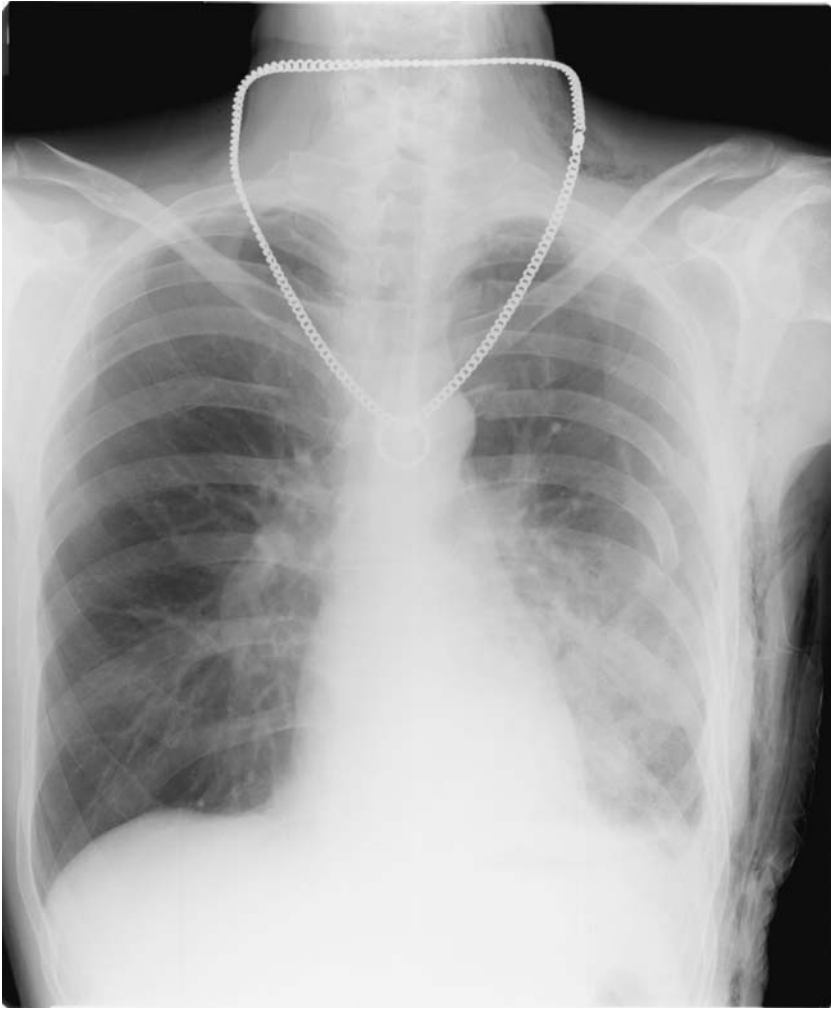- Simple rib fractures and pulmonary contusion with under ventilation secondary to chest wall pain.



**Flail chest – case I.** Multiple right-sided rib fractures. Note the double fracture of the right fifth rib.

## Management

- Initial management includes securing the airway and maximising oxygenation.
- In the absence of systemic hypotension, judicious fluid replacement is required as the injured lung is susceptible to both under resuscitation and fluid overload.
- Definitive treatment includes oxygenation and adequate analgesia to optimise ventilation/lung re-expansion.
- A pleural drain or ventilatory support may be necessary.
- Treat associated injuries.



**Flail chest – case 2.** Double fractures of the left posterior fifth and sixth ribs.



# Foregut duplication cyst

## Characteristics

- This is a broad term used to encompass a number of congenital mediastinal cysts derived from the embryological foregut. They include bronchogenic, oesophageal duplication and neuroenteric cysts.
- Bronchogenic cysts are the most common and are thin-walled cysts lined by respiratory epithelium lying within the mediastinum.
- Foregut cysts are often picked up incidentally.
- Symptoms are due to compression of local structures or secondary to cyst haemorrhage or infection. Rarely, in children symptoms can be quite severe particularly in neonates.

## Clinical features

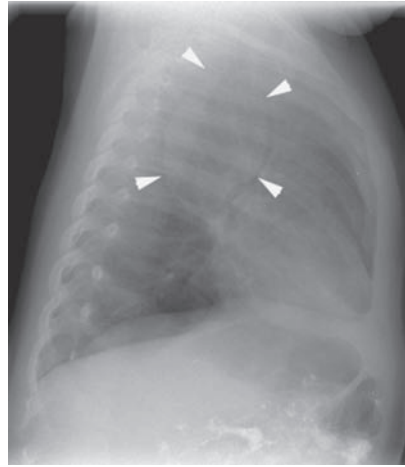
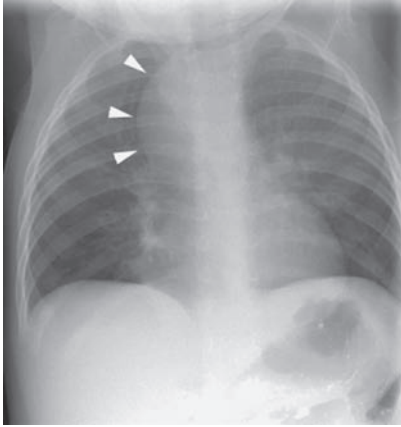
- Most are asymptomatic.
- Can present with chest pain, dysphagia, wheeze and shortness of breath.
- In children they can be large and, if the cyst grows, complications from airway compression can be life threatening.

## Radiological features

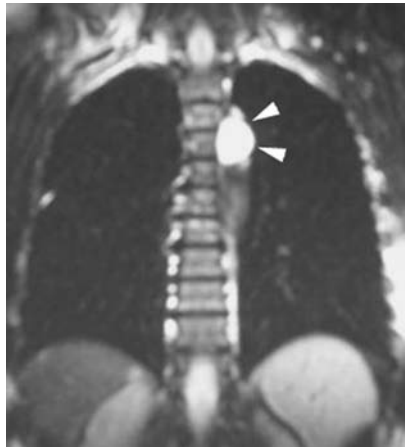
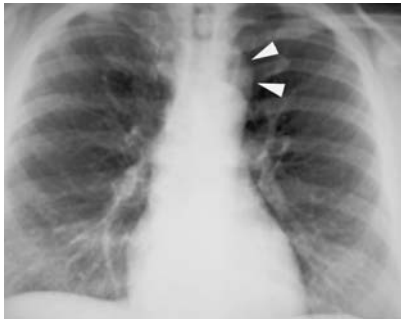- **CXR** – spherical or oval mass with smooth outlines projected either side of the mediastinum. Most are unilocular. They are usually located in the middle mediastinum adjacent to the carina. They tend to push the carina forward and oesophagus posteriorly which is almost unique to foregut cysts.
- **CT** demonstrates a water density cyst (HU 0). Occasionally high protein content or infection can cause soft tissue attenuation within a cyst. This can cause diagnostic difficulty. Wall enhancement suggests infection.
- **MRI** is also a good way of demonstrating the location and contents of the cyst.

## Differential diagnosis

- Pancreatic pseudocyst.
- Neurogenic tumour.
- Primary or secondary lung malignancy
- Lymphadenopathy, particularly necrotic tuberculous lymph nodes.



**Foregut duplication cyst – case 1.** Smooth round mass projecting from the right side of the mediastinum (arrowheads).



**Foregut duplication cyst – case 2.** Smooth mass projecting from the left side of the mediastinum above the aortic arch (arrowheads).

**Coronal T<sub>2</sub>-weighted MRI.** Elegantly demonstrates the lesion (arrowheads).

## Management

- If asymptomatic the cyst can be left alone.
- If there are atypical diagnostic features a biopsy and tissue sampling may be necessary.
- If symptomatic then surgical removal is indicated.

# Foreign body – inhaled

## Characteristics

- Usually seen in children.
- Considered an emergency as it may result in complete upper airway obstruction.

## Clinical features

- Complete upper airway obstruction with a distressed, agitated and choking child leading to unconsciousness. Some children may have mild symptoms such as a persistent cough or may even be asymptomatic.
- Auscultation of the chest may be normal. Monophonic wheeze is characteristic of large airway obstruction. Beware the localised absence of breath sounds.

## Radiological features

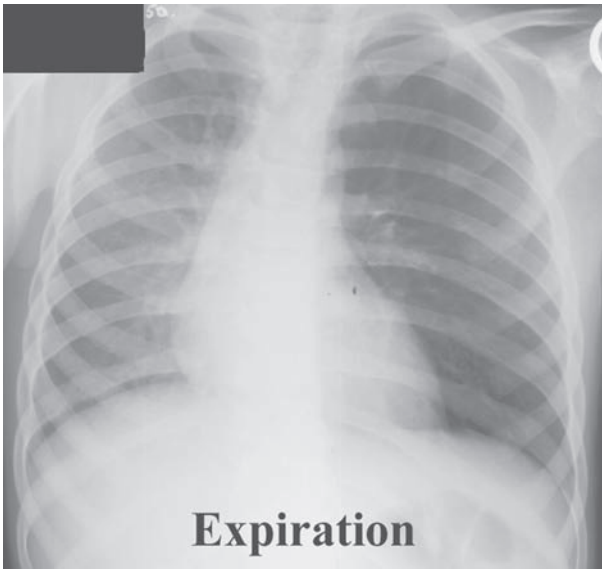
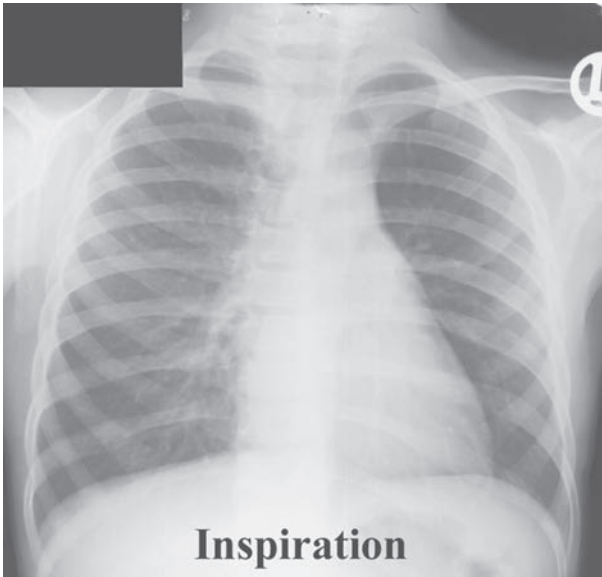
- **CXR**
  - A radio-opaque foreign body may or may not be seen.
  - Look for secondary signs such as loss of volume, segmental collapse, consolidation or hyperinflation as the foreign body acts as a ball valve. Expiratory films may be helpful in demonstrating air trapping distal to the FB.
  - If there is a high index of suspicion then further investigation with CT or bronchoscopy is advised.

## Differential diagnosis

- Asthma ± mucus plugging may give similar clinical and radiological features.

## Management

- If the child is coughing they should be encouraged to continue.
- Do not intervene unless the child's cough becomes ineffective (quieter) or the child is losing consciousness. A spontaneous cough is more effective than assisting manoeuvres.
- Choking child procedure involves back blows, chest thrusts (same landmarks as for cardiac compression) and abdominal thrusts (omit in infants) repeated as a cycle.
- If the choking child procedure fails, the child may require laryngoscopy. Contact a senior anaesthetist and ENT surgeon urgently.



**Inhaled foreign body lodged in the left main bronchus.** There is hypertransradiance of the left hemithorax, with mild associated mediastinal shift to the left on inspiration. On expiration the right lung becomes smaller, with the abnormality in the left lung accentuated. This is due to air trapping within the left lung secondary to a 'ball valve' effect.

## Foreign body – swallowed

### Characteristics

- Swallowed foreign bodies tend to lodge at sites of anatomical narrowing. These are at the level of cricopharyngeus, at the levels of the aortic arch and left main stem bronchus, and at the gastro-oesophageal junction.
- In children, cricopharyngeus is the most likely site of impaction. Once past this level, objects tend to pass through without hindrance. Impaction distal to this level should raise the possibility of pathological narrowing such as a stricture.
- In adults foreign body ingestion is deliberate (self-harm), accidental (fish or chicken bones) or as the result of a diminished gag reflex.
- Complications result from the direct trauma caused by the foreign body, secondary pressure necrosis or during its removal.

### Clinical features

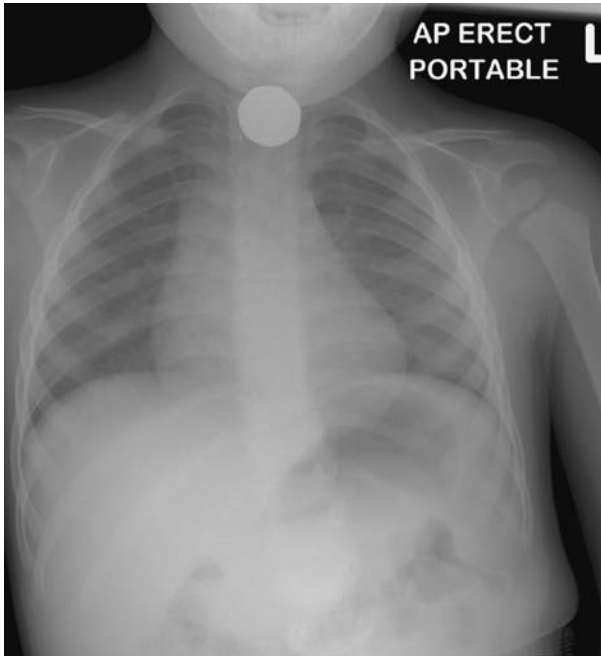
- Sensation of the presence of the foreign body.
- Features relating to complications, e.g. oesophageal perforation.

### Radiological features

- **CXR**
  - A **lateral cervical soft tissue** radiograph may reveal a radio-opaque foreign body.
  - Soft tissue swelling may be the only indicator of a radiolucent foreign body. Beware foreign bodies that have migrated through the mucosal wall and formed a parapharyngeal abscess.
  - A **water-soluble contrast swallow** may demonstrate an intraluminal foreign body or outline a complication.

### Differential diagnosis

- Patients may have swallowed a foreign body which has then passed through with minimal hold up. However, if the object was sharp or irregular it may have caused abrasions to the mucosal surface which may mimic a persistent ingested foreign body.



**Swallowed foreign body.**

## Management

- Visualisation, both direct and indirect, is useful and may allow removal of a visible foreign body.
- Refer patients who are symptomatic, and for whom an obvious cause cannot be seen and removed.
- Endoscopy allows definitive management.
- Beware of patients swallowing potentially dangerous items such as button batteries (e.g. watch batteries) and sharp objects such as razor blades!
- In a child, a chest radiograph should be performed to demonstrate the site of the object. An abdominal X-ray is required if the object is not seen within the chest to both confirm passage into the abdomen, and for transit monitoring if the object does not appear in the stool after 1 to 2 days.

# Goitre

## Characteristics

- A goitre represents enlargement of the thyroid gland in the neck. It can be diffuse, multinodular or simply relate to an enlarged solitary nodule.
- Symptoms may be due to local mass effect, from thyroid hormonal imbalance or rarely due to the presence of a focal malignancy within the thyroid.
- The enlarged thyroid may extend from the neck inferiorly into the superior mediastinum and retrosternal region.
- Goitres are the most common mediastinal mass.
- More common in females and in middle-aged/older people.

## Clinical features

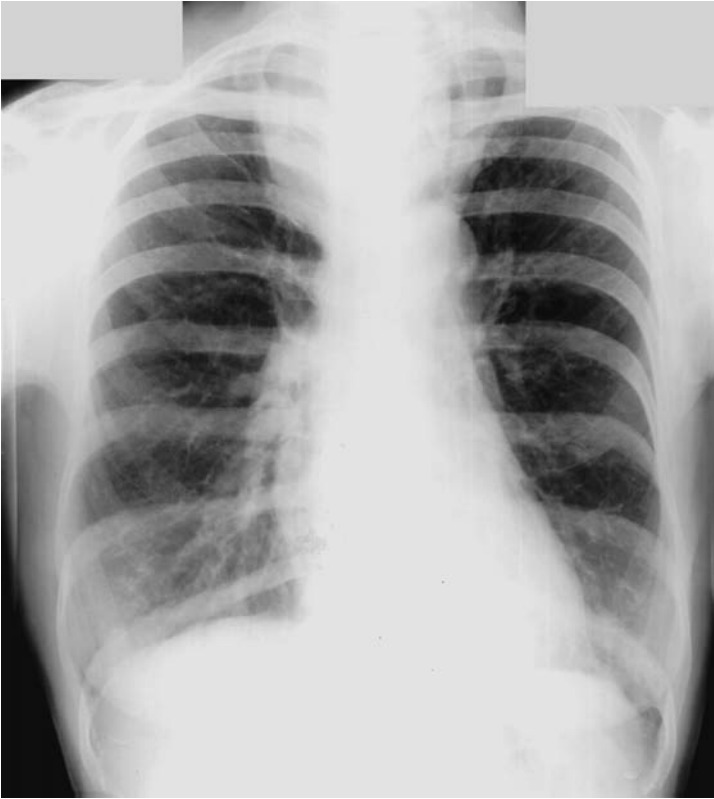- Most are asymptomatic, identified incidentally on a routine CXR.
- Symptoms may be due to local compression of the trachea or oesophagus. Occasionally recurrent laryngeal nerve palsies occur.
- Patients may be euthyroid, hyperthyroid or hypothyroid.
- Rarely a malignancy may coexist. Local pain and metastases can be a feature.

## Radiological features

- **CXR** – superior soft tissue mass, which may extend into the neck or retrosternally. There may be tracheal deviation away from the mass or tracheal compression. The mass may have a smooth or lobulated appearance and contain foci of calcification.
- **CT** – the mass is usually of high attenuation, contains calcification and enhances avidly.

## Differential diagnosis

- **4 Ts**
  - **T**hymus or **T**hymoma.
  - **T**erm cell tumour (e.g. **T**eratoma).
  - **T**ymphoma (e.g. **T**-cell lymphoma).
- If clinical doubt persists then biopsy and tissue sampling may be necessary.



**Goitre.** Superior mediastinal mass extending into the neck, resulting in marked narrowing and displacement of the trachea to the left.

## Management

- Most require no active treatment.
- If symptomatic patients should be considered for surgical resection (partial or complete thyroidectomy).
- Thyroid replacement hormone may be needed following surgery.



# Haemothorax

## Characteristics

- Accumulation of blood within the pleural space following blunt or penetrating trauma.
- Commonly associated with a pneumothorax and other extra-thoracic injuries.
- Haemorrhage usually occurs from the lung parenchyma, and is often self limiting, rather than from a specific vessel injury. Intercostal and internal mammary vessels are more commonly injured than the hilar or great vessels.

## Clinical features

- Depends mainly on the amount of blood lost.
- Varying degrees of hypovolaemic shock.
- Breath sounds may be reduced or absent with dull percussion.

## Radiological features

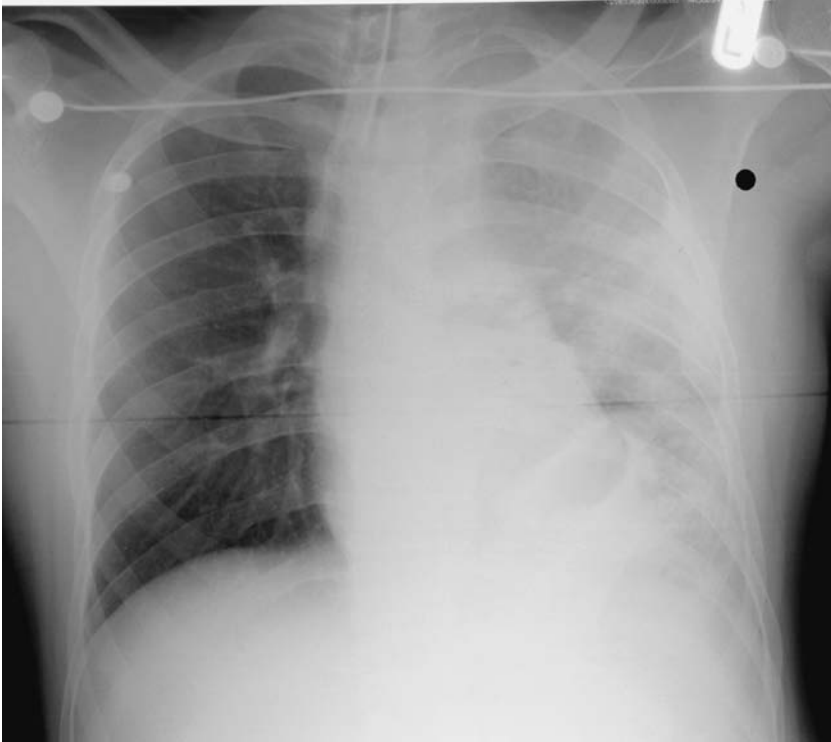- Erect **CXR** is more sensitive than a supine film.
  - Blunting of the costophrenic angles – seen with approximately 250 ml of blood.
  - General increased opacification of the hemithorax is seen on a supine film.

## Differential diagnosis

- Long-standing or acute pleural effusions (e.g. heart failure) may mimic a haemothorax. Review of old films and the clinical history is helpful. A pleural tap is diagnostic.

## Management

- ABC with IV access prior to tube thoracostomy.
- Definitive management involves the placement of a large-bore tube thoracostomy. This allows both re-expansion of lung as well as estimation of initial and ongoing blood loss. Airway control and circulatory volume support are essential alongside definitive treatment. A patient with initial drainage of 1500 ml or greater than 200 ml/h is likely to require thoracotomy. Discuss with thoracic team and be guided by the patient's physiological status.



**Haemothorax.** Traumatic aortic rupture and multiple rib fractures. Generalised increase in density of the left hemithorax secondary to haemorrhage.

# Heart failure

## Characteristics

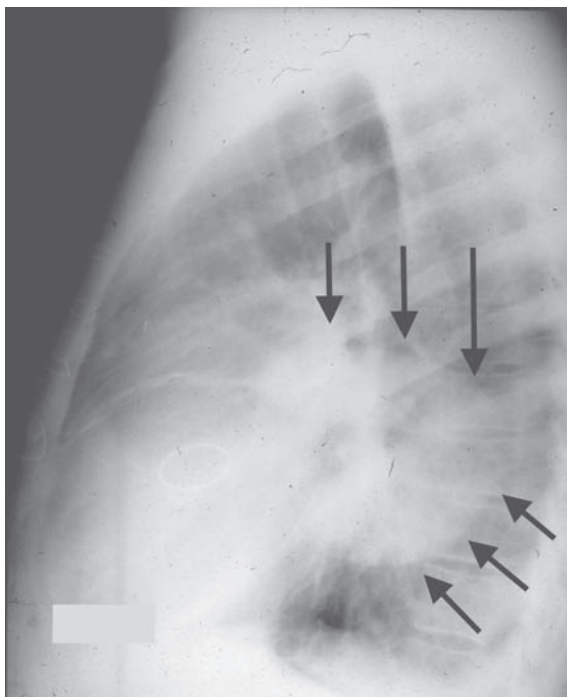
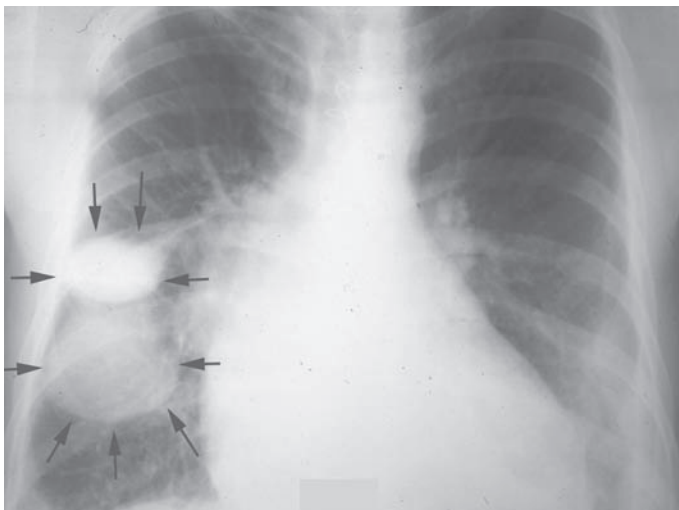
- This occurs when the heart fails to maintain sufficient circulation to provide adequate tissue oxygenation in the presence of normal filling pressures.
- There are many causes – ischaemic heart disease, hypertension, valvular heart disease, cardiomyopathy, congenital heart disease, cardiac tumours, chronic lung disease and negatively inotropic drugs.
- Different parts of the heart are affected depending on the pathology. In particular, the failing heart is sometimes clinically subdivided into right heart failure and left heart failure. In practice heart failure is more complicated with systolic and diastolic dysfunction affecting both sides of the heart. It is often referred to as congestive cardiac failure because the failing pump leads to the accumulation of fluid in the lung and soft tissues of the body.

## Clinical features

- SOB, fatigue, cough and wheeze.
- Orthopnoea, paroxysmal nocturnal dyspnoea.
- Cyanosis, arrhythmias, chest pain, syncope.
- Hypertension or history of angina or myocardial infarction.
- May be no clinical findings.
- Oedema, hepatomegaly.
- Hypoxia.

## Radiological features

- **CXR**
  - **Right heart failure** (this is usually due to chronic airways disease).
  - Features in keeping with COPD.
  - There may be cardiomegaly, but often the heart size is normal with a prominent elevated apex due to right ventricular hypertrophy. Pulmonary arterial enlargement and venous upper lobe diversion in keeping with pulmonary arterial and venous hypertension. There may be pleural effusions with fluid tracking in the oblique and horizontal fissures. Beware these may look like mass lesions on the frontal radiograph.



**Right heart failure.** Well-defined masses seen with the right mid and lower zones. These 'pseudotumours' represent encysted pleural fluid within the horizontal and oblique fissures (arrows).

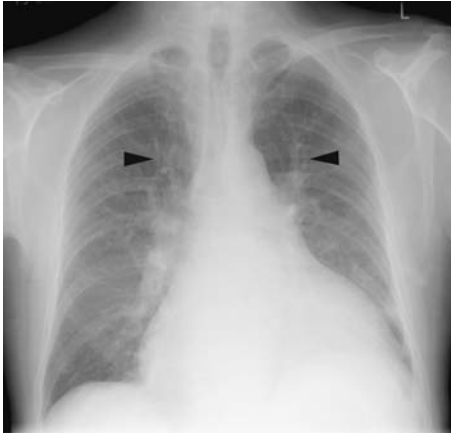- **Left heart failure**
- *Stage 1* – there is venous upper lobe blood diversion with thickened upper lobe veins bilaterally.
- *Stage 2* – interstitial pulmonary oedema – prominent peripheral interstitial thickening (Kerley B lines) bilaterally at both bases with apparent peribronchial thickening at both hila.
- *Stage 3* – alveolar (air space) pulmonary oedema – patchy bilateral perihilar air space consolidation giving a ‘Bat’s wing’ appearance. The consolidation may become confluent and extensive. Occasionally asymmetry may be misleading and can be due to the way in which the patient had been lying or the presence of concomitant chronic lung disease. There is venous upper lobe blood diversion with thickened upper lobe veins bilaterally.
- **Echocardiography** – the diagnosis and characterisation of heart failure are made with this modality. **CXR** is used to monitor and look for changes in acute deterioration.

## Differential diagnosis

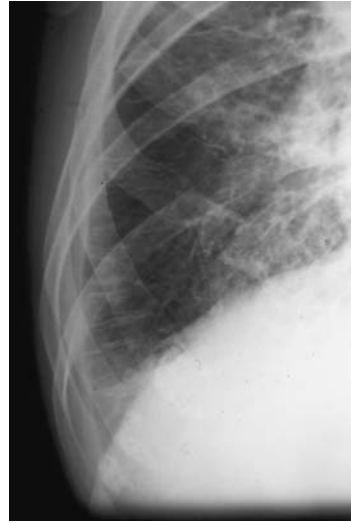- Non-cardiogenic pulmonary oedema. The air space oedema tends to be more peripheral with less upper lobe redistribution. Discrimination can be difficult.
  - Fluid overload.
  - ARDS.
  - NSAIDS.
  - Post intracranial disease.
  - Post drowning.
- Other conditions such as pulmonary haemorrhage, infection or granulomatous diseases may mimic the changes of pulmonary oedema.

## Management

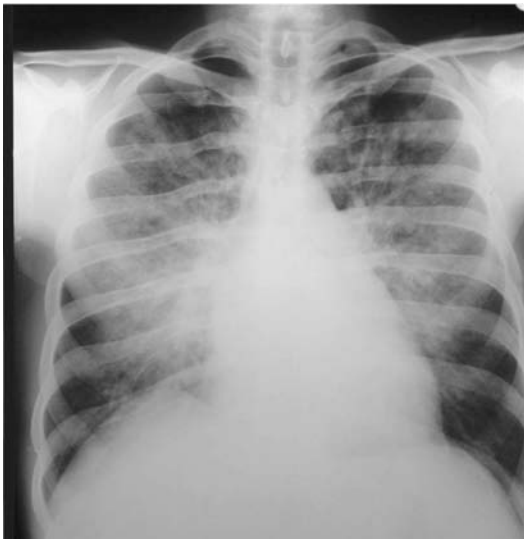- Oxygen.
- Diuretics and ACE inhibitors.
- Intravenous nitrates in acute episodes.
- Intravenous inotropes.
- BiPAP has shown some benefit in acute episodes.
- Treat the underlying cause.
- Pacemaker.
- Aortic balloon pump in severe cases to maintain cardiac output until a more permanent treatment/intervention can be commenced.



**Stage 1 left heart failure.** *Raised pulmonary venous pressure. Note the bilateral upper lobe blood diversion (arrowheads).*



**Stage 2 left heart failure.** *Interstitial pulmonary oedema. Prominent septal lines at the right costophrenic angle.*



**Stage 3 left heart failure.** *Pulmonary oedema. Bilateral perihilar ('bats wing') consolidation.*

# Hiatus hernia

## Characteristics

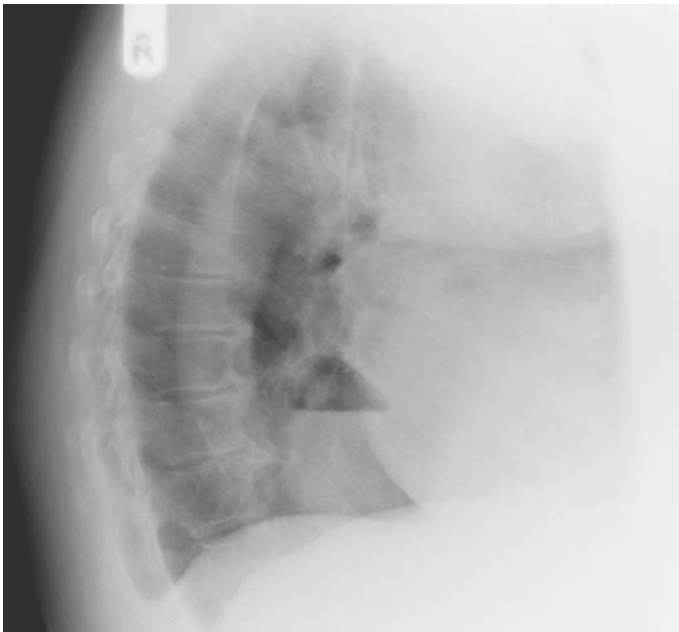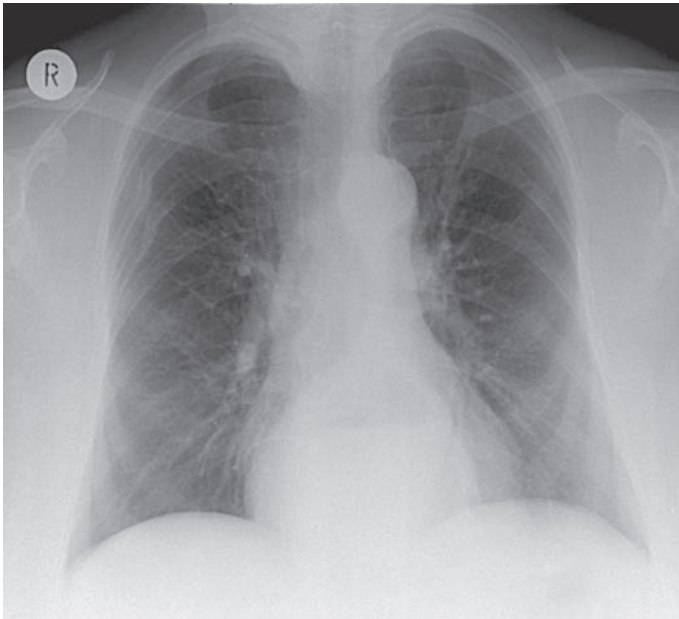
- Two types:
  - **Sliding** (99%) – there is dehiscence of the diaphragmatic crura with herniation of the gastro-oesophageal junction (GOJ) above the diaphragm. The hernia can be very large and is often reducible in an upright position. Increased incidence with age.
  - **Rolling/paraoesophageal** (1%) – the GOJ lies at the level of the diaphragm. A part of the stomach herniates through the oesophageal opening in the diaphragm adjacent to the normal GOJ. The hernia rarely reduces.
- Both hernias increase with age. There is association with reflux oesophagitis. Both hernias predispose the stomach to volvulus. The rolling hernias are at high risk of incarceration.

## Clinical features

- Often asymptomatic.
- Reflux indigestion. Food regurgitation. Coffee ground vomiting.
- Dysphagia.
- Epigastric or abdominal pain.

## Radiological features

- **CXR**
  - May be normal.
  - Retrocardiac well demarcated soft tissue density. May be an air-fluid level.
  - Lateral film demonstrates an inferior, middle mediastinal soft tissue density mass, often with an air-fluid level.
- **Barium swallow**
  - The B-ring of the oesophagus lies above the diaphragm in sliding hiatus hernias. There may be narrowing at the B-ring with dilatation and often gastric mucosal folds lying above the diaphragm. There may be tertiary contractions and irregular mucosa due to reflux oesophagitis in the distal oesophagus.
  - A part of the stomach lies adjacent to the GOJ above the diaphragm in rolling hernias.
  - Both hernias predispose the stomach to volvulus.



**Hiatus hernia.** There is a mass projected behind the heart in one of the 'hidden areas'. On the lateral view, an air-fluid level is seen confirming a hiatus hernia.

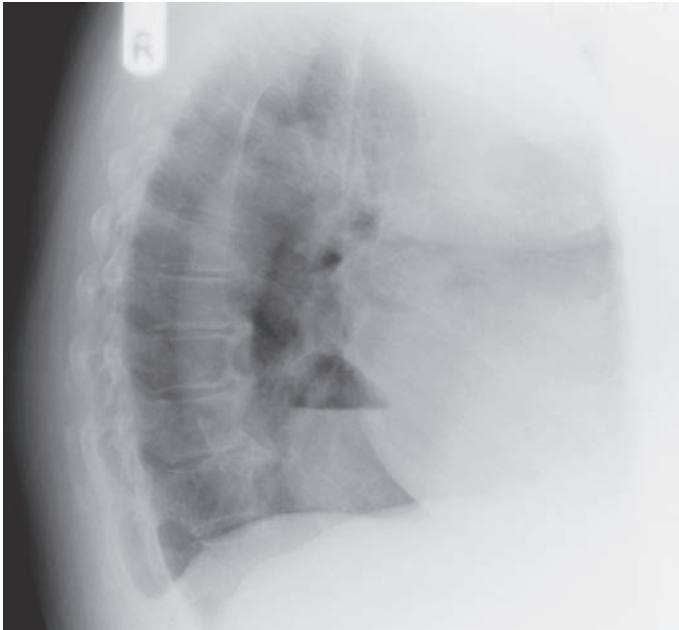
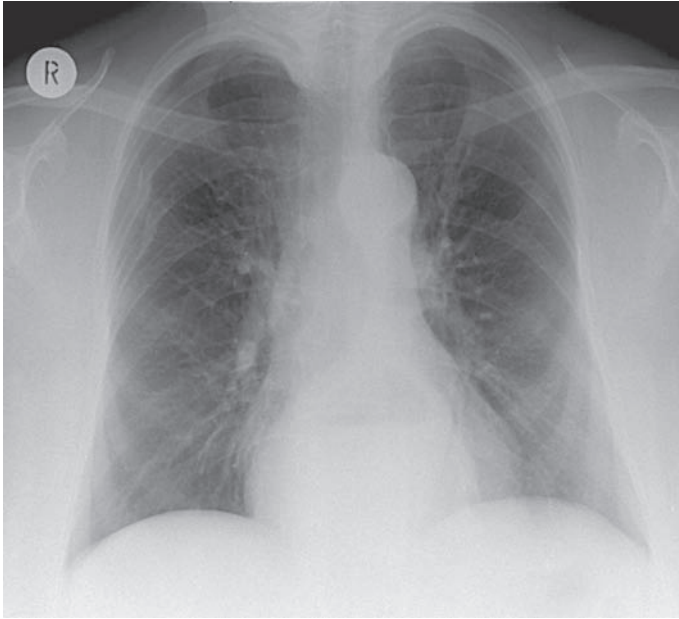


## Differential diagnosis

- The differential diagnosis of a retrocardiac density on CXR includes posterior/middle mediastinal lesions:
  - Neurogenic tumour
  - Primary lung tumour
  - Thoracic aneurysm
  - GOJ cancer
  - Lymphadenopathy.

## Management

- Often no treatment required.
- Long-term acid suppression with proton pump inhibitors.
- Surgical reduction of the hernia – Nissen fundoplication.



**Hiatus hernia.** There is a mass projected behind the heart in one of the 'hidden areas'. On the lateral view, an air-fluid level is seen confirming a hiatus hernia.

# Idiopathic pulmonary fibrosis

## Characteristics

- Progressive inflammation, fibrosis and destruction of the lung of unknown cause. Leads to an end-stage restrictive lung disease.
- Currently known as usual interstitial pneumonitis (UIP) formerly cryptogenic fibrosing alveolitis.
- Affects  $M > F$  and age 40–70 years.
- The commonest interstitial pneumonitis.
- Overlap with other interstitial pneumonitides, which are often secondary to a predisposing condition.
- Strong association with primary bronchogenic tumour.

## Clinical features

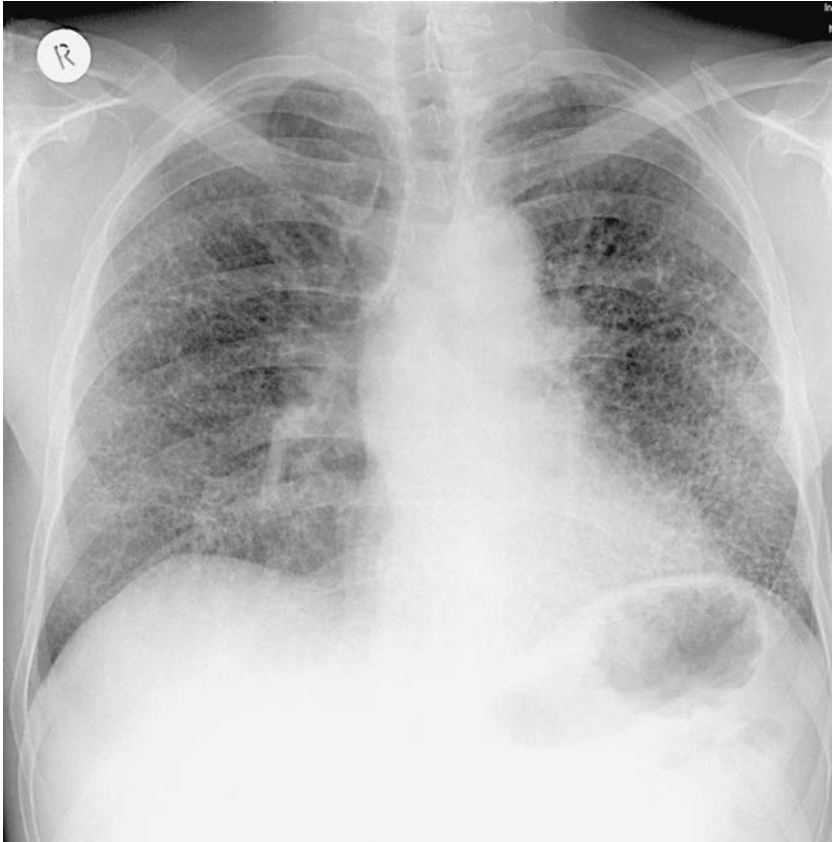
- Progressive dyspnoea.
- Non-productive cough.
- Weight loss.
- Clubbing.
- Bibasal lung crackles.
- Hypoxia.
- Restrictive changes on lung function tests.

## Radiological features

- **CXR** – peripheral bibasal distribution. Reticulation predominately subpleural. Progressive fibrosis leads to volume loss and honeycombing. There is parenchymal distortion with traction bronchiectasis. Consolidation from infection and rarely ground glass (<25%) may be present. Associated pulmonary arterial enlargement secondary to pulmonary arterial hypertension.
- ALWAYS LOOK FOR AN ASSOCIATED MASS LESION (TUMOUR).
- **HRCT** – approx 90% sensitive. Patchy irregular subpleural, peripheral bibasal reticulation. Honeycombing and bronchiectasis.

## Differential diagnosis

- Other forms of fibrosis or interstitial pneumonitis.
- Desquamative interstitial pneumonitis (DIP).
- Non-specific interstitial pneumonitis (NSIP).
- Respiratory bronchiolitis interstitial lung disease (RB-ILD).
- Lymphocytic interstitial pneumonitis (LIP).

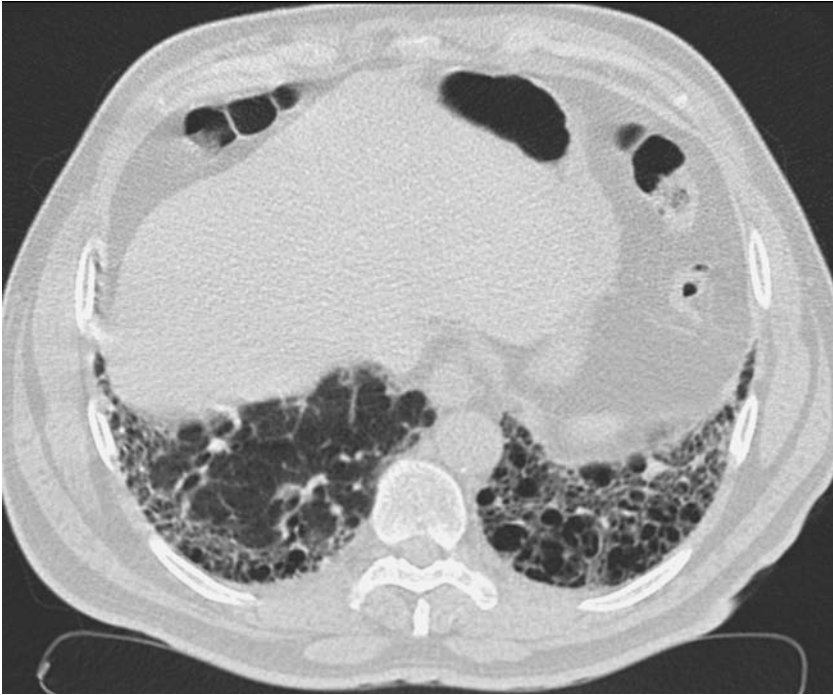

**Idiopathic pulmonary fibrosis.** Small volume lungs with extensive reticular shadowing and early 'honeycombs' in the lower zones.

- Drug-related interstitial pneumonitis.
- Collagen-vascular-disorder-related interstitial pneumonitis.
- They all have very similar imaging features, but subtle differences in HRCT appearance, clinical presentation and treatment response help in discriminating the different causes.

## Management

- A biopsy may be required to make a diagnosis.
- 15% respond to steroids.
- 5-year mortality is 90%.



**Idiopathic pulmonary fibrosis – HRCT.** Coarse reticular bibasal fibrosis resembling ‘honeycombing’.

# Incorrectly sited central venous line

## Characteristics

- There are two types of incorrectly positioned central lines.
  - The first is common and demonstrates the venous line lying in the appropriate structure but not the appropriate position, e.g. lines only just into the SVC or placed well within the right atrium. They predispose the line to complications such as venous thrombus or perforation.
  - The second type is rarer but potentially more hazardous from a line placed in an inappropriate vein/vessel or site. They include the tip lying in internal mammary, superior intercostal, subclavian or carotid arteries or alarmingly outside any vasculature structure and in the soft tissues.

## Clinical features

- May be asymptomatic.
- Poorly functioning catheter or pain on flushing.
- SOB secondary to a pneumothorax or pleural effusion/haemothorax.
- Localised erythema, pain or swelling at the cutaneous site of line insertion.

## Radiological features

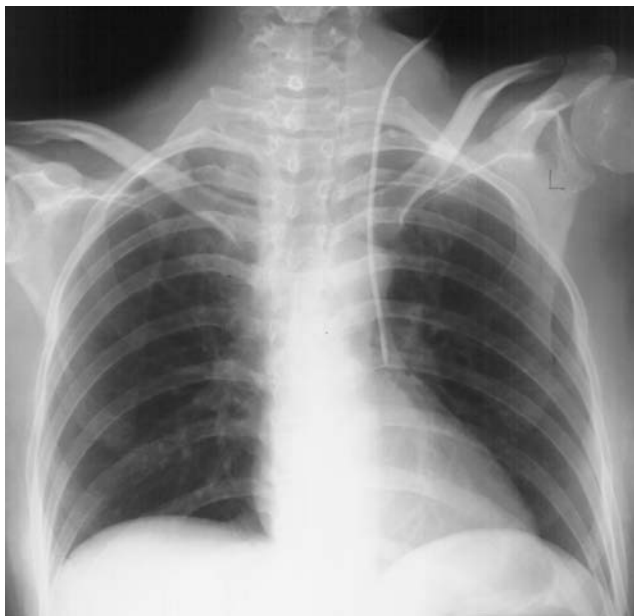
- **CXR** – central line appropriately sited but too proximal or distal to the ideal SVC position.
- The central line may lie in position anywhere within the neck or thorax. It may follow common vessels (arteries or veins).
  - Associated pneumothorax or haemothorax.
- **CT** – confirms position and may also demonstrate local thrombus associated with the line tip.

## Differential diagnosis

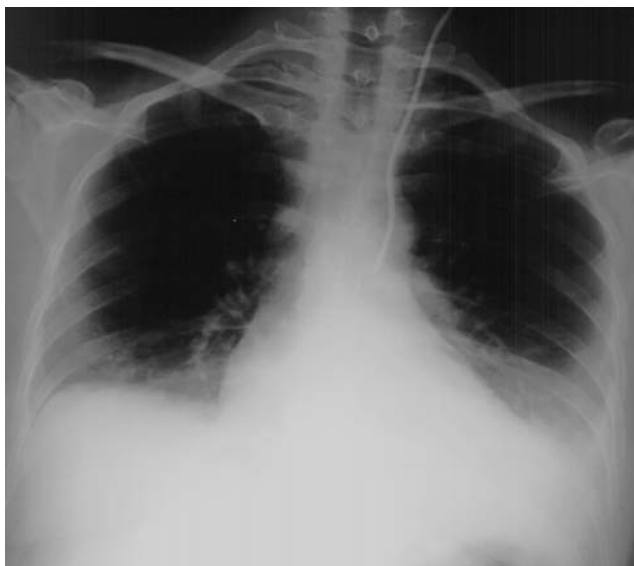- There are several common anatomical vascular variants. For example, double or left-sided SVC. Awareness of these is critical to understanding a truly incorrectly positioned line.

## Management

- Removal/re-siting of the line.
- US ± venography may be necessary to confirm anatomy, particularly if there are complications following multiple line insertions.
- A vascular surgeon may be needed for safe removal of inappropriately positioned venous lines within the arterial system.



**Incorrectly sited central venous line.** This left internal jugular central venous line is incorrectly placed. The tip is directed directly into the mediastinum.



This error was not identified. When IV fluids were started this accumulated in the left pleural space.



# Kartagener syndrome

## Characteristics

- Rare syndrome associated with cilia dysmotility.
- Affects respiratory, auditory and sperm cilia.
- Triad of features
  - Situs inversus (50%).
  - Nasal polyposis and chronic sinusitis.
  - Bronchiectasis.
- Associated with deafness, infertility and other congenital anomalies (e.g. cardiac).
- Familial predisposition.

## Clinical features

- Diagnosis in childhood. May be antenatal diagnosis.
- Dyspnoea, cough and sputum.
- Recurrent chest infections.

## Radiological features

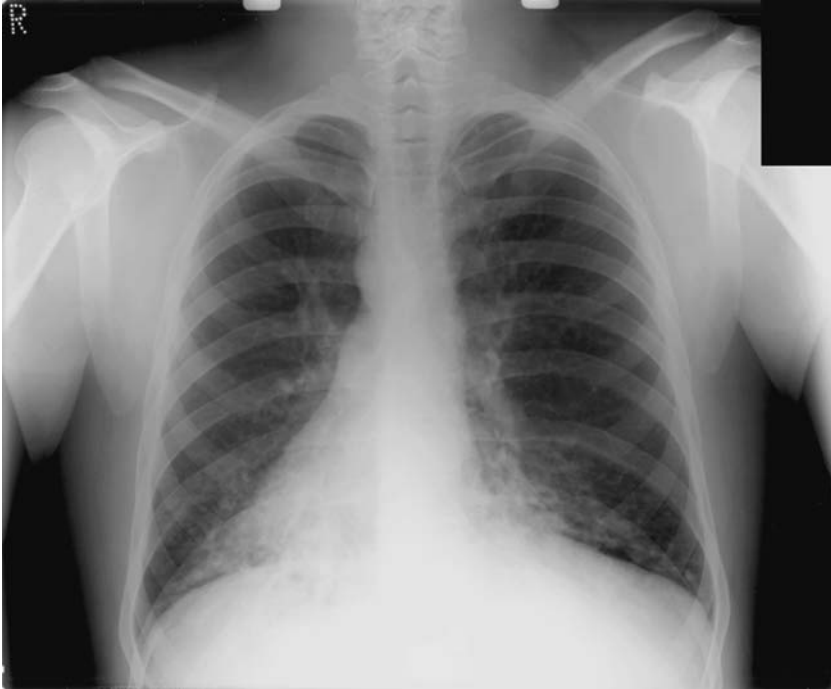- **CXR** – dextrocardia  $\pm$  situs inversus. Bibasal bronchiectasis. May be mucus plugging and lobar collapse or associated infective consolidation.
- **Facial X-ray** or **CT** – demonstrates extensive sinus soft tissue in keeping with polyps and mucus.

## Differential diagnosis

- Cystic fibrosis and asthma may have similar appearances particularly as 50% of Kartagener's cases have no dextrocardia.

## Management

- Chest physiotherapy.
- Long-term and/or recurrent antibiotic therapy.
- Consideration for heart-lung transplant.



**Kartagener syndrome.** Dextrocardia and left lower lobe bronchiectasis.

# Lymphangiomyomatosis

## Characteristics

- This is a rare disease of unknown cause characterised by the presence of abnormal smooth muscle proliferation of the pulmonary interstitium, particularly in the bronchioles, pulmonary vessels and lymphatics.
- Exclusively affects women of a child-bearing age.
- Associated with chylous ascites, fatty liver and renal angiomyolipomas.

## Clinical features

- Progressive exertional dyspnoea.
- Haemoptysis.
- Restrictive lung function and hypoxia.
- Increase in symptoms during pregnancy and on the oral contraceptive pill.

## Radiological features

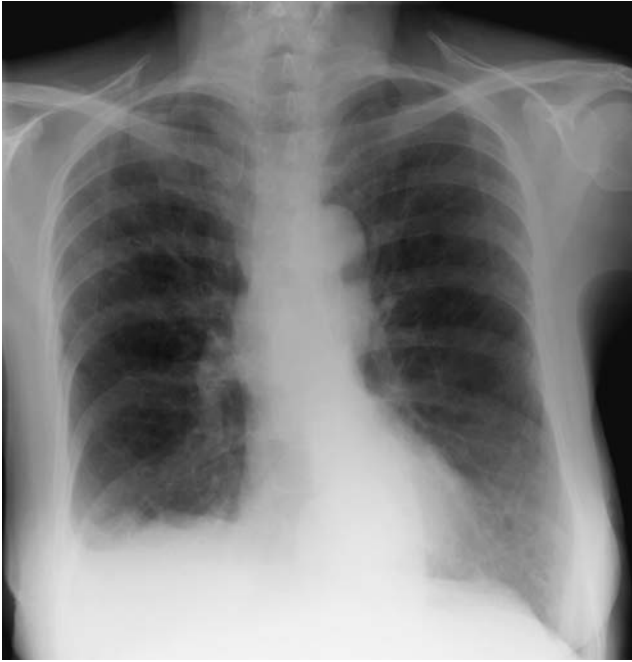- **CXR** – coarse reticular interstitial pattern with cyst formation on the background of large volume lungs. There is a common association with chylous pleural effusions (70%), pneumothoraces (40%) and mediastinal lymphadenopathy.
- **HRCT** – numerous random thin-walled cysts of varying size and relatively regular shape. Bronchovascular bundles at edge of cyst. Lymphadenopathy, pleural effusions and pneumothoraces. Dilated thoracic duct.
- Long-standing cases may develop pulmonary arterial hypertension with enlargement of the central pulmonary arteries.

## Differential diagnosis

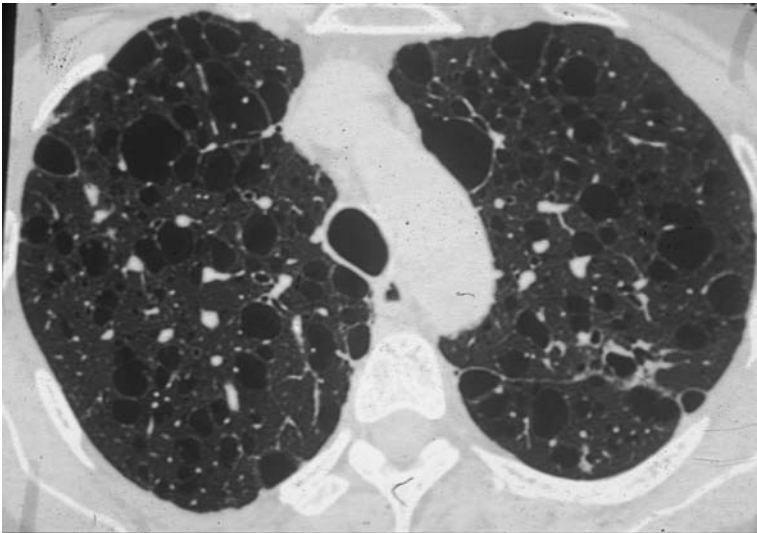
- Langerhan's cell histiocytosis – male smokers, with upper zone predisposition and more cyst irregularity.
- Tuberos sclerosis – rare. Other characteristic abnormalities present.
- Emphysema – smokers. No wall to the emphysematous bullae.
- Neurofibromatosis – rare with musculoskeletal and neurogenic abnormalities.
- Lung fibrosis (e.g. UIP). Basal fibrosis and honeycombing.

## Management

- Lung biopsy may be required to confirm the diagnosis.
- No specific treatment.
- 10-year survival is 75%.
- Progression to pulmonary insufficiency and arterial hypertension.



**Lymphangioleiomyomatosis.** Large volume lungs with cystic air spaces in the left lower zone.



**Lymphangioleiomyomatosis – HRCT.** Multiple cystic air spaces within both lungs.

# Lymphoma

## Characteristics

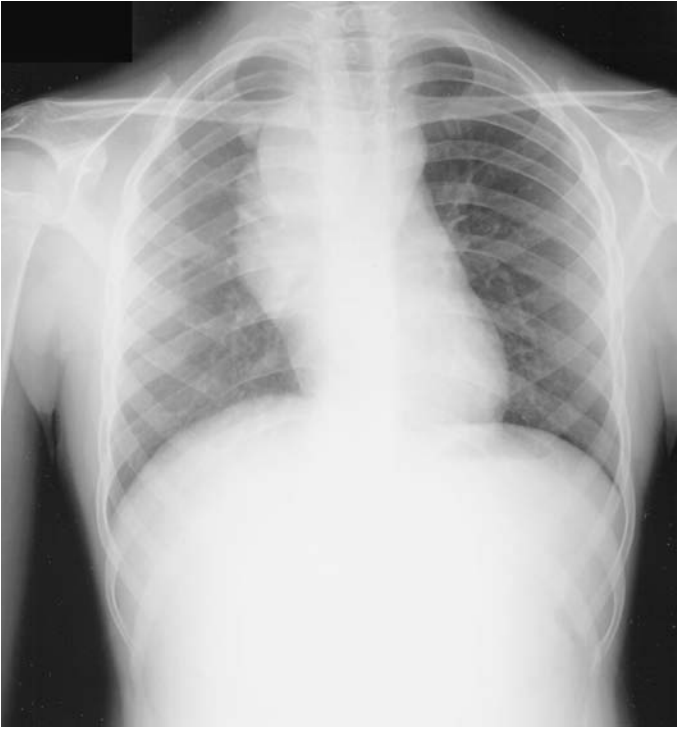- Lymphoma represents a specific group of neoplasms of the lymphoproliferative system.
- They are broadly subdivided into Hodgkin's disease (HD) and non-Hodgkin's lymphoma (NHL) based on the presence of Reed–Sternberg cells (HD). NHL represents a spectrum of abnormal lymphoid tissue affecting a variety of different tissues and organs.
- Most develop de nova, but others occur following radiotherapy and NHL is associated with various immunosuppressed states (e.g. post transplantation).
- They occur at any age with peaks occurring in adolescence and late/middle age.
- They can run a variable course with some, particularly HD, demonstrating complete recovery and others showing frequent relapse.

## Clinical features

- May be asymptomatic.
- Palpable cervical or abdominal lymphadenopathy.
- Sweats. Swinging pyrexia.
- Weight loss, anorexia, malaise.
- Dyspnoea.
- Stridor.
- Dysphagia.
- Some of the symptoms may relate to posture with difficulty breathing seen on lying flat.

## Radiological features

- **CXR** – mediastinal and hilar soft tissue mass in keeping with lymphadenopathy. This may be extensive. Lymphadenopathy may extend confluent into the neck or abdomen. Splenic enlargement may be demonstrated by increased soft tissue density under the left hemidiaphragm.
  - Rarely primary lung lymphoma may be present. This manifests as diffuse air space opacification, or occasionally parenchymal nodular disease.
- **CT** – confirms the extent of the intra-thoracic lymphadenopathy and allows full staging of the chest, abdomen and pelvis. HD spreads confluent. Staging is based on the extent of disease above and



**Lymphoma.** Hilar, paratracheal and axillary lymphadenopathy.

below the diaphragm and liver/splenic and other organ involvement. Calcified lymph nodes are present following treatment.

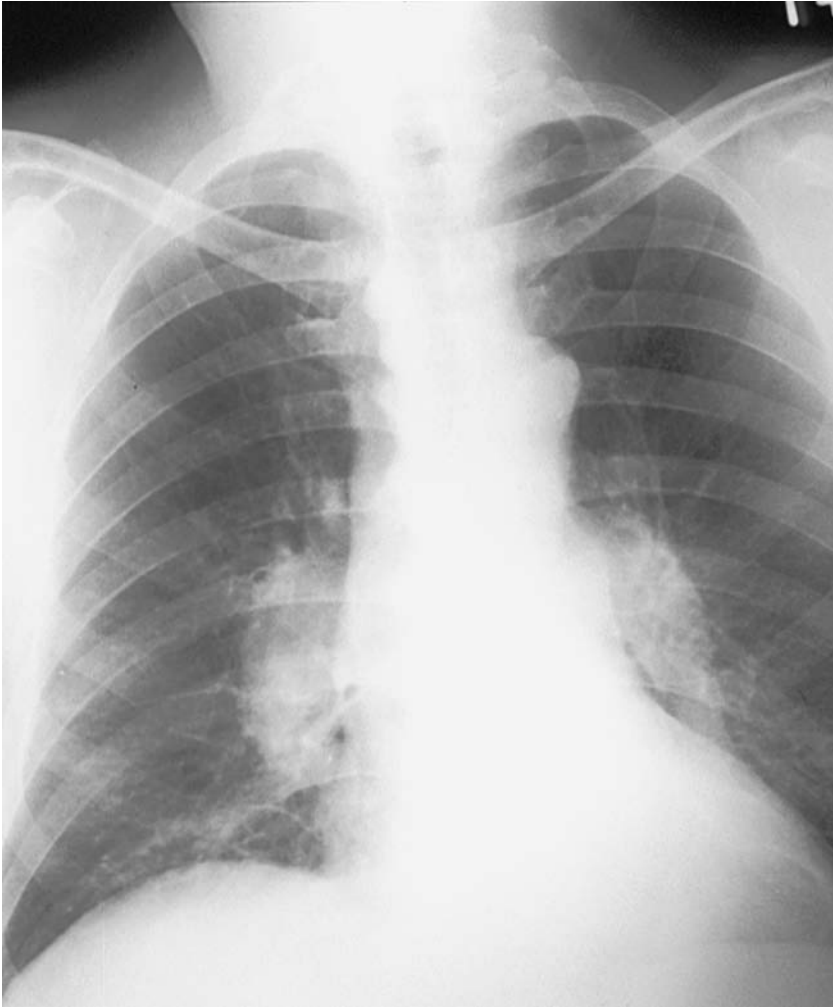- **PET/CT** – following treatment residual soft tissue is often present in the anterior mediastinum. This may or may not represent residual active disease. Increased uptake within the tissue represents active disease.

## Differential diagnosis

- Sarcoid.
- TB.
- Anterior mediastinal mass: thyroid, thymus/thymoma, teratoma.

## Management

- Biopsy is essential to confirm the presence and type of lymphoma.
- Treatment is tailored to the type of lymphoma.
- Steroids.
- Chemoradiotherapy.



**Lymphoma.** Bilateral hilar adenopathy.





# Macleod's syndrome

## Characteristics

- Also known as Swyer–James syndrome or unilateral lobar emphysema.
- Follows an acute viral infective bronchiolitis (e.g. adenovirus or measles) to the developing lung during childhood (<8 years old). The children then develop a post infective form of obliterative bronchiolitis with bronchiectasis and distal airspace destruction.
- Usually affects the whole of one lung, but can affect both lungs and very occasionally has been shown to affect lobar or segmental parts of the lung.

## Clinical features

- Often asymptomatic.
- Cough, SOB, wheeze.
- History of recurrent childhood infections.
- Presentation usually in adulthood.

## Radiological features

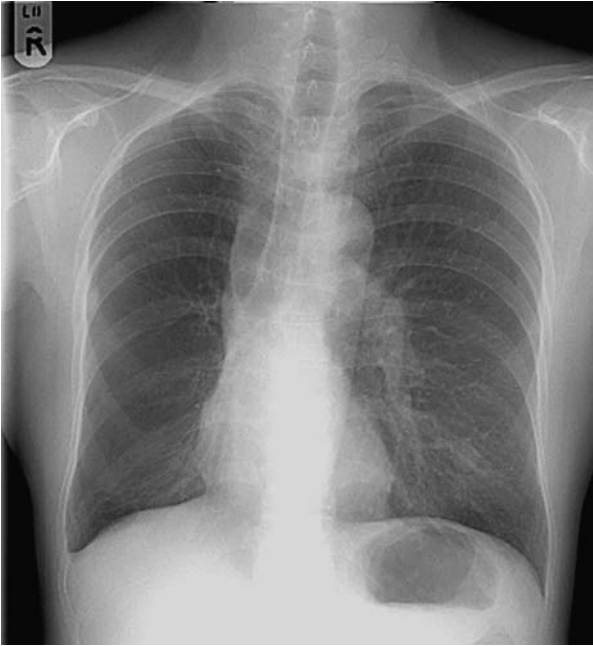
- **CXR** – there is typically increased transradiancy throughout one lung. Reduced volume in affected lung. May be mediastinal shift towards the affected side. Air trapping in expiration. Reduced pulmonary vasculature in low attenuation areas on the affected side.
- **HRCT** – often bilateral mosaic pattern of reduced attenuation and air trapping demonstrated. Again reduced pulmonary vasculature in low attenuation areas. Bronchiectasis may be present.
- Partial involvement of only one lobe or lung is difficult to diagnose.

## Differential diagnosis

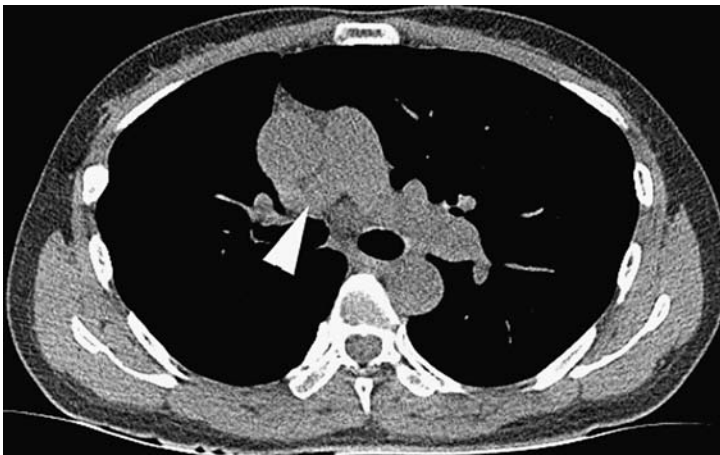- Hypogenetic lung syndrome (this is associated with proximal interruption of the pulmonary artery).
- Pulmonary artery hypoplasia.
- Thromboembolic disease (seen more in adults).
- Localised bullous emphysema (seen more in adults).
- Bronchial obstruction.

## Management

- No active management in most patients.
- Physiotherapy and long-term antibiotic requirement may be necessary.



**Macleod's syndrome.** The left hilum and left pulmonary vascular tree appear normal. The right hilum is very small and the entire right hemithorax has a paucity of lung markings. Additional volume loss within the right lung. The right lung appears otherwise normal (i.e. it is not hypoplastic).



CT confirms a small right pulmonary artery (arrow) and additional volume loss within the right hemithorax.

# Mastectomy

## Characteristics

- Removal of the breast tissue in the treatment of breast cancer.
- Common form of treatment.
- It may be partial, or total, with additional removal of soft tissues from the chest wall and/or axilla.
- Reconstructive surgery or breast augmentation surgery with prostheses may be present.
- Patients receiving mastectomies often get adjuvant radiotherapy to the ipsilateral chest wall.

## Clinical features

- Post mastectomy, the majority of patients are asymptomatic.
- Some patients may complain of chest wall discomfort.
- Clinicians should be alerted to the onset of new chest wall pain or chest symptoms (SOB, cough) as this may herald recurrent disease.

## Radiological features

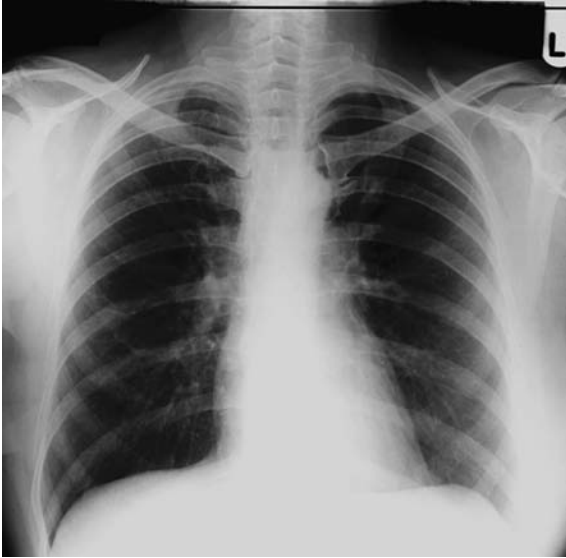
- **CXR**
  - Total mastectomy: there is increased transradiancy throughout the ipsilateral hemithorax. The axillary soft tissues may be reduced in thickness.
  - Partial mastectomy: may show breast shadow distortion or asymmetry of the breast shadows only.
  - Always look for changes consistent with radiotherapy in the bones (radionecrosis) which may mimic bone metastases.
  - There may be associated lung, pleural or bone metastases.

## Differential diagnosis

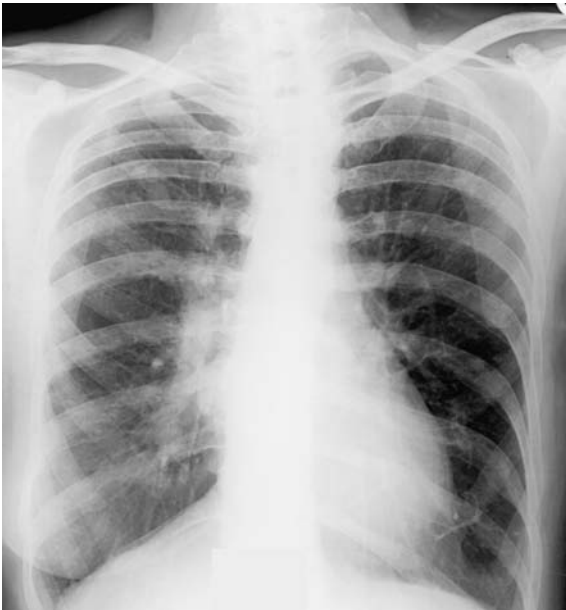- Poland's syndrome – congenital absence of pectoralis major.

## Management

- No treatment required.



**Right mastectomy.**



**Left mastectomy.** The outline of the right breast is visible whilst the left is absent. In addition, the left hemithorax is hyper-transradiant as compared to the right.

# Mesothelioma

## Characteristics

- Benign and malignant forms.
- Most common malignant tumour of the pleura.
- Multiple tumour masses involving predominately the parietal pleura encasing the lung with a thick sheet-like tumour.
- Strong association with asbestos exposure. Also linked with chronic inflammation and irradiation.
- Can spread to the peritoneal pleura.
- Spread can be haematogenous or via the lymphatic route to lymph nodes, lung and liver.
- Presentation >50 years. M > F.

## Clinical features

- Chest pain.
- Dyspnoea.
- Fever and sweats.
- Weakness and malaise.
- Cough.
- Weight loss.

## Radiological features

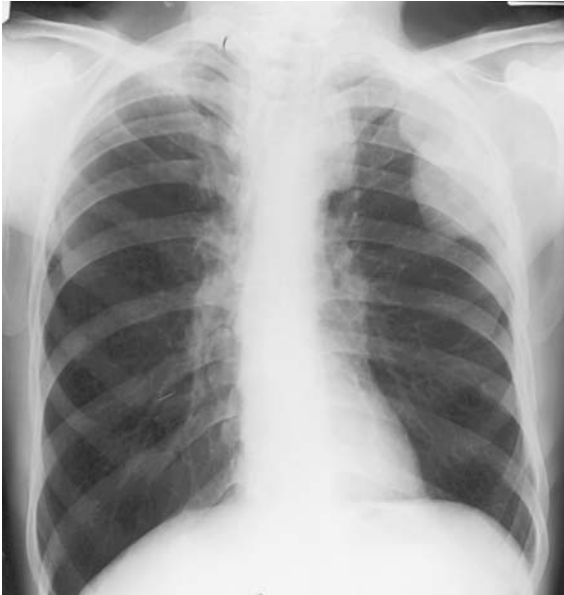- **CXR** – extensive lobulated pleural masses often extending over the mediastinal pleural surface. Volume loss in the lung. Associated pleural effusion. Pleural calcifications (25%). Extension into the interlobular fissures and rib destruction in 20%.
- **CT** – enhancing lobulated pleural thickening (>1 cm) encasing the lung. Extends over mediastinal surface. Associated lung nodules. Rib destruction and extrathoracic extension. Ascites is demonstrated in 30%.

## Differential diagnosis

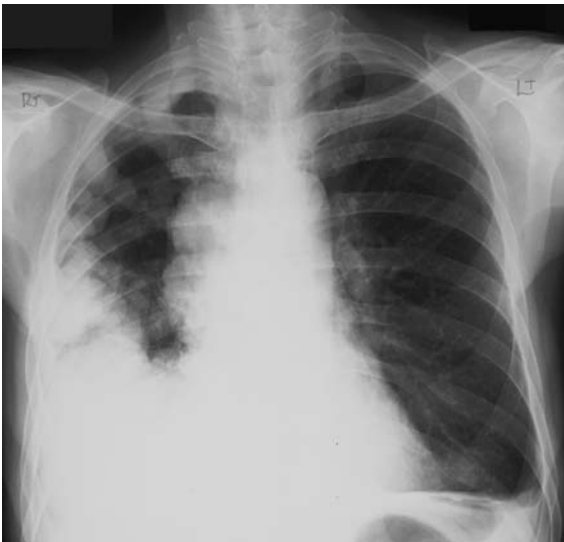- Post infective pleural fibrosis.
- Post empyema.
- Pleural metastatic disease.

## Management

- Confirm diagnosis with biopsy. Give radiation to biopsy site as tumour seeding occurs in 30%.



**Mesothelioma.** Lobulated pleural masses in the left upper zone.



**Mesothelioma.** In this case, there are more extensive lobulated pleural masses encasing the right lung.

- Palliative symptom treatment with pain relief, radiotherapy and trial chemotherapy.
- Mean survival is poor <1 year.

# Metastases

## Characteristics

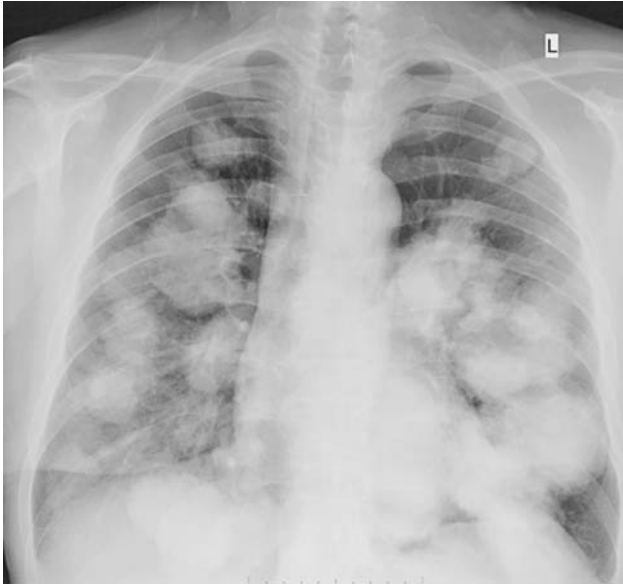- Metastatic disease within the chest represents spread to the lung, pleura, bones and soft tissues.
- Lung metastases are common, occurring in 30% of all malignancies.
- Metastatic spread to the lung is via the haematogenous or lymphatic route.
- Common cancers include breast, kidney, colorectal and prostate.
- Lung metastases are prominent in rarer malignancies such as osteosarcoma, thyroid cancer and melanoma.
- Can present as a solitary lung nodule (60% chance of malignant lesion), multiple lung nodules, diffuse air space opacification or diffuse reticulonodular change (lymphangitis carcinomatosa).

## Clinical features

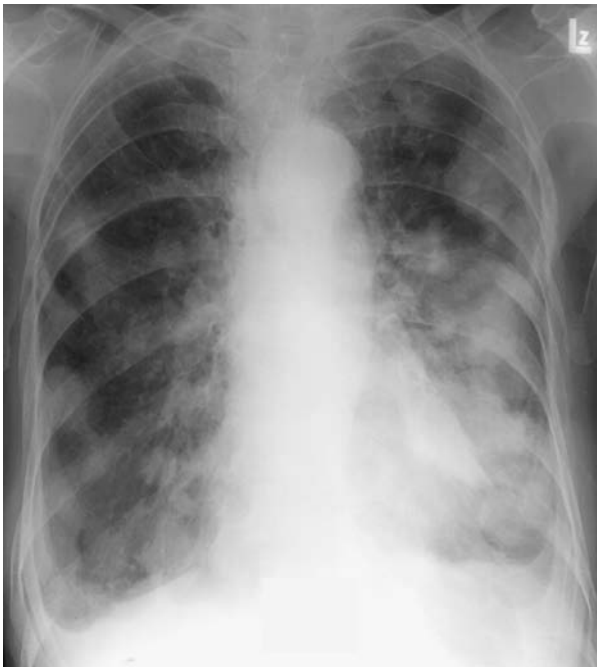- May be asymptomatic.
- Cough, sputum and haemoptysis.
- Dyspnoea.
- Weight loss, anorexia, malaise.
- Fever.
- Chest pains.
- This may be the first presentation of an occult primary malignancy.

## Radiological features

- **CXR** – solitary or multiple rounded lung lesions.
  - They may be calcified (osteosarcoma, breast, thyroid and mucinous adenocarcinoma).
  - They may be small (thyroid, breast, prostate, choriocarcinoma).
  - Cavitating (squamous cell, colon, melanoma, transitional cell carcinoma).
  - Haemorrhagic (choriocarcinoma, melanoma, thyroid).
  - Endobronchial (lung, lymphoma, breast, renal or colorectal carcinoma).
  - Air space opacification (adenocarcinoma of the breast, ovary or GI tract).
  - Lymphadenopathy may be present.
  - Septal lines, irregular fissural nodularity – lymphangitis (breast, colon, pancreas and stomach).



**'Cannon ball' metastases.**



**Multiple parenchymal metastases. Further example.**



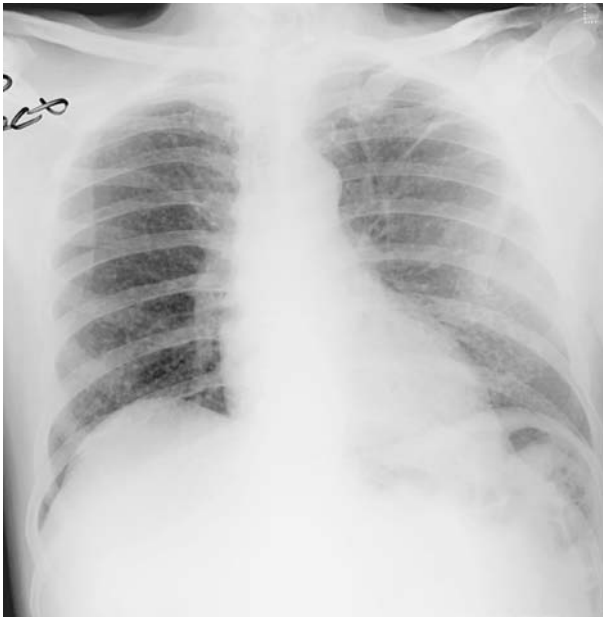- **CT** – may demonstrate the multiplicity of the lesions, lymphadenopathy and importantly the characteristic beaded interlobular septal thickening from lymphangitis.

## Differential diagnosis

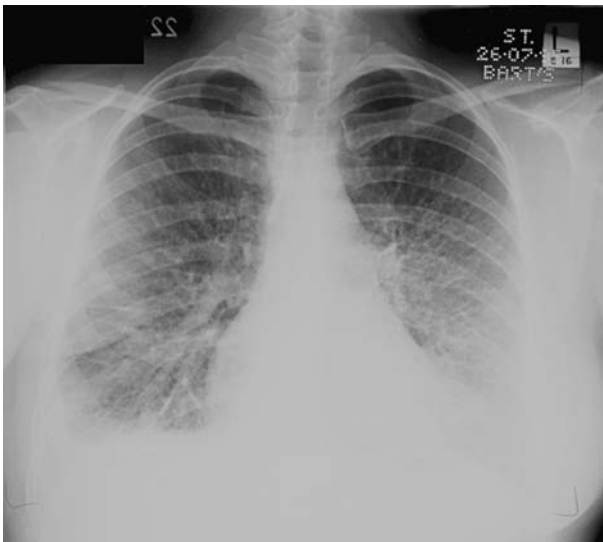- Benign neoplasms (hamartoma or adenoma).
- Granulomatous disease (rheumatoid arthritis or Wegener's granulomatosis).
- Septic emboli.
- Cryptogenic organising pneumonia.
- Pulmonary arteriovenous malformations.
- Multifocal infection.
- A biopsy may be required to confirm the diagnosis.

## Management

- Search for primary malignancy.
- May require tissue sampling.
- Full staging.
- Consider therapeutic or palliative chemoradiotherapy.



**Miliary metastases.**



**Lymphangitis carcinomatosa.** Previous right mastectomy, with extensive reticular shadowing in the right lower zone.

# Neuroenteric cyst

## Characteristics

- This is the rarest form of bronchopulmonary foregut malformation.
- It represents an incomplete congenital separation of the foregut from the notochord. There is a midline defect through the spine where the meninges communicate with the cyst.
- Rarely there is also a direct communication with the oesophagus.
- The cyst wall contains both gastrointestinal and neural elements.
- They are associated with neurofibromatosis and spinal dysraphism.
- Often present in childhood.

## Clinical features

- May be asymptomatic.
- Presentation common in childhood with chest pains.
- Dyspnoea and or dysphagia.
- Recurrent chest infections.
- May be associated neurological abnormalities.
- Incidental finding on CXR or spinal imaging.

## Radiological features

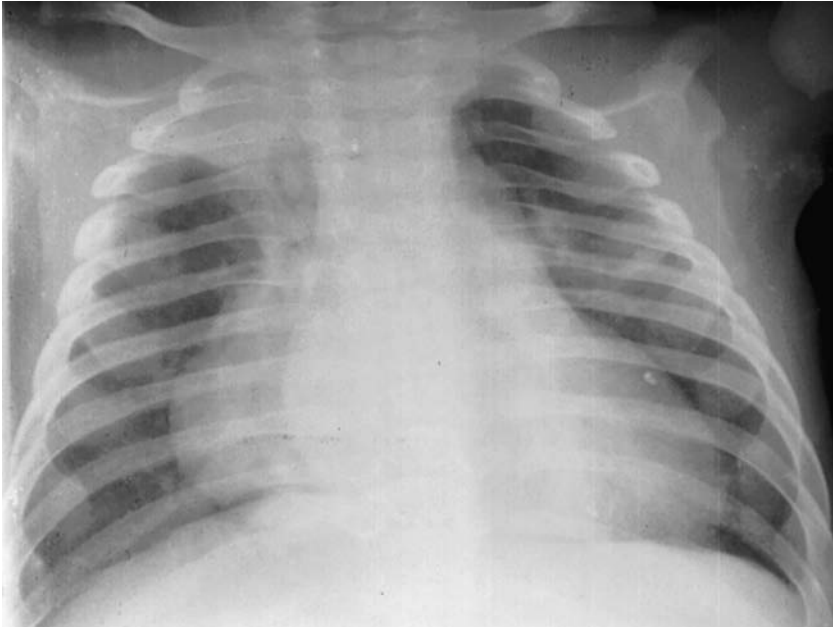
- **CXR** – posterior mediastinal midline soft tissue mass. There may be an air-fluid level. The mass may be large with smooth and sometimes lobulated margins. A midline spinal defect may be visible.
- **CT** – demonstrates the thin-walled posterior mediastinal cystic structure and its relationship with the spine  $\pm$  oesophagus.
- **MRI** – this is excellent for characterising the vertebral, spinal cord and meningeal abnormalities involved with the cyst.

## Differential diagnosis

- Thoracic meningocele.
- Neurogenic tumour.
- Lung abscess, especially TB abscess.
- Bronchogenic cyst.
- Primary lung tumour.

## Management

- If very small they can be left alone.
- Larger cysts are surgically excised. Caution is required when spinal canal and cord are involved with the cyst.



**Neuroenteric cyst.** Right paravertebral mass.

# Neurofibromatosis

## Characteristics

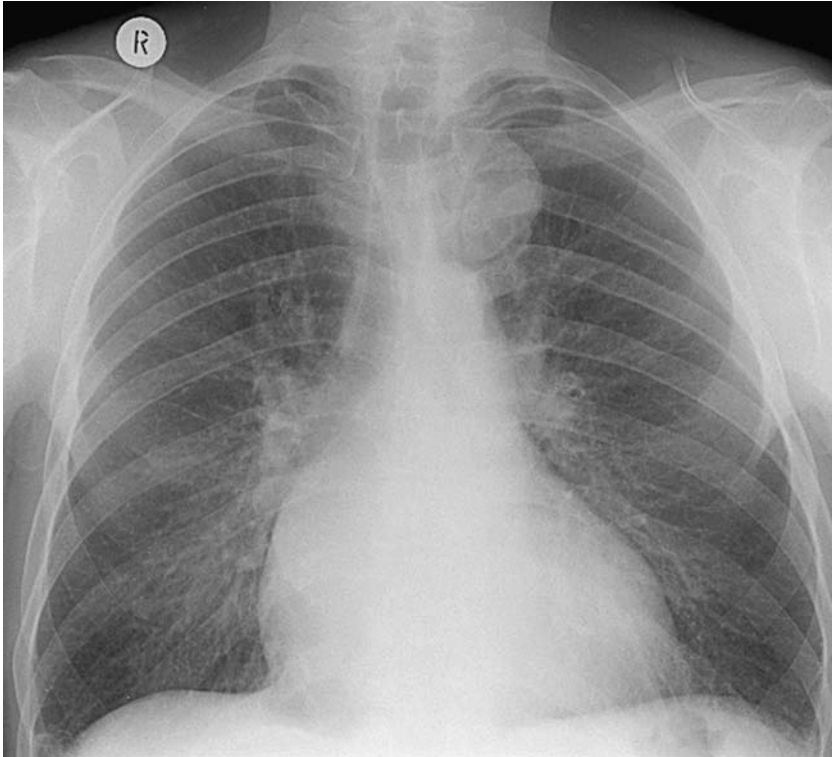
- Autosomal dominant inherited phakomatosis.
- Multi-organ involvement with propensity to develop neurogenic tumours, demonstrating proliferation of fibroblasts and Schwann cells on histology.
- Affects the central and peripheral nervous systems, spine, eyes, skin, skeletal system, thorax, kidneys and GI tract.
- Two types: NF1 (chromosome 17 – is most common) and NF2 (chromosome 21).
- 50% spontaneous mutations.
- Classical triad of cutaneous lesions, skeletal deformity and neurogenic tumours. Plexiform neurofibromas are characteristic for NF1.
- Patients present in early adulthood.

## Clinical features

- May be asymptomatic with incidental finding on routine CXR.
- Other patients have an established diagnosis of neurofibromatosis, with prominent neurological signs and symptoms.
- Patients may have ‘café-au-lait’ spots and cutaneous neuromas.
- Clinical chest features include: scoliosis, dyspnoea, chest pains. Occasionally arm, hand or leg weakness/pain may represent neurological impingement on nerves within the spine or peripheral plexus.

## Radiological features

- **CXR**
  - Scoliosis with rib irregularity (ribbon ribs).
  - Soft tissue masses may be present in the lung periphery representing intercostal neurofibromas.
  - Posterior mediastinal mass, abutting the spine.
    - The soft tissue lesion could represent a neurogenic tumour or a lateral meningocele, both present in neurofibromatosis.
    - The mass is well defined with a round or lobulated lateral margin. There is expansion of the vertebral exit foramen and scalloping of the ribs and vertebral bodies. Small flecks of calcium may be present in the mass.
  - Very rarely diffuse reticulo-cystic lung changes are present resembling chronic obstructive pulmonary disease.



**Neurofibromatosis.** Large left superior mediastinal mass which can be placed within the posterior mediastinum:

- the left brachiocephalic vein is visible within the anterior mediastinum
- the left wall of the trachea is visible in the middle mediastinum.

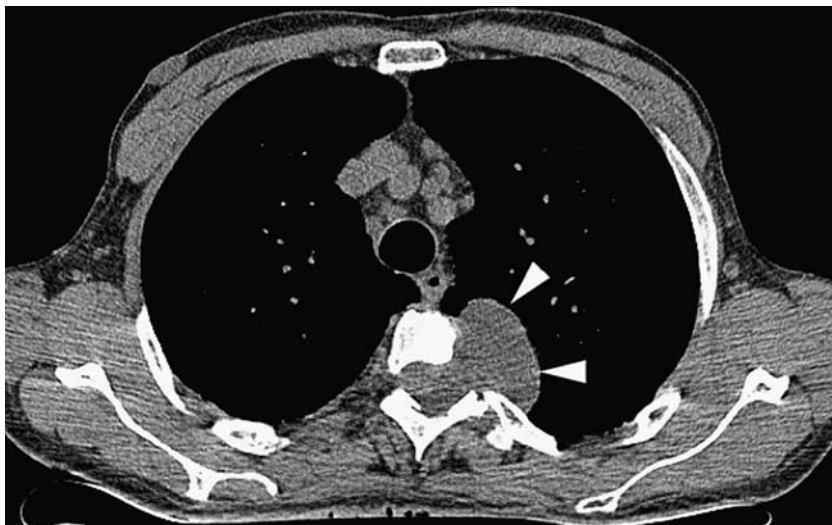- **MRI** – confirms the paravertebral soft tissue mass and demonstrates the intraspinal component giving rise to a ‘dumb-bell tumour’. Further lesions both intra- and extra-spinally may also be demonstrated.
- Increase in size of lesions may represent malignant transformation.

## Differential diagnosis

- Isolated neurogenic tumours (e.g. neuroblastoma or ganglioneuroma).
- Lateral meningocele.
- Primary lung tumour.
- Bronchogenic cyst.
- Thoracic aortic aneurysm.
- Paraspinal abscess.
- Paraspinal extramedullary haematopoiesis.

## Management

- May not require any treatment.
- Consider surgical excision of tumours if symptomatic.
- Follow-up screening of neurogenic tumours. There is a risk of malignant transformation, particularly if the tumour enlarges rapidly.



CT confirms the mass originates within the posterior mediastinum (arrows) and is continuous with the adjacent intervertebral foramen.



# Pancoast tumour

## Characteristics

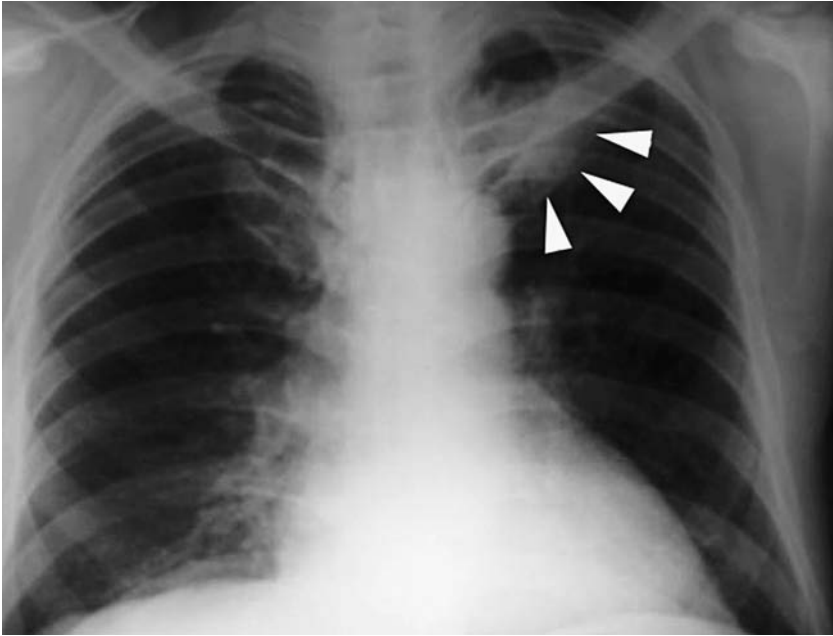
- This is a primary lung tumour located in the lung apex.
- The majority are squamous cell carcinomas.
- They represent 3% of all primary lung tumours.
- Strong association with cigarette smoking.
- Usual age at presentation >40 years.
- The tumour spreads locally and patients often present with a specific set of signs and symptoms.

## Clinical features

- May be asymptomatic.
- Chest and/or shoulder pain. Some patients are referred for a shoulder X-ray.
- Cough, sputum, haemoptysis.
- Weight loss and malaise.
- SVC obstruction.
- Hoarse voice.
- **Horner's syndrome** (enophthalmos, miosis, ptosis and anhidrosis) due to direct involvement of the sympathetic plexus.
- Wasting of the muscles in the hand and arm due to brachial plexus invasion.

## Radiological features

- **CXR** – unilateral apical pleural thickening/mass. The mass lesion may cavitate. Hilar enlargement secondary to lymphadenopathy. May be rib destruction and extrathoracic soft tissue mass lesion.
- **CT** – confirms the apical mass lesion. Good for staging the tumour with assessment for mediastinal and metastatic disease.
- **MRI** – excellent for demonstrating local tissue invasion, particularly on T<sub>1</sub> sequences as extrathoracic spread and brachial plexus involvement are readily identified. Accurate assessment is needed prior to consideration for surgical excision.
- **PET/CT** – increased uptake of FDG tracer in primary cancer and metastases. Sensitive tool for staging tumours and discriminating ambiguous mass lesions.



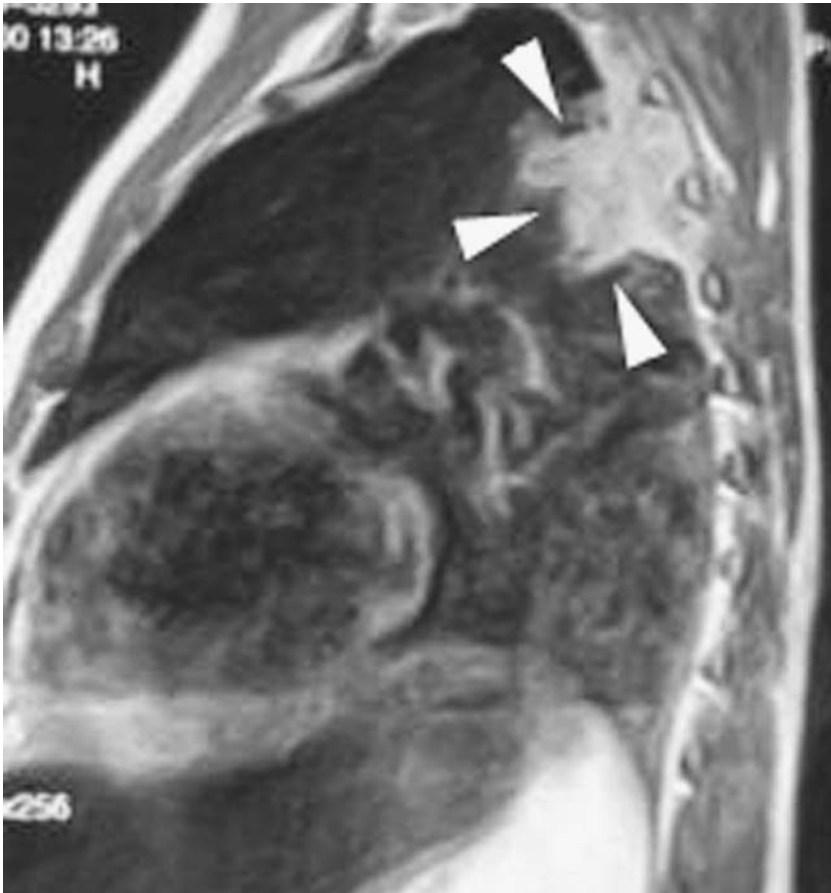**Pancoast tumour.** Ill-defined tumour within the left apex (arrowheads).

## Differential diagnosis

- TB infection – this can represent active disease or simply be post infective pleuroparenchymal thickening.
- Fungal infection.
- Wegener's granulomatosis.

## Management

- Sputum cytology.
- Transbronchial or transthoracic biopsy.
- Accurate staging.
- Radiotherapy.
- Surgical resection.



**Sagittal T<sub>1</sub> MRI post contrast.** This demonstrates the enhancing tumour eroding through the posterior thoracic wall (arrowheads).

## Pectus excavatum

### Characteristics

- Also known as a funnel chest.
- Relatively common thoracic skeletal anomaly.
- Represents posterior depression of the sternum with closer approximation of the sternum to the spine.
- The majority are isolated cases, but it can be associated with congenital heart disease and Marfan's syndrome.

### Clinical features

- The majority have no symptoms.
- May be exertional dyspnoea.
- Patients with concomitant conditions or syndromes may have symptoms and signs related to these associated problems.

### Radiological features

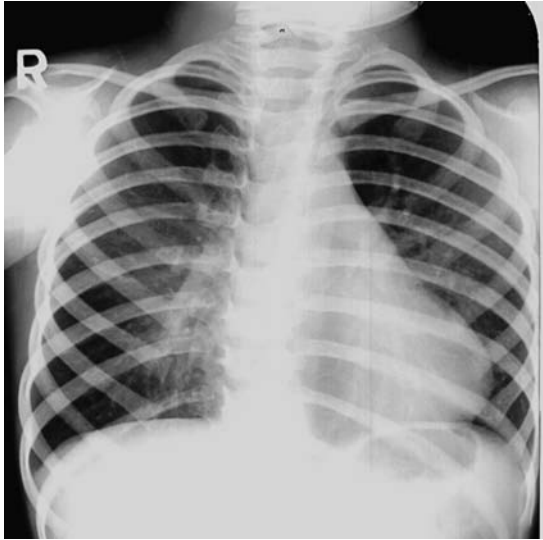
- **CXR** (PA film) – shift of the heart to the left with straightening of the left heart border. The right heart border is indistinct. The posterior ribs appear horizontal and the anterior ribs are angulated steeply (so called 'sevens – reverse sevens' appearance).
- The **lateral CXR** confirms the depression of the sternum and the narrow AP diameter of the thorax.

### Differential diagnosis

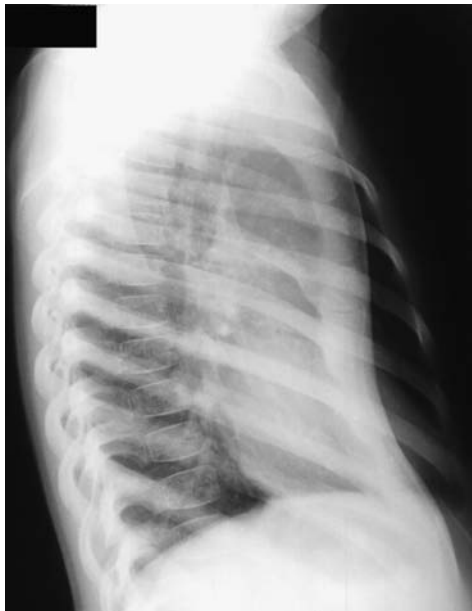- Right middle lobe collapse/consolidation mimics pectus on the frontal CXR. A lateral film allows for accurate differentiation.

### Management

- No active treatment required.



**Pectus excavatum.** ‘Seven, Reverse Seven’ orientation of the ribs. The posterior ribs adopt a more horizontal position and the anterior ribs a more vertical position than normal. As a result the mediastinum is displaced to the left, resulting in a spurious appearance of right middle lobe pathology.



The lateral view confirms the sternal deformity.

# Pericardial cyst

## Characteristics

- These are congenital out-pouchings from the parietal pericardium.
- Rarely communicate with the pericardial space. If the cysts communicate with the pericardial space they are referred to as pericardial diverticula.
- Appear as well-defined oval mass attached to the pericardium usually in the right cardiophrenic angle.

## Clinical features

- The majority are asymptomatic, identified incidentally on routine imaging.
- A few may describe chest pain or dyspnoea.

## Radiological features

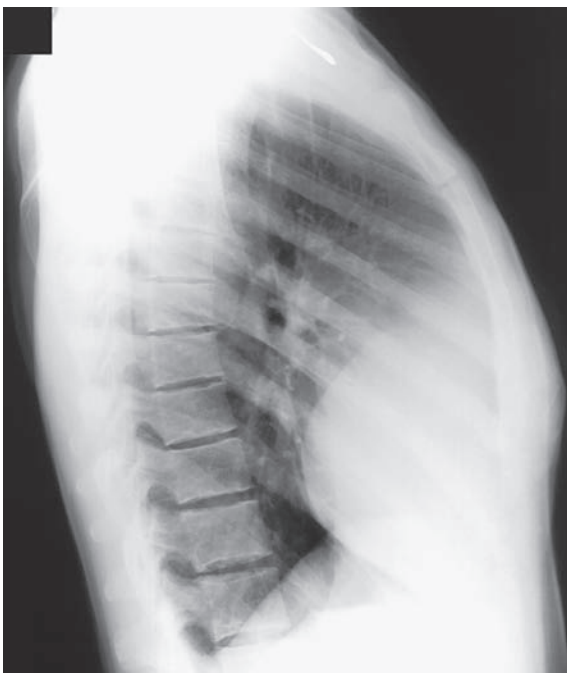
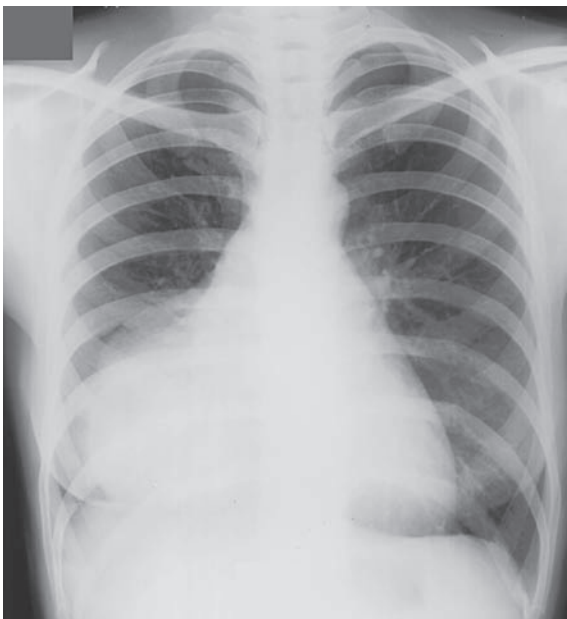- **CXR** – sharply marginated mass lesion usually in the right cardiophrenic region measuring 3–8 cm.
- **CT** – the cyst is fluid attenuation (HU <20).
- **MRI** – confirms cystic nature of the lesion with high T<sub>2</sub> signal. The pericardium can often be demonstrated on MR sequences, as a low signal pencil line surrounding the cyst.

## Differential diagnosis

- Foregut duplication cyst.
- Primary or secondary lung neoplasm.
- Mediastinal pleural metastasis.

## Management

- No active management required.



**Pericardial cyst.** Sharply marginated round mass at the right cardiophrenic angle.



# Pleural effusion

## Characteristics

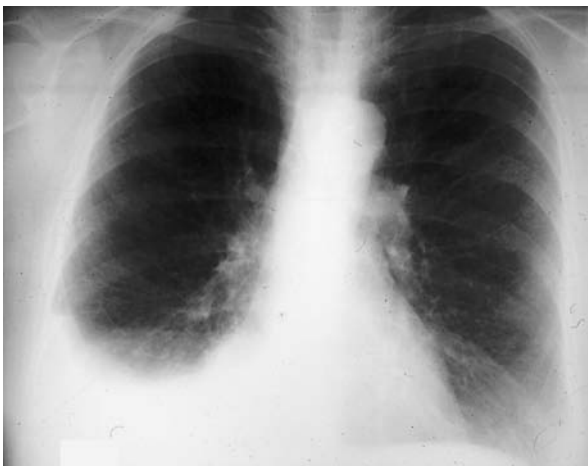- Accumulation of fluid within the pleural space.
- Subdivided into transudates or exudates based on the protein content of the fluid.
- **Transudates** (protein < 3 g/dl) – often bilateral due to increased hydrostatic pressure (e.g. cardiac or renal failure) or decreased colloid oncotic pressure (nephrotic syndrome or cirrhosis).
- **Exudates** (protein > 3 g/dl) – due to increased permeability of abnormal capillaries (e.g. infection/empyema, malignant disease, blood, collagen vascular disorders and pancreatitis).
- The effusion lies dependently within the pleural space unless it is loculated.
- Effusions in specific conditions are often found on one particular side only, e.g. left side in pancreatitis.

## Clinical features

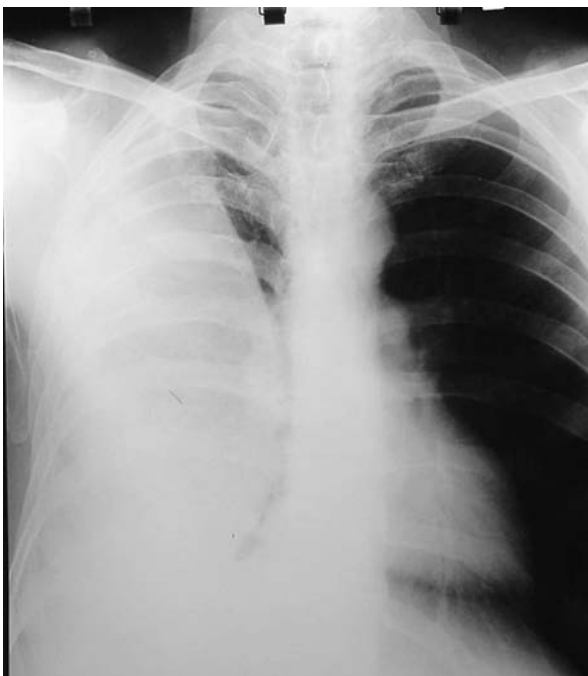- May be asymptomatic.
- SOB.
- Cough, haemoptysis or sputum.
- Fever or swinging pyrexia.
- Chest pain.
- Generalised oedema.
- Weight loss or malaise.
- Symptoms relating to an underlying systemic cause, e.g. rheumatoid arthritis, pancreatitis or chronic renal failure.
- Hypoxia.
- Reduced breath sounds with dull percussion on examination.

## Radiological features

- **CXR** (PA film) – effusions up to 300 ml may not be visible.
  - There may be blunting of the costophrenic angles. Radio-opaque density extending from the base with a meniscus-shaped upper surface. They may be large extending up to the apex and causing mediastinal shift away from the effusion.
  - Look for differential increased density projected beneath the diaphragm ± elevated apex of the diaphragm laterally, in keeping with a **subpulmonic effusion**.



**Right pleural effusion.** Note the meniscus-shaped upper surface of the right pleural effusion.



**Loculated pleural effusion.** The right pleural effusion has a sharply defined medial margin and an indistinct lateral margin.

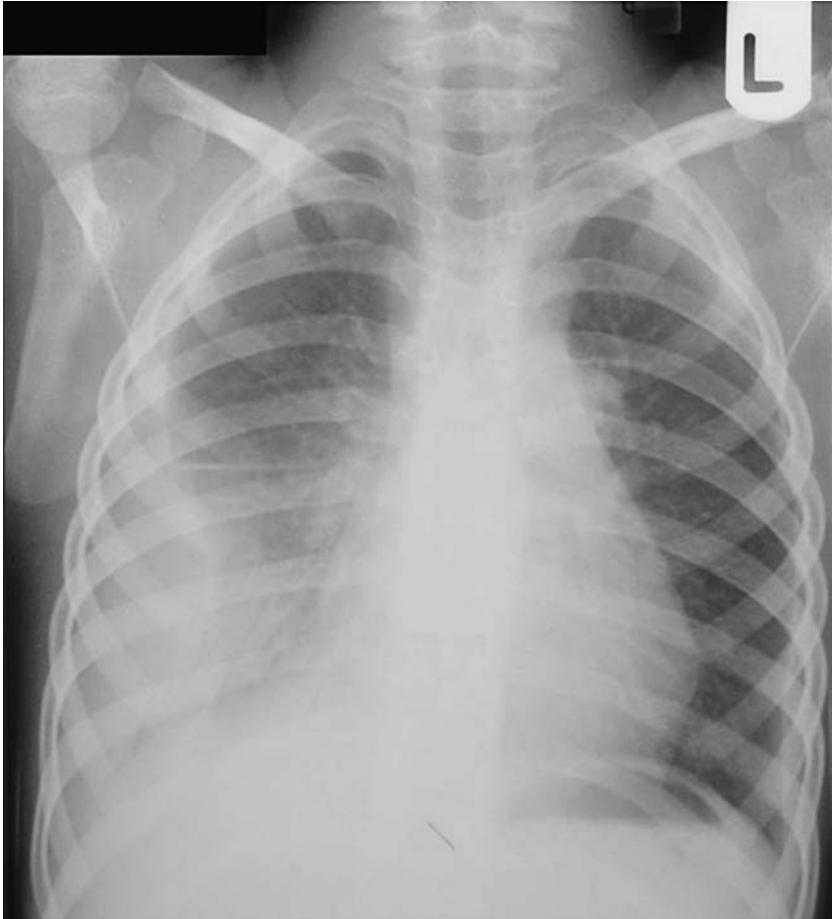
- The effusion may track up the lateral chest wall (**lamellar**), be irregular in outline (**loculated**), track along the mediastinal pleural surface – resembling lower lobe collapse – or track along a fissure (**encysted**).
  - Encysted pleural effusions may resemble a mass lesion on frontal views. Lateral films are diagnostic.
- A lateral decubitus film may identify very small effusions.
- Always look for underlying causes, e.g. heart size, lung mass, pleural nodularity, mastectomy or rib destruction.
- **Ultrasound** – confirms the size and fluid nature of the effusion. Very helpful in identifying loculations.
- **CT** – may identify small effusions, the cause of the effusion and also the presence of thickened enhancing pleura, in keeping with an exudate.

## Differential diagnosis

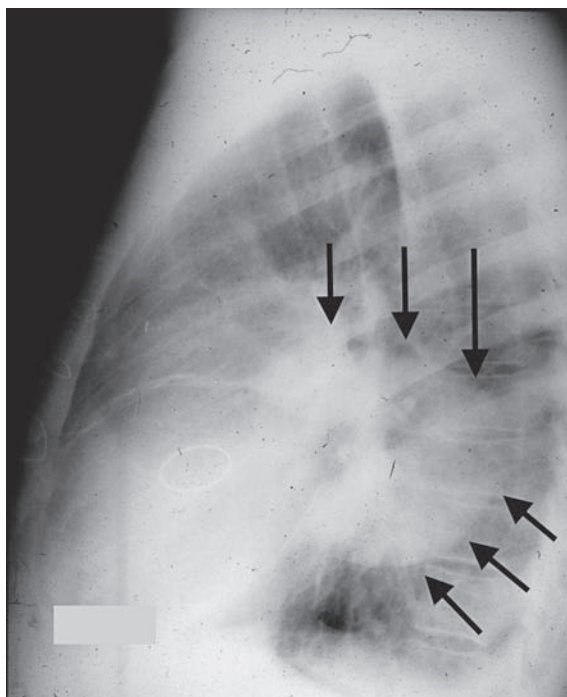
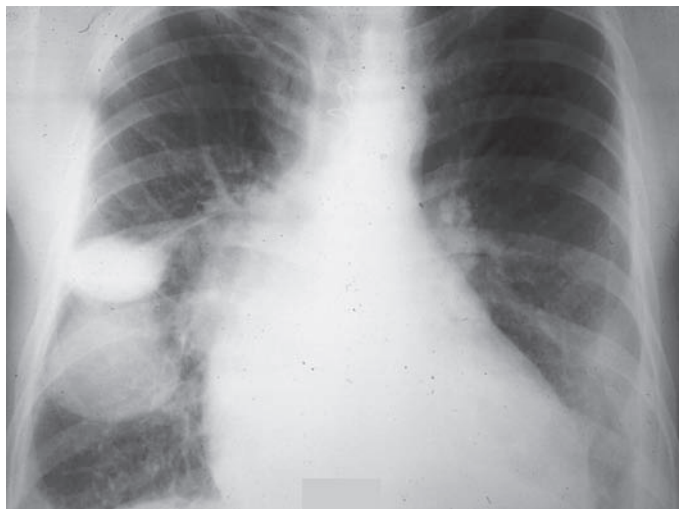- Lung consolidation ± collapse. (Ultrasound helpful diagnostic tool.)
- Pleural mass, e.g. fibroma.
- Diaphragmatic eventration.
- Subpulmonic abscess.

## Management

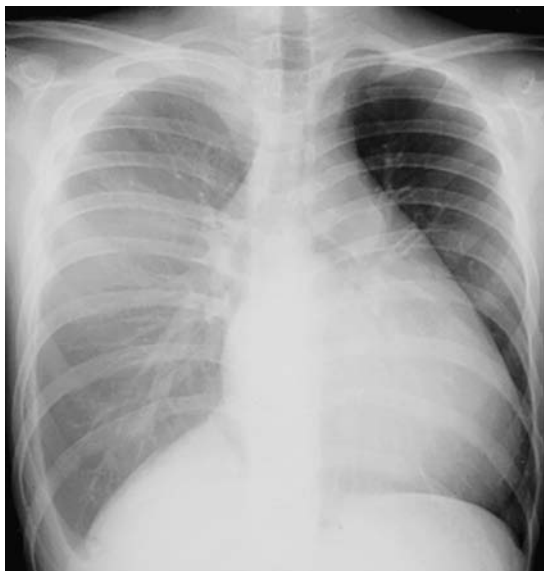- Tap the fluid to determine if it is an exudate or transudate.
- Send sample for M, C & S and cytology.
- If considering infection, assess pH (if pH < 7.2 an empyema is likely).
- If moderate/large or symptomatic – percutaneous drainage.
- Any evidence of infection/empyema – percutaneous drainage.
- Treat underlying condition, e.g. cardiac failure.
- Recurrent effusions may require pleurodesis.



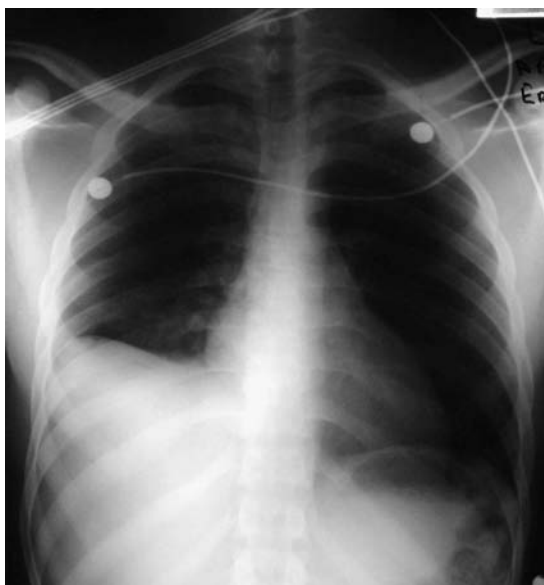**Lamellar pleural effusion.** A meniscus of fluid is seen tracking up the right lateral chest wall beneath the loose connective tissue of the visceral pleura, typical of a lamellar effusion.



**Encysted pleural effusions.** Two well-margined 'masses' within the right mid and lower zones. These are confirmed as encysted effusions within the horizontal and oblique fissures respectively, on the lateral view (arrows).



**Right pleural effusion – supine film.** The pleural fluid usually manifests as an increase in density within the affected hemithorax.



**Subpulmonic pleural effusion.** Apparent elevation of the right hemi-diaphragm, with the dome of the hemi-diaphragm shifted laterally and an acutely angled right costophrenic angle.

# Pleural mass

## Characteristics

- There are a number of conditions affecting the pleura which give rise to soft tissue pleural masses or the appearance of a pleural mass.
- **Benign** – pleural fibroma, pleural thickening or rounded atelectasis.
- **Malignant** – mesothelioma, metastases.
- The majority of pleural metastases are from lung or breast lesions, but other tumours including lymphoma, ovarian adenocarcinoma and plasmacytoma can either metastasise to or lie adjacent to the pleura giving the appearance of a pleural mass on imaging.
- A loculated empyema may resemble a pleural mass on routine imaging.
- Lastly, primary or secondary lung tumours can abut the pleura giving the appearance of a pleural mass.

## Clinical features

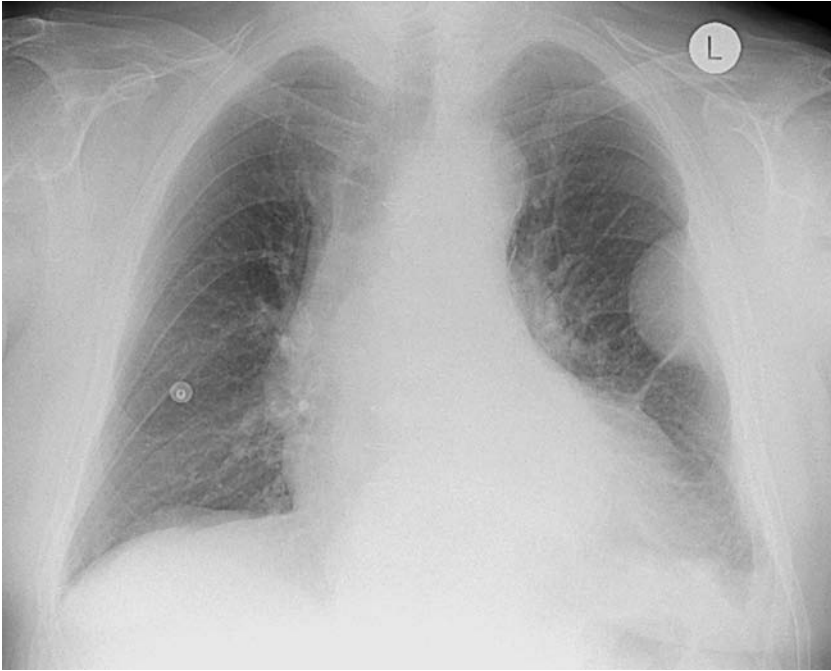
- Benign – at least 50% are asymptomatic. Others present with cough, dyspnoea or chest pain.
  - Clubbing and hypertrophic pulmonary osteoarthropathy are not uncommon.
  - Rarely, symptomatic episodic hypoglycaemia is a recognised feature of pleural fibromas.
- Malignant lesions are usually more symptomatic.
  - Both SOB and chest wall pains are predominant features.
  - Weight loss and malaise accompany malignant disease.

## Radiological features

- **CXR** – peripherally based soft tissue mass. Sharp medial margin with indistinct lateral margins. They may be multiple or solitary. Extra-thoracic soft tissue extension, rib destruction or lymphadenopathy suggests malignant disease.
- Pleural fibromas can be very large, up to 20 cm in diameter. They are pedunculated and can change position with posture.
- **CT** or **MRI** – confirms the pleurally based mass and characterises the presence of haemorrhage, calcification, multiplicity and local invasion.

## Differential diagnosis

- The differential lies between discriminating true from apparent pleural masses and determining benign from malignant disease.



**Pleural fibroma.** Mass in the periphery of the left mid zone. This has a sharply defined medial border and an ill-defined lateral border, indicating that it is likely to be pleural in origin.

## Management

- Management depends on the underlying cause.
- Investigation should be used to fully characterise the mass.
- In many cases no active treatment is required, particularly if benign and asymptomatic.
- Surgical excision for large masses.
- Radiotherapy can be used for malignant lesions.



# Pneumoconiosis

## Characteristics

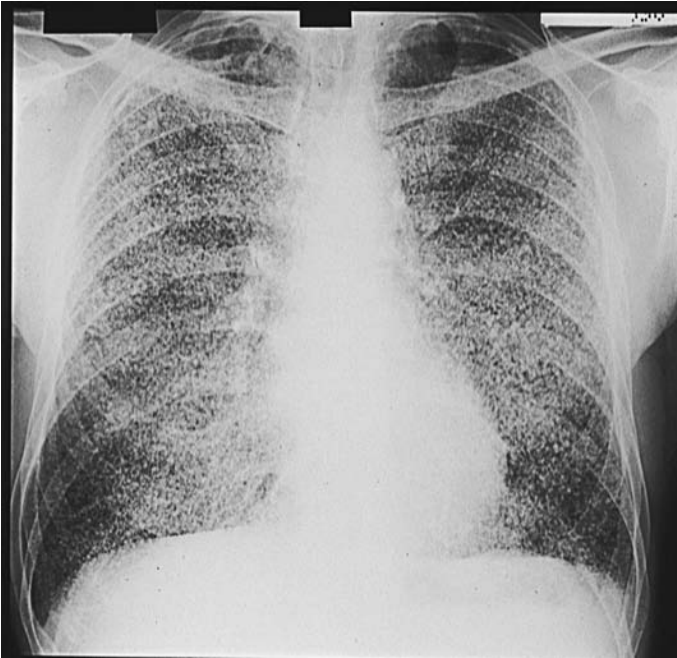
- These represent a spectrum of lung conditions caused by inhalation of inorganic dust particles. The particles overwhelm the lung's defence mechanism and induce a chronic granulomatous reaction.
- The exposure to the particles occurs over many years.
- The resulting lung changes are progressive and irreversible.
- There are two main subtypes of pneumoconiosis:
  - Minimal symptoms as the particles are not fibrogenic, e.g. stannosis (tin), baritosis (barium) and siderosis (iron).
  - Symptomatic due to fibrogenic particles, e.g. silicosis (silica), asbestosis (asbestos) and coal workers' pneumoconiosis.
- All the conditions have very similar characteristic clinical and radiological features.

## Clinical features

- May be asymptomatic.
- Non-productive cough.
- Dyspnoea – this is progressive.
- Weight loss, malaise.
- Hypoxia.
- Restrictive lung function.

## Radiological features

- **CXR** – multiple bilateral 3- to 10-mm nodules present in the upper and mid zones. Some of the nodules coalesce. Different particles produce different density nodules, e.g. stannosis can be very dense. There may be hilar lymphadenopathy some of which show egg shell calcification. There may be fibrotic change and parenchymal distortion.
- **HRCT** – demonstrates small nodular opacities, interlobular septal thickening, fibrous parenchymal bands and a ground glass pattern.



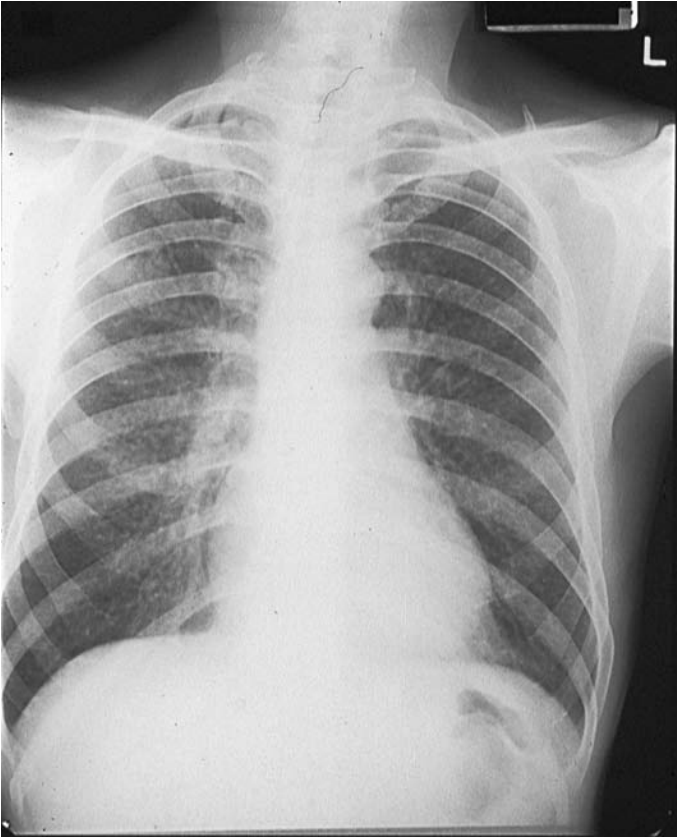
**Pneumoconiosis – stannosis.** Multiple small dense bilateral pulmonary nodules.

## Differential diagnosis

- Sarcoidosis.
- TB.
- Post viral infections.
- Miliary metastases.
- Pulmonary alveolar microlithiasis.

## Management

- No effective active treatment.



**Pneumoconiosis – talcosis.** Multiple small bilateral pulmonary nodules. These are less dense than the nodules seen in stannosis.

# Pneumoperitoneum

## Characteristics

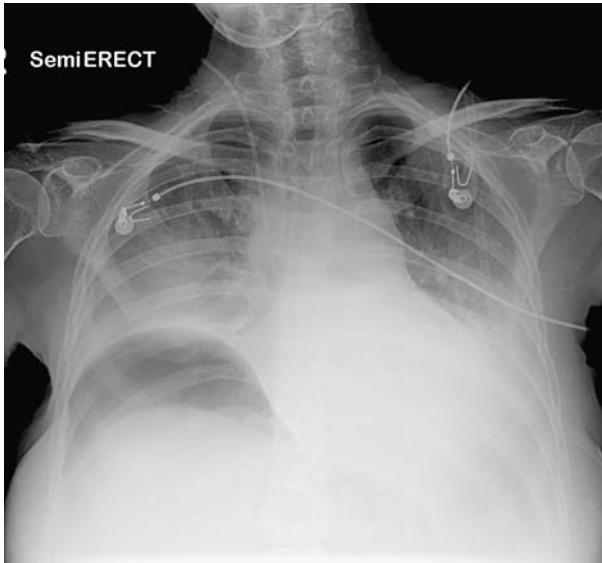
- Free intra-abdominal air.
- May follow surgery. It is normal to see free air up to 3 days following a laparotomy. Beyond 3 days, there is a high suspicion of air leak from an abdominal/pelvic viscus.
- Associated with a perforated abdominal or pelvic viscus (e.g. duodenal ulcer, ruptured appendicitis or diverticulitis, vaginal injury), blunt or penetrating trauma, necrotising enterocolitis, inflammatory bowel disease.
- Pneumomediastinum may track into the abdomen.
- Rupture of a bleb from pneumatosis cystoides intestinalis may lead to asymptomatic intraperitoneal air.

## Clinical features

- THIS IS A SURGICAL EMERGENCY.
- Abdominal pain. Vomiting. Diarrhoea.
- Pyrexia. Sweating.
- Patient shock – tachycardia and hypotension.
- Abdominal tenderness with signs of peritonism (guarding and rebound tenderness).

## Radiological features

- As little as 5 ml of air may be visible.
- **Erect CXR** – free air lying under one or both of the hemidiaphragms. The **CXR** may be normal or if supine/semi-recumbent, it may be missed.
- **AXR** or decubitus films may be helpful
  - Locules of gas lying outside bowel often with odd/linear margins.
  - Both sides of the bowel may be visible (Rigler's sign).
  - The falciform ligament may be demonstrated.
  - Hyperlucency overlying the liver with clear inferior hepatic margin outlined by air.
- **CT** – demonstrates even tiny locules of free air if clinically suspicious. Also allows assessment of underlying cause.



**Pneumoperitoneum.** There is clearly free air under the right hemidiaphragm. This is a surgical emergency. In addition there is dense left lower lobe consolidation.

## Differential diagnosis

- Subphrenic abscess.
- Loops of gas-filled bowel lying beneath the diaphragm. Colon interposed between the right hemidiaphragm and liver is known as Chilaiditi's syndrome.
- Loculated pneumothorax or empyema.
- Free retroperitoneal air.

## Management

- ABC.
- Pain relief. NBM.
- A perforated viscus is a surgical emergency. Further characterisation of the underlying cause may be demonstrated with CT.
- Laparotomy and definitive treatment of the perforated viscus.

# Pneumothorax

## Characteristics

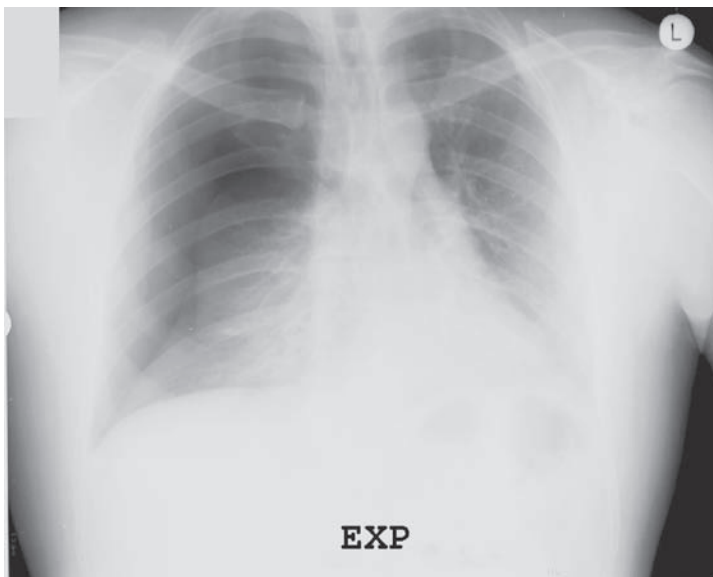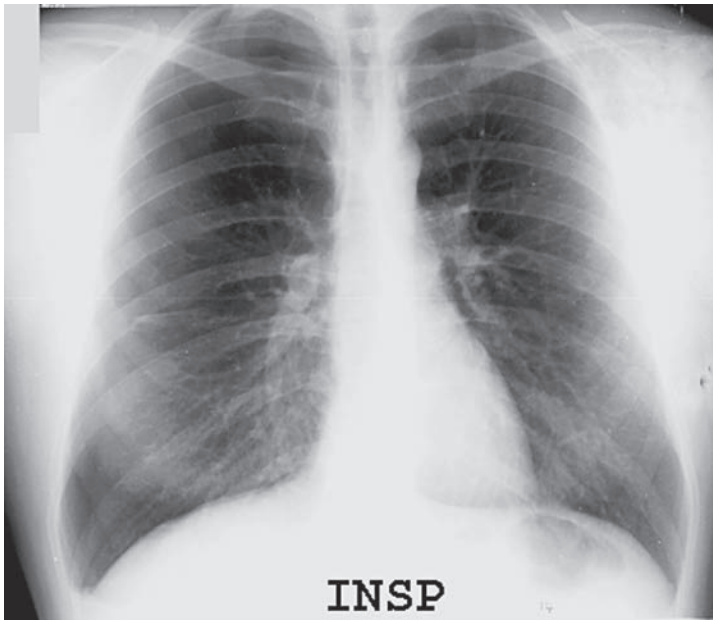
- Accumulation of air within the pleural cavity.
- A common complication of chest trauma (15%–40%).
- They may be spontaneous, related to underlying lung/pleural disease or follow trauma.
- Divided into three categories:
  - *Simple* – no communication with the atmosphere or mediastinum. No midline shift.
  - *Communicating* – associated with chest wall defect.
  - *Tension* – progressive accumulation of air under pressure within the pleural cavity; leading to mediastinal shift with compression of the contralateral lung and great vessels.

## Clinical features

- Chest pain and shortness of breath are common.
- Variable spectrum ranging from acutely unwell, with cyanosis and tachypnoea, to the relatively asymptomatic patient.
- Signs and symptoms don't necessarily correlate well with the degree of associated lung collapse.
- Signs of a tension pneumothorax include:
  - Tachycardia
  - Jugulo-venous distension
  - Absent breaths sounds
  - Hyper-resonance to percussion
  - Tracheal and cardiac impulse displacement away from the affected side
  - The patient may be acutely unwell with signs of cardio-respiratory distress.

## Radiological features

- *Simple* – visceral pleural edge visible. Loss of volume on the affected side (e.g. raised hemidiaphragm). A small pneumothorax may not be visualised on a standard inspiratory film. An expiratory film may be of benefit.
- *Tension* – THIS IS A CLINICAL AND NOT A RADIOLOGICAL DIAGNOSIS! Associated mediastinal shift to the opposite side is seen.
- Pneumothoraces may be difficult to visualise on frontal films, particularly on supine films. Look for increased lucency over the costophrenic recess (the deep sulcus sign).



**Simple pneumothorax.** The right lung edge is faintly visible on the inspiratory film. However, the pneumothorax becomes clearly evident on the expiratory film.



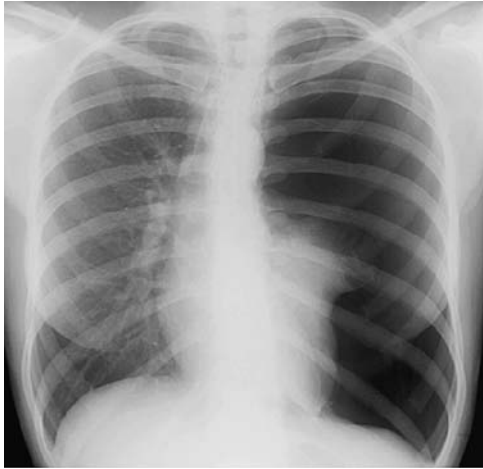- Look for features of underlying pleural or lung disease.
- A CT scan may be necessary if diagnosis is in doubt and symptoms persist.

## Differential diagnosis

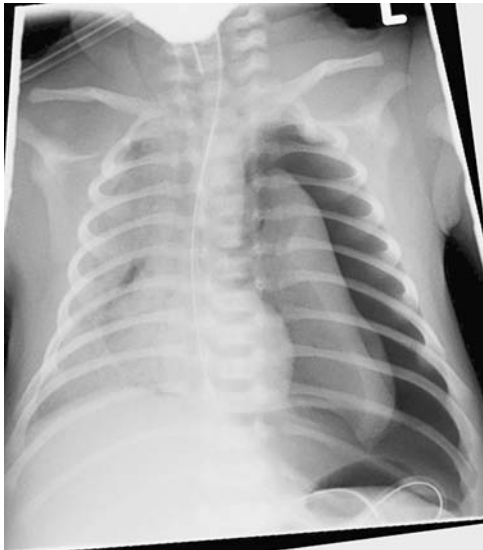- Pneumothoraces, particularly if persistent, raise the possibility of a bronchopleural fistula. This may require surgical intervention to correct the fistula. A CT scan is good at demonstrating a direct communication between the bronchi and pleural space. If diagnostic doubt persists a ventilation scan will confirm the presence but not location of the fistula.

## Management

- *Simple* – depends on size and clinical picture.
  - Conservative treatment with follow-up chest radiograph.
  - Aspiration using a three-way tap may be adequate.
  - Definitive management – tube thoracostomy.
- *Tension* – a needle thoracostomy with a 14/16-g cannula in the 2nd intercostal space (mid-clavicular line).
- Recurrent pneumothoraces may require pleurodesis.



**Tension pneumothorax – case 1.** Large left-sided pneumothorax with early mediastinal shift to the right. This medical emergency is a clinical diagnosis and not a radiological one.



**Tension pneumothorax – case 2.** This is not an infrequent complication of ventilation. The barotrauma associated with ventilation results in accumulation of air within the pleural space with limited egress of air. As a result, there is mediastinal shift away from the side of the pneumothorax. Associated deep sulcus sign. This is a medical emergency.

# Poland's syndrome

## Characteristics

- Congenital absence of the pectoralis major muscle.
- May be associated with ipsilateral absence of the pectoralis minor muscle, rib and arm anomalies (syndactyly in the hand).
- Autosomal recessive condition.

## Clinical features

- Most are asymptomatic.
- Diagnosis is an incidental finding.

## Radiological features

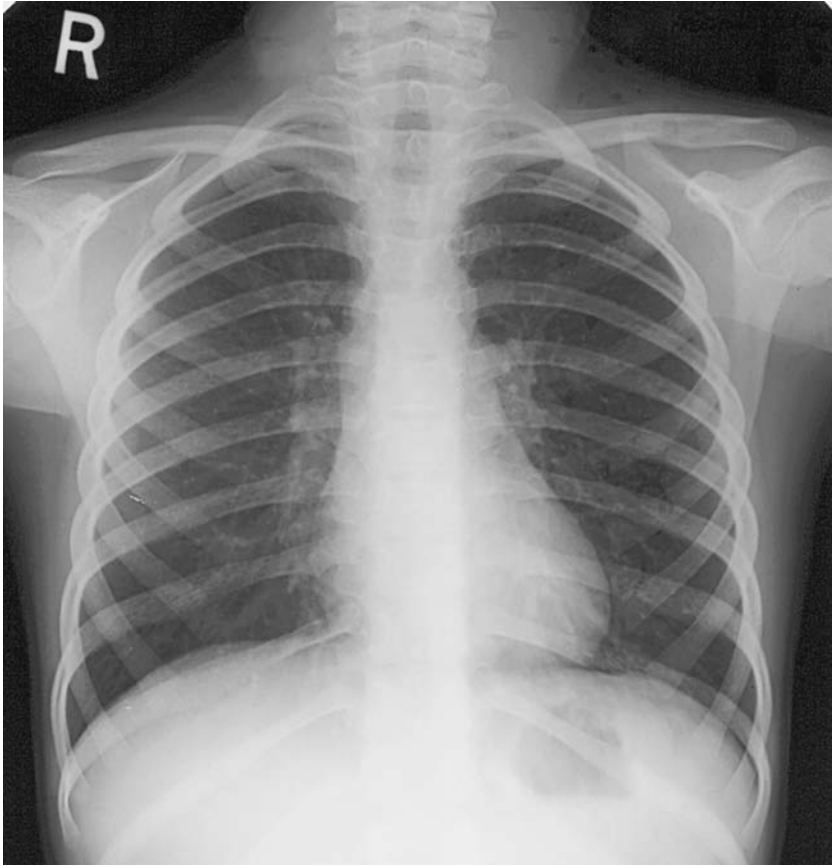
- **CXR** – increased transradiancy of the affected hemithorax. Absence of the normal pectoralis soft tissue shadow.
- **CT** – confirms the absent muscle and normal lung.

## Differential diagnosis

- Post mastectomy changes.
- Unilateral obliterative bronchiolitis (e.g. Macleod's syndrome) may mimic Poland's syndrome.

## Management

- No active management.



**Poland syndrome.** Unilateral absence of the sternocostal head of the left pectoralis major muscle. Note the asymmetry of the axillary folds and the hyper-transradiancy of the left hemithorax.

## Post lobectomy/post pneumonectomy

### Characteristics

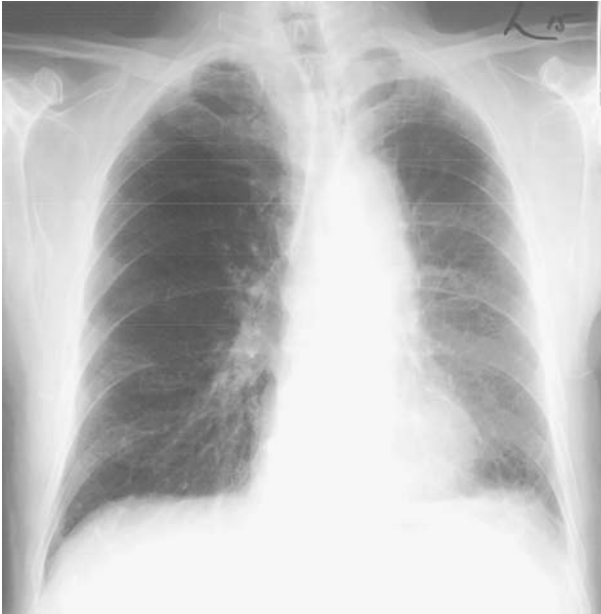- Represents surgical removal of a single lobe (lobectomy) or total lung (pneumonectomy) from a hemithorax.
- Previously performed for chronic infections (e.g. TB). Now surgery is increasingly performed for treatable lung tumours or in the treatment of bullous chronic airways disease.

### Clinical features

- Usually asymptomatic if uncomplicated.
- Some patients have SOB or mild chest pains.
- Increasing symptoms such as cough, pyrexia, dyspnoea, weight loss or malaise should alert the clinician to complications of lobectomy (e.g. bronchopleural fistula) or recurrence of the initial pathology (tumour metastases).

### Radiological features

- **CXR**
  - Volume loss in the affected hemithorax, with elevation of the hemidiaphragm. The signs may be very subtle, as hyperexpansion of the remaining lobe(s) replaces the excised lobe.
  - There may be rib anomalies or surgical staples following surgery. Always look for any evidence of the underlying cause of the lobectomy and possible complications.
  - The pleural space often fills with fluid following surgery, particularly after removal of a whole lung. Over time this should fully fill, with complete opacification of the hemithorax.
    - Following surgery, an increase in air on the side of the surgery suggests either infection or a bronchopleural fistula.
    - The fistula can be confirmed directly with **CT** scans or indirectly with ventilation scanning demonstrating abnormal ventilation to the hemithorax.



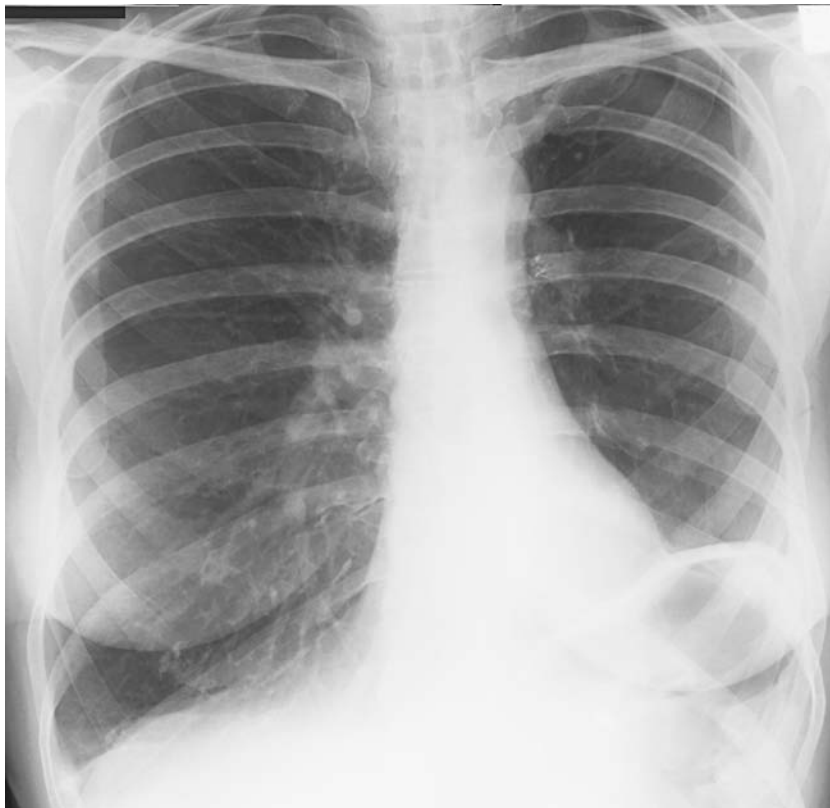**Post left upper lobectomy.** Volume loss in the left hemithorax with mediastinal shift to the left. Note the subtle increase in density within the left hemithorax, as the left lower lobe expands to replace the excised lobe.

### Differential diagnosis

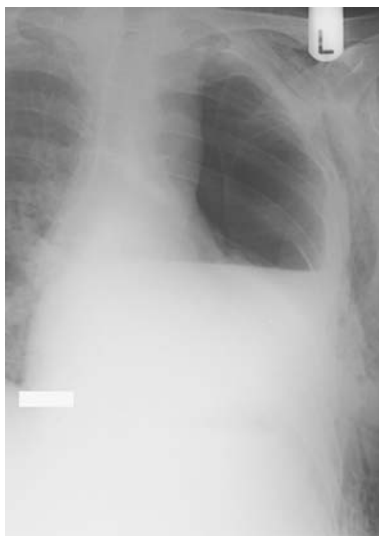
- Pulmonary hypoplasia – small or absent pulmonary artery.
- Phrenic nerve palsy – postural changes in the volume of the hemithorax.
- Diaphragmatic eventration.
- Tight lobar collapse.

### Management

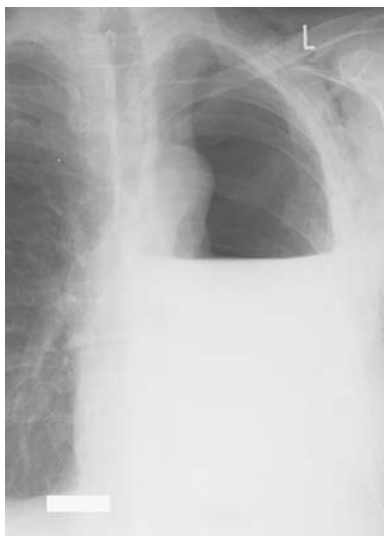
- No active treatment required.
- A bronchopleural fistula will require surgical repair.



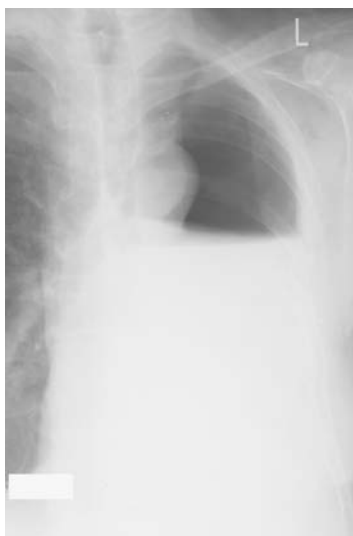
**Post left lower lobectomy.** Volume loss in the left hemithorax with mediastinal shift to the left and associated elevation of the left hemidiaphragm. There is compensatory hyperinflation of the right lung.



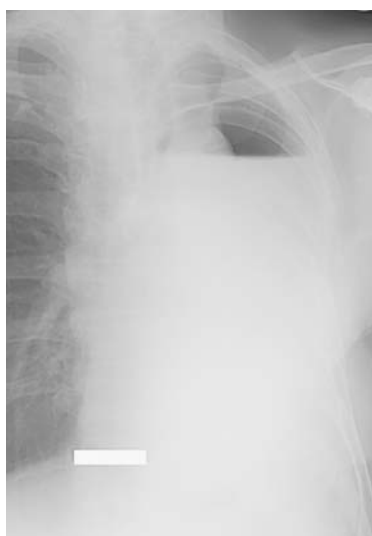
Day 1.



Day 6.



Day 15.  
Pneumonectomy Series



5 weeks.



# Progressive massive fibrosis

## Characteristics

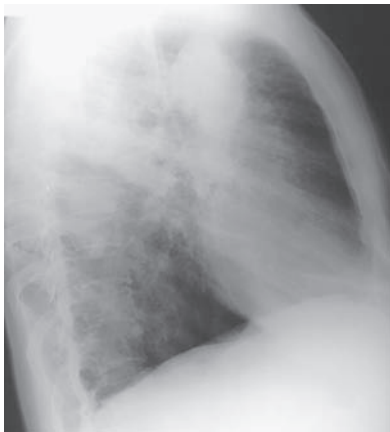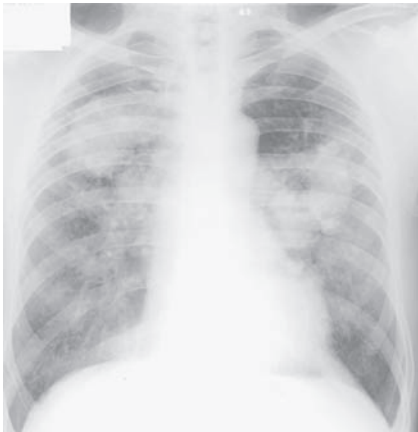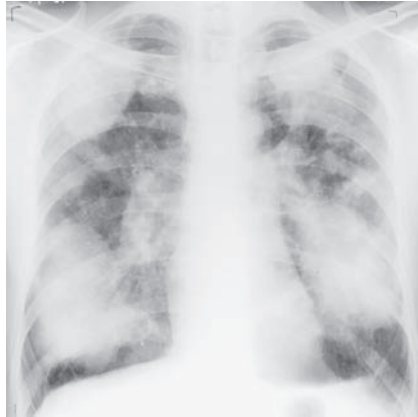- A specific form of pneumoconiosis resulting as a complication of chronic exposure to silicosis.
- At least 20 years of exposure to silicon dust.
- Occurs exclusively in the posterior segments of the upper lobes and superior segment of the lower lobes.

## Clinical features

- May be asymptomatic.
- Non-productive cough.
- Dyspnoea – this is progressive.
- Weight loss, malaise.
- Hypoxia.
- Restrictive lung function.

## Radiological features

- **CXR**
  - Bilateral masses (>1 cm) usually starting in the periphery of the posterior segment of the upper lobes.
  - They coalesce and extend towards the hilum and are associated with hilar retraction.
  - Cavitation may represent superimposed active TB infection.
  - There is hilar lymphadenopathy, some of which shows egg shell calcification.
  - There may be upper lobe fibrotic change.
  - The mass lesions enlarge slowly over time.
- **BEWARE AN UNDERLYING LUNG CANCER** – usually demonstrates a more rapid change in size.
- **HRCT** – demonstrates large irregular rounded opacities, interlobular septal thickening, fibrous parenchymal bands and a ground glass pattern. There may also be patchy calcification within the lung opacities which is not seen in malignant masses. Most cases have associated emphysematous change.



**Progressive massive fibrosis – two cases.** Large bilateral and symmetrical opacities at the periphery of the lung. Migration towards the hila. The medial border is often ill-defined with the lateral border sharp and parallel to the rib cage.

### Differential diagnosis

- Sarcoid.
- Cryptogenic organising pneumonia.
- Lymphoma.
- Metastatic disease.

### Management

- No active treatment available.

# Pulmonary arterial hypertension

## Characteristics

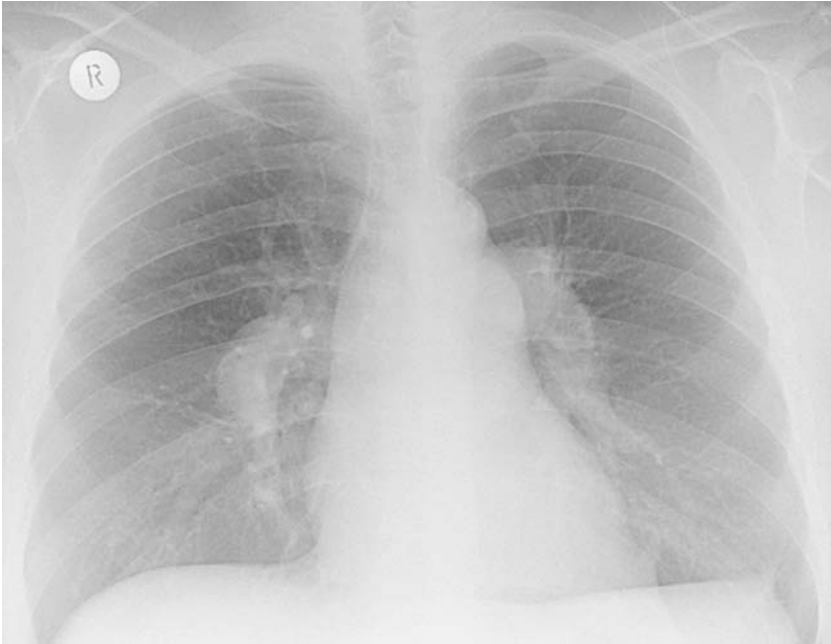
- Sustained pulmonary arterial pressure > 25 mmHg.
- Several causes
  - Excessive pulmonary blood flow, e.g. left to right shunts, AVMs and thyrotoxicosis.
  - Obliteration of pulmonary vasculature, e.g. pulmonary arterial emboli, idiopathic (primary pulmonary hypertension), vasculitis and chronic lung disease.
  - Excessive pulmonary vasoconstriction, e.g. hypoxia or drugs.
  - Secondary to pulmonary venous hypertension, e.g. left ventricular failure or mitral stenosis.
- Primary pulmonary hypertension is an idiopathic disease of young women.

## Clinical features

- Can be asymptomatic, particularly early.
- Progressive SOB.
- Haemoptysis.
- Chest pains.
- Cyanosis.
- Hypoxia.
- Peripheral oedema.

## Radiological features

- **CXR**
  - Enlargement of the main, right and left pulmonary arteries (main PA diameter >29 mm, right PA >16 mm and left PA >15 mm).
  - Rapid tapering of the pulmonary vasculature ('peripheral pruning').
  - The heart size may be normal or enlarged.
  - Look for underlying causes, e.g. chronic airways disease, AVMs or heart disease.
- **HRCT** – confirms pulmonary enlargement. There may be a mosaic pattern to the lungs with small-calibre vessels present in the low attenuation areas.
- **Echocardiography** – assessment of pressures within the pulmonary arterial system and looks for possible underlying causes.



**Pulmonary arterial hypertension.** Increase in calibre of central vessels. Peripheral vascular pruning.

### Differential diagnosis

- The main differential lies within diagnosing the cause of the pulmonary artery enlargement.
- Bilateral hilar lymphadenopathy may mimic the CXR appearances of pulmonary arterial hypertension.

### Management

- Treat the underlying cause, e.g. left ventricular failure, pulmonary emboli or cardiac shunts.
- Younger patients, e.g. with PPH, can be considered for heart lung transplants.

# Pulmonary arteriovenous malformation

## Characteristics

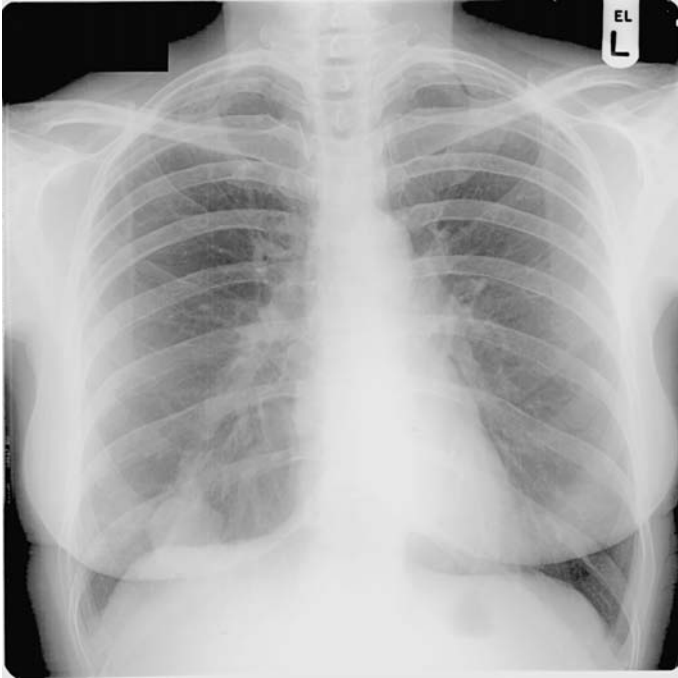- This is abnormal vascular communication between a pulmonary artery and vein.
- Congenital or acquired (cirrhosis, post TB, cancer).
- Multiple lesions in 40%.
- Strong association with Rendu–Osler–Weber syndrome in approx. 50%.
- AVMs usually present in lower lobes.
- Complications of AVM
  - Cerebrovascular accident (paradoxical embolus).
  - Brain abscess (paradoxical embolus).
  - Polycythaemia.
  - Haemothorax.
  - Pulmonary arterial hypertension.

## Clinical features

- At least 50% of patients are asymptomatic with an AVM found incidentally.
- Exertional dyspnoea.
- Haemoptysis.
- Cyanosis, if the AVM is large and associated with a significant right to left shunt.
- Cutaneous AVMs.
- May present with TIA/CVA or cerebral abscess.

## Radiological features

- **CXR**
  - Sharply defined rounded mass usually in the lower lobe.
  - May be solitary or multiple.
  - Occasionally dilated feeding/draining vessels are visible.
  - Pulmonary arterial enlargement secondary to pulmonary arterial hypertension.
- **CT** – confirms the enhancing mass lesion. Feeding vessels and phleboliths can be demonstrated.
- **Radionuclide study** – demonstrates and quantifies the extent of the right to left shunt at the level of the AVM. Tracer (<sup>99m</sup>Tc) uptake within the kidneys confirms the shunt.
- **Angiography** – demonstrates feeding artery and draining vein(s).



**Pulmonary arteriovenous malformation.** Sharply defined lobulated rounded mass in the right lower zone. A cordlike band is seen from the mass to the hilum  $\equiv$  feeding artery and draining veins.

## Differential diagnosis

- Lung neoplasm or secondary metastases.
- Granuloma.
- Pulmonary sequestration.
- Infection, especially tuberculoma.
- Pulmonary infarct.

## Management

- Confirm diagnosis and quantify the right to left shunt.
- Referral to a specialist unit for embolisation. Complete successful embolisation can be a very difficult procedure.
- Further AVMs can develop over time.
- Annual follow-up with CXR and radionuclide studies (looking for the presence of right to left shunts).

# Sarcoidosis

## Characteristics

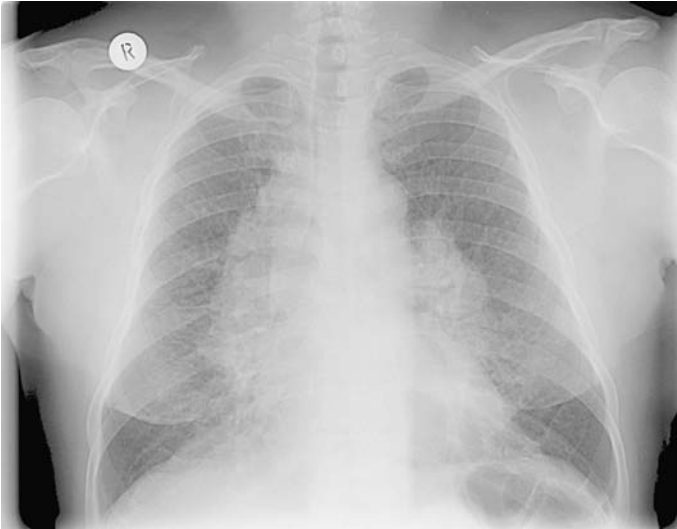- Multisystem non-caseating granulomatous disorder of unknown aetiology.
- Age at presentation 20–40 years.
- More common in females and black people.
- Present throughout the world, but more common in temperate climates.
- Diagnosis is made from a combination of clinical, radiological and histological features.
- Thoracic involvement in 90%.
- Can also affect skin, eyes, liver, spleen, CNS and heart.

## Clinical features

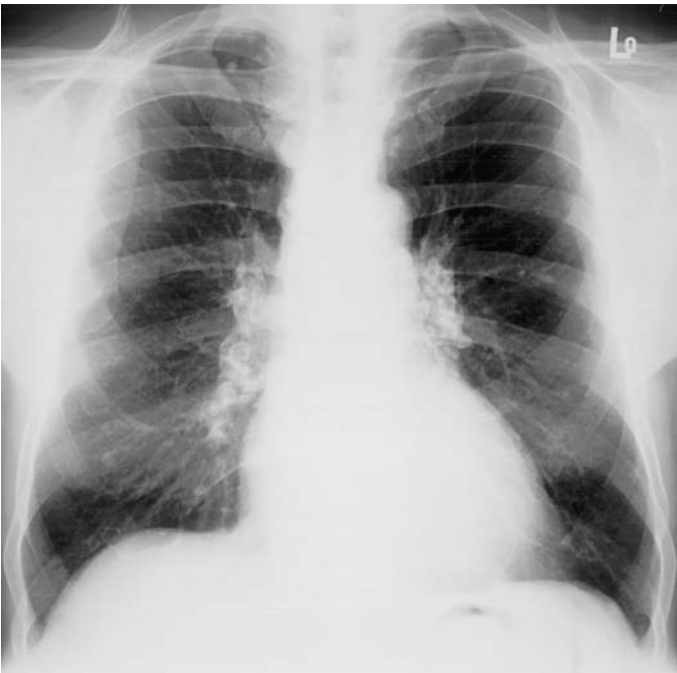- Up to one-third are asymptomatic.
- Acute presentation (Löfgren's syndrome) with fever, malaise, arthralgia, erythema nodosum and uveitis.
- Chronic presentation with fever, weight loss, dry cough or SOB.
- Symptoms are usually mild if thoracic disease only.
- Rarer presentations include
  - Hypercalcaemia (renal stones, constipation and dehydration).
  - Red eyes.
  - Skin rashes.
  - Central and peripheral nerve palsies.
  - Hypothalamic deficiency.
  - Bilateral salivary gland enlargement.
  - Cardiomyopathy or arrhythmias.

## Radiological features

- **CXR**
  - May be normal.
  - **Stage 1** – bilateral hilar and mediastinal lymphadenopathy (particularly right paratracheal and aortopulmonary window nodes).
  - **Stage 2** – lymphadenopathy and parenchymal disease.
  - **Stage 3** – diffuse parenchyma disease only.
  - **Stage 4** – pulmonary fibrosis.
    - The parenchymal disease involves reticulonodular shadowing in a perihilar, mid zone distribution. There is bronchovascular and fissural nodularity. Rarely air space consolidation or parenchymal bands may also be present. Fibrosis affects the upper zones where



**Sarcoidosis.** '1-2-3 sign' – right paratracheal and right and left hilar nodes.



**Sarcoidosis.** Egg shell calcification of both hila.



the hilar are pulled superiorly and posteriorly. Lymph nodes can demonstrate egg shell calcification.

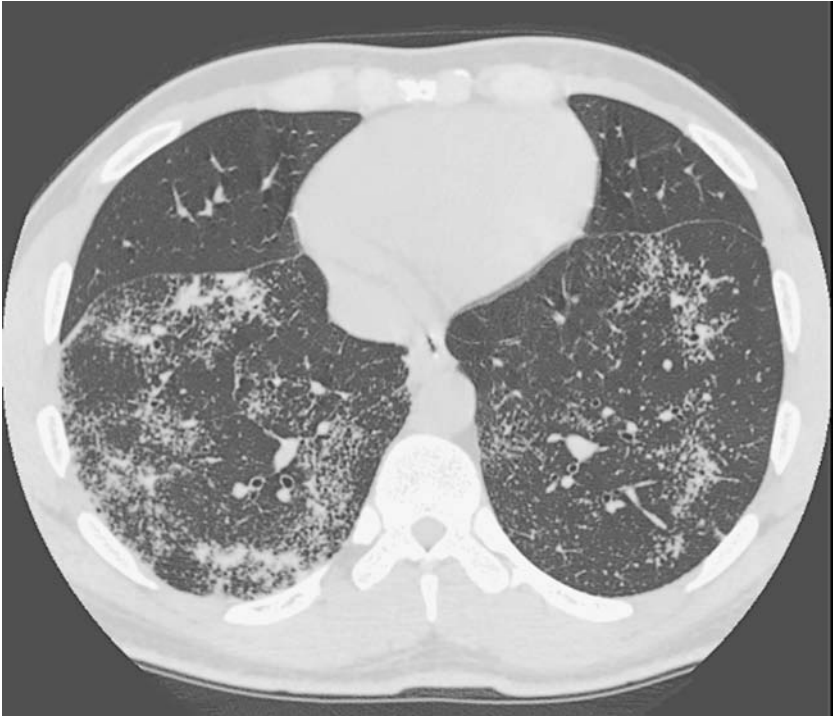
- **HRCT**
  - Very good at confirming irregular septal, bronchovascular and fissural nodularity. Traction bronchiectasis, fibrosis and ground glass change may be present. There may also be tracheobronchial stenosis. Also look for subdiaphragmatic, cardiac, bone, hepatic and splenic involvement on the same scan.

## Differential diagnosis

- Lymphoma.
- Infection – TB.
- Lymphangitis carcinomatosa.
- Chronic hypersensitivity pneumonitis.

## Management

- Biopsy or bronchoalveolar lavage may be necessary to gain histological confirmation, particularly as symptomatic cases may resemble active TB.
- Mainstay of treatment is steroids, which may be long term.



**Sarcoidosis – HRCT.** Irregular septal, bronchovascular and fissural nodularity.

# Silicosis

## Characteristics

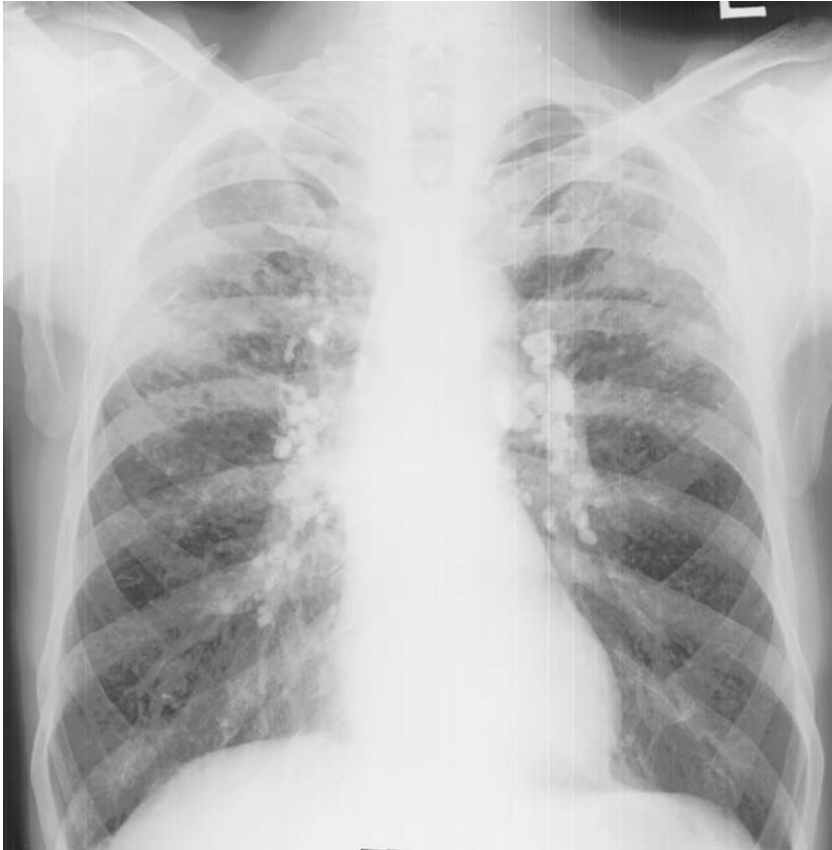- This is a specific pneumoconiosis caused by the inhalation of the inorganic dust particle silicone dioxide (mining, quarrying and sandblasting).
- The silica is phagocytosed by pulmonary macrophages. Cytotoxic reaction leads to the formation of non-caseating granulomata. These form small silicotic nodules. Pulmonary fibrosis develops as nodules coalesce.
- Acute and chronic forms.
  - The chronic form follows over 20 years of exposure.
  - The acute form may occur after as little as 1 year.
- Association with TB in 25%.
- Silicosis can develop into progressive massive fibrosis.

## Clinical features

- May be asymptomatic.
- Non-productive cough.
- Dyspnoea – this is progressive.
- Weight loss, malaise.
- Hypoxia.
- Restrictive lung function.

## Radiological features

- **CXR**
  - **Chronic form:** 3- to 10-mm nodules present in the upper and mid zones. Some of the nodules coalesce. There is hilar lymphadenopathy, some of which shows egg shell calcification. There may be upper lobe fibrotic change.
  - **Acute form:** bilateral lower lobe peripheral air space opacification and ground glass pattern.
  - **Progressive massive fibrosis:** masses (1 cm), usually in the posterior segment of the upper lobes, coalesce and are associated with hilar retraction. Cavitation may represent superimposed active TB infection.
- **HRCT**
  - Demonstrates small nodular opacities, interlobular septal thickening, fibrous parenchymal bands and ground glass pattern.



**Silicosis.** Egg shell calcification of both hila.

## Differential diagnosis

- Sarcoidosis.
- TB.
- Miliary metastases.
- Other inhalational pneumoconiosis.

## Management

- Unfortunately, despite removal of the causative dust, silicosis is often progressive.
- No active treatment available.

# Subphrenic abscess

## Characteristics

- Focal walled-off infected intra-abdominal collection lying in the sub-diaphragmatic space.
- Usually right sided.
- Gram-negative or anaerobic organisms are the usual pathogens.
- The source is usually from bowel (spread from diverticulitis, bowel infection/inflammation or even colonic malignancy).
- At increased risk are the elderly, immobile and immunosuppressed.

## Clinical features

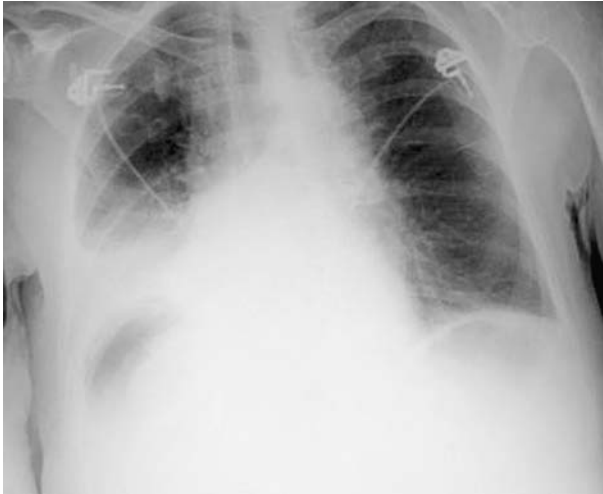- Fever (can be swinging).
- Sweats.
- Weight loss.
- Malaise.
- Cough (diaphragmatic irritation).
- Dyspnoea.

## Radiological features

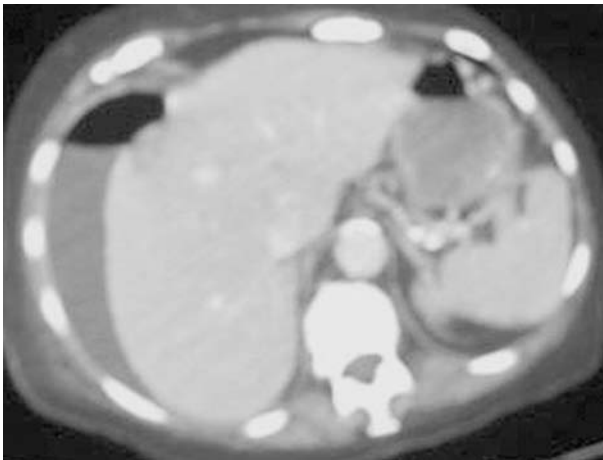
- **CXR** – elevated hemidiaphragm. Pleural effusion (reactive). Subphrenic lucency or air-fluid level.
- **CT**
  - Wall enhancing sub-diaphragmatic collection.
  - May contain locules of air.
- The collection may breach the diaphragm and communicate with the pleural space.
- May be free intra-abdominal fluid.
- Look for bowel wall thickening or diverticulosis as a possible source of the sepsis.

## Differential diagnosis

- Loculated pneumothorax.
- Lung abscess or empyema.
- Pneumoperitoneum.
- Interposed bowel, e.g. Chilaiditi's.
- Diaphragmatic eventration.
- Phrenic nerve palsy.



**Subphrenic abscess.** Note the large pocket of gas within a right subphrenic collection. This results in elevation of the right hemidiaphragm and a secondary right basal pleural effusion.



CT confirms the presence of gas within a right subphrenic collection.

**Management**

- Antibiotic therapy.
- Percutaneous drainage; may be US or CT guided.
- Occasionally surgical drainage is needed.
- Look for an underlying source of the infection. This is usually secondary to a primary bowel pathology – do in order not to miss a colonic malignancy.

# Thoracoplasty

## Characteristics

- Represents an old form of treatment for active TB infection.
- The principle involved deliberate and permanent collapse of the affected lung. TB organisms are obligate aerobes and the collapsed lung receives no oxygen, thus starving the infection.
- There are two main types of thoracoplasty.
  - Plombage – the placement of inert foreign bodies within the hemithorax collapsing the affected lung.
  - Rib excision with lung collapse.

## Clinical features

- Many are asymptomatic.
- Complete unilateral thoracoplasty may be associated with dyspnoea or chest discomfort.

## Radiological features

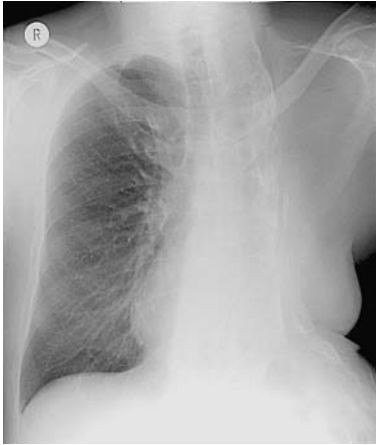- **CXR**
  - **Plombage**
    - Radio-opaque or radiolucent well-circumscribed densities within the affected lung, usually the lung apex. The appearance often looks like ‘ping pong balls’. Other inert substances may be used.
    - This may be associated with adjacent rib anomalies or absent ribs.
  - **Unilateral thoracoplasty**
    - Associated with more extensive rib anomalies/ rib excision.
    - The whole hemithorax is small with no significant aerated lung present.

## Differential diagnosis

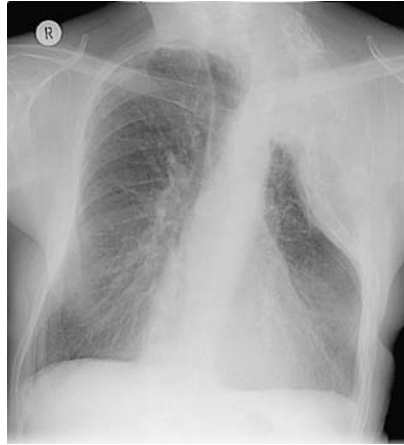- Congenital anomalies including neurofibromatosis rarely resemble the appearances of thoracoplasty.

## Management

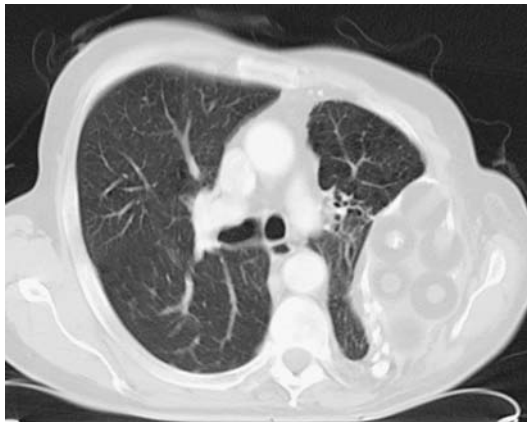- No active treatment required.



**Thoracoplasty.**



**Thoracoplasty with  
plombage.**



The lucite balls clearly seen in the thoracoplasty cavity.



## Thymus – malignant thymoma

### Characteristics

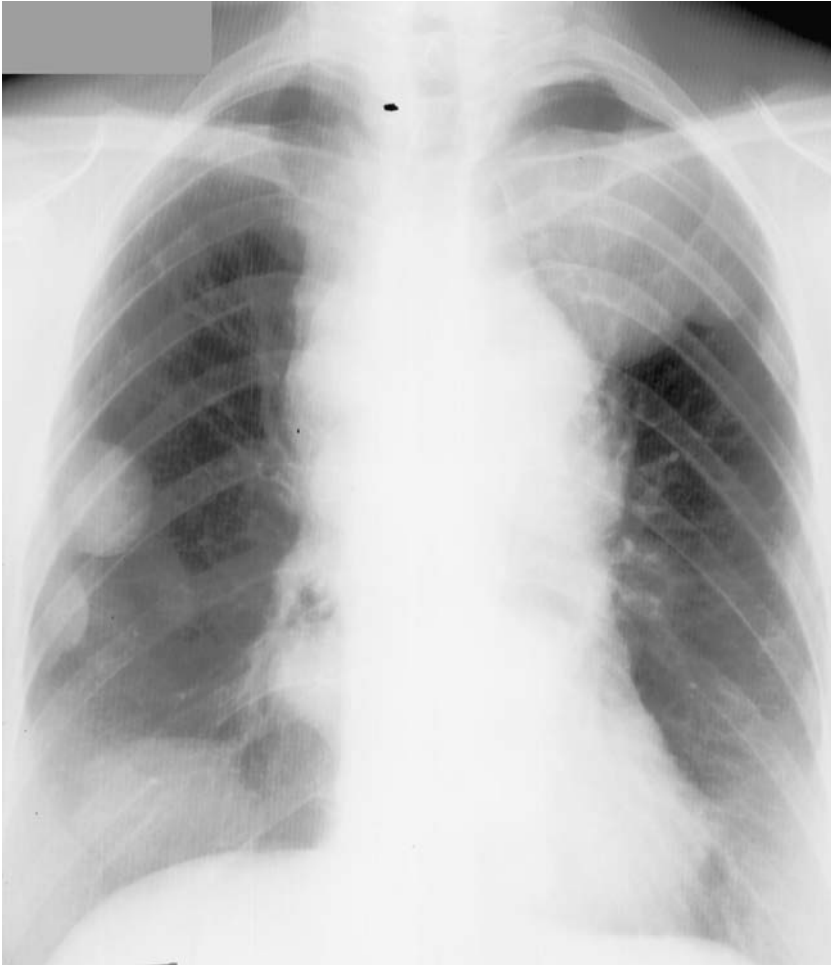
- Most common primary neoplasm of the anterior superior mediastinum.
- They are lymphoepithelial neoplasms and may be benign or malignant (30%).
- Demonstration of malignancy is based on behaviour rather than histological appearance.
- Presentation usually in middle age.
- Strong association with myasthenia gravis (35% of patients with a thymoma have myasthenia gravis).
- Other associations include red cell aplasia, hypogammaglobulinaemia and paraneoplastic syndromes.
- The malignant disease can spread to the mediastinum and pleura invading mediastinal and intrathoracic structures.

### Clinical features

- Asymptomatic (50%) – incidentally picked up on CXR.
- Chest pains, dyspnoea, cough.
- Stridor, hoarse voice, dysphagia.
- SVC obstruction.
- Sweats, weight loss.
- Associated myasthenic symptoms.

### Radiological features

- **CXR** – round/ovoid anterosuperior mediastinal mass (may be difficult to visualise). Widening of the mediastinum. Calcification may be present. Pleurally based metastatic masses may be present.
- **CT** – usually a homogeneous soft tissue mass in the anterior mediastinum with uniform enhancement. There may be cystic changes, patchy calcification and invasion of the mediastinal fat and other mediastinal structures. Pleural metastatic soft tissue masses may be present.
- **MRI** – similar appearances and findings to CT. However, it may allow clearer demonstration of soft tissue invasion.



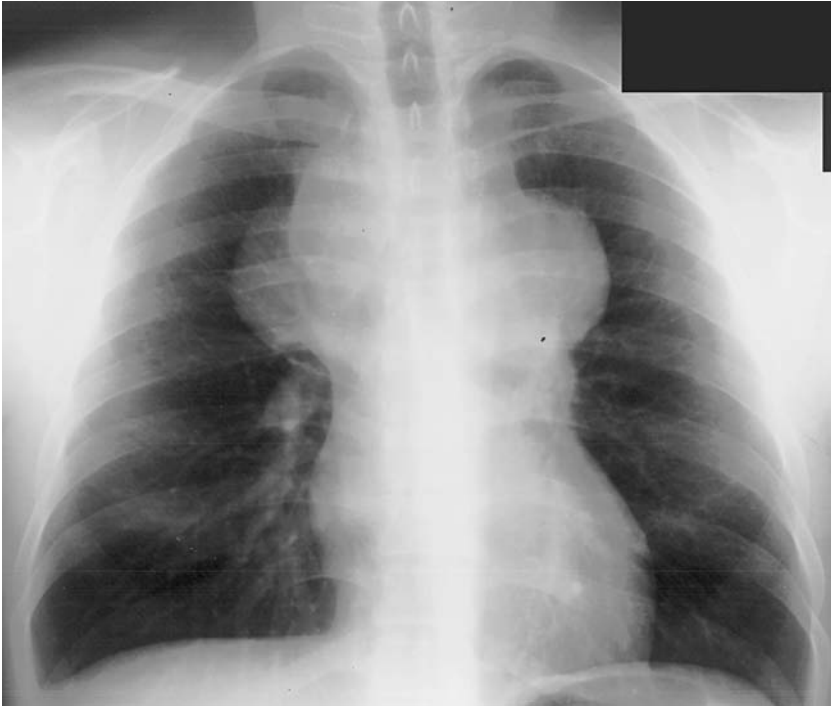**Malignant thymoma.** Large left superior mediastinal mass, with multiple right-sided pleural masses encasing the right hemithorax. Multiple pleural masses are a feature of malignant thymomas.

## Differential diagnosis

- Anterior mediastinal mass
  - Lymph nodes
  - Teratoma
  - Thyroid
  - Thymic carcinoma.

## Management

- Surgical resection and adjuvant radiotherapy.
- Surveillance following surgery.
- 50% five-year survival if stage-4 malignant thymoma.
- >90% five-year survival if stage-1 malignant thymoma.



**Malignant thymoma.** Soft tissue density superior to mediastinal mass. The paratracheal stripe and hilar vessels are visible indicating that the mass is most likely sited in the anterior mediastinum.

# Thymus – normal

## Characteristics

- A normal thymus is visible in 50% of neonates of 0–2 years of age.
- The size and shape of the thymus are highly variable.
- Thymic hyperplasia and subsequent visualisation of the thymus occur in a number of conditions:
  - Hyperthyroidism (most common).
  - Rebound in children recovering from illness (e.g. post chemotherapy).
  - Myasthenia gravis.
  - Acromegaly.

## Clinical features

- No symptoms from a normal or hyperplastic thymus.

## Radiological features

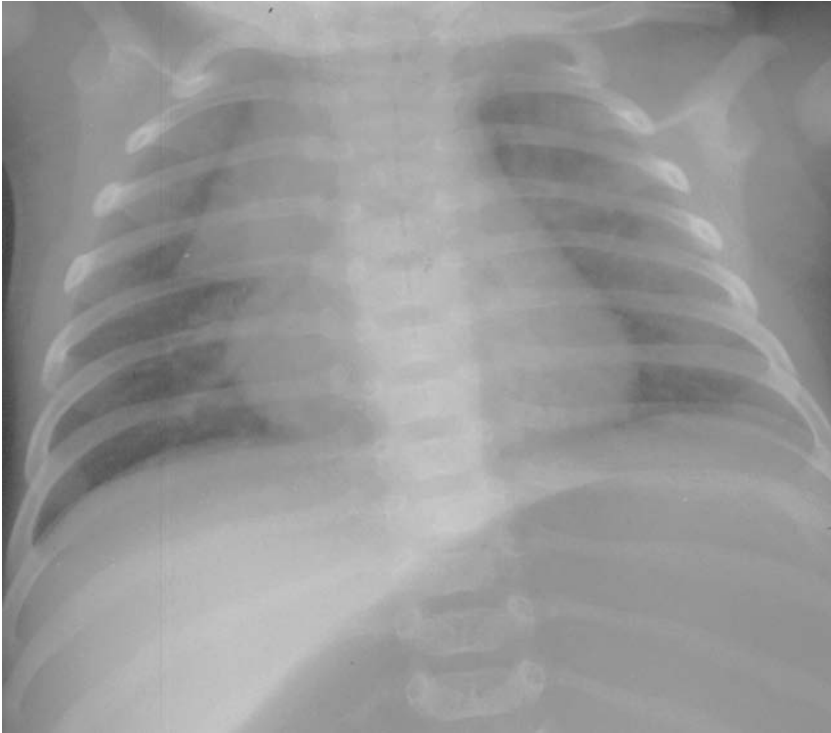- Visualisation in neonates and rarely children.
- **CXR**
  - Triangular density extending from the superior mediastinum ('sail sign'). There is an indentation at the junction of the thymus and heart. There may be a wavy rippled border to the thymus.
  - Elevation of the thymus away from the mediastinum, with clear visualisation of the medial and lateral borders of the thymus, raises the possibility of a pneumomediastinum.

## Differential diagnosis

- Superior mediastinal mass
  - Lymphoma
  - Teratoma
  - Thymoma (rare)
  - Cystic hygroma.
- Upper lobe collapse or consolidation in children can often mimic a normal thymus.

## Management

- No active treatment required.



**Normal thymus.** This demonstrates the classical **'sail-sign'** of normal thymic tissue in a neonate. The normal thymus usually undergoes complete atrophy by adolescence.

# Tuberculosis

## Characteristics

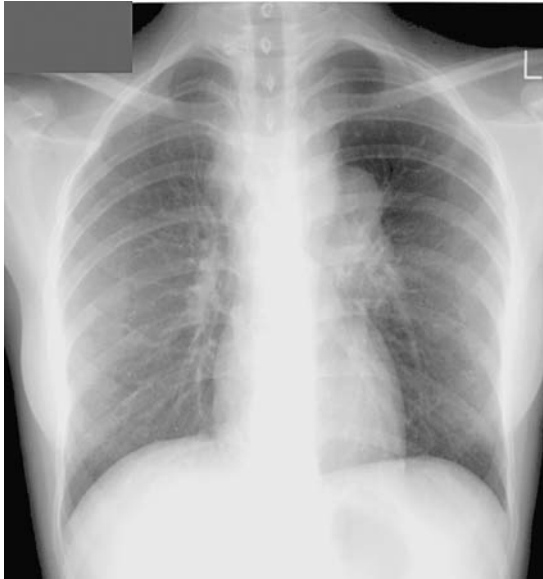
- *Mycobacterium tuberculosis* (TB) is an aerobic bacillus.
- High cause of morbidity and mortality worldwide.
- Rising incidence due to increasing susceptibility and antibiotic resistance.
- Susceptible groups include immunocompromised, elderly, alcoholics and immigrants from third world countries.
- TB predominately affects the lungs but spread via lymphatics and blood vessels allows dissemination to other organs (pericardium, gastrointestinal and genitourinary tracts, bone and the CNS).
- Diagnosis may sometimes be difficult – direct sputum/tissue microscopy or culture. Immunological skin testing using Heaf or Mantoux tests. Unfortunately the patient needs to be able to host an immune response to aid diagnosis. In some patients this response is absent due to immunosuppression.
- Three main types of pulmonary tuberculous infection:
  - Primary.
  - Post primary or reactivation.
  - Miliary.
- A tuberculoma represents a focal mass lesion of uncertain tuberculous infective activity.

## Clinical features

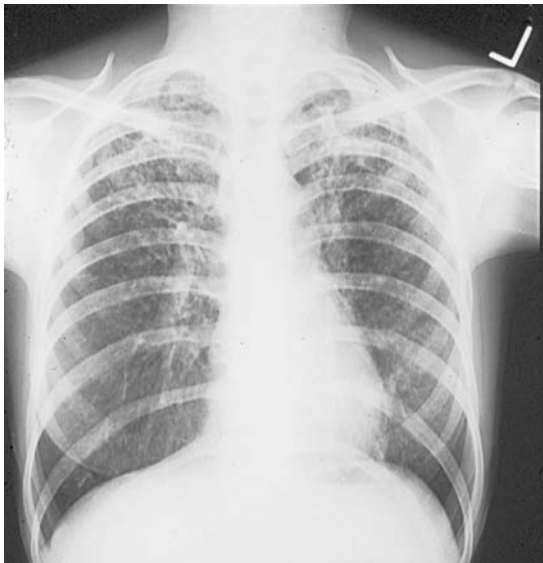- Cough, SOB, sputum or haemoptysis.
- Weight loss, fatigue and malaise.
- Pyrexia and night sweats.
- Progressive, rapid and debilitating symptoms suggest miliary spread of the infection.
- Always consider the diagnosis in at-risk groups and patients who fail to respond to standard antibiotic regimes.

## Radiological features

- **CXR**
  - **Primary**
    - May be active or inactive infection.
    - Scarring and calcification (lung and lymph nodes) suggest inactive disease.



**Primary TB.** Right paratracheal and left hilar adenopathy.



**Post primary TB.** Linear parenchymal streaking extending into both apices, with associated retraction of both hila. The findings are of bilateral upper lobe fibrosis.



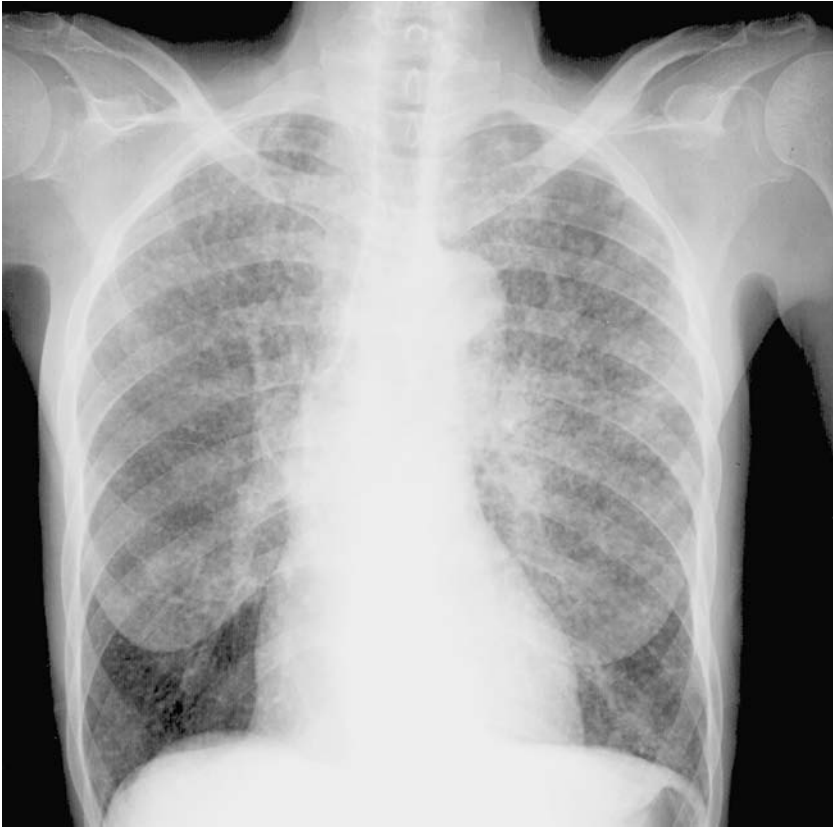- Consolidation, small focal nodularity, lymphadenopathy and effusions suggest active infection.
- A Ghon focus is a peripheral area of lung consolidation.
- **Post primary**
  - Again may be active or inactive.
  - Focal scarring and lung distortion  $\pm$  cavitation. Usually in upper lobes.
  - Adenopathy and effusions are much less common.
  - Fungal infections may develop in active cavities (mycetomas).
- **Miliary infection**
  - Multiple small discrete widespread pulmonary nodules.
- **Reactivation of TB** can be difficult to diagnose. Comparison with old films for changes in appearance is helpful. Increased soft tissue and cavitation suggest active infection.
- **CT and HRCT** – demonstrate occult soft tissue masses, cavitation and lymphadenopathy. Other features include reticulonodular change and ‘tree-in-bud’ appearances in keeping with endobronchial disease. The lymph nodes are characteristically necrotic on contrast-enhanced studies.

## Differential diagnosis

- Other infections including non *Tuberculosis mycobacterium*.
- Lymphoma.
- Sarcoid.
- Miliary metastases may mimic miliary TB disease.

## Management

- Current treatment is 6–12 months of a quadruple antibiotic regime.
- Patient contacts should be screened for active disease and treated where appropriate.
- Always consider reactivation of TB in susceptible groups, and symptomatic patients previously exposed to TB.



**Miliary TB.** Multiple tiny nodules scattered throughout both lungs.

# Varicella pneumonia

## Characteristics

- Usually presents in adults.
- Severe chest infection which may require hospitalisation.
- Vesicular rash and patchy diffuse lung changes.
- The pneumonia can heal with tiny calcified granulomata throughout the lungs. These have a characteristic appearance on CXR and should be recognised and not confused with alternative diagnoses.

## Clinical features

- Acute infection – cough, sputum, fever, malaise, dyspnoea and vesicular rash.
- Post infection – asymptomatic.

## Radiological features

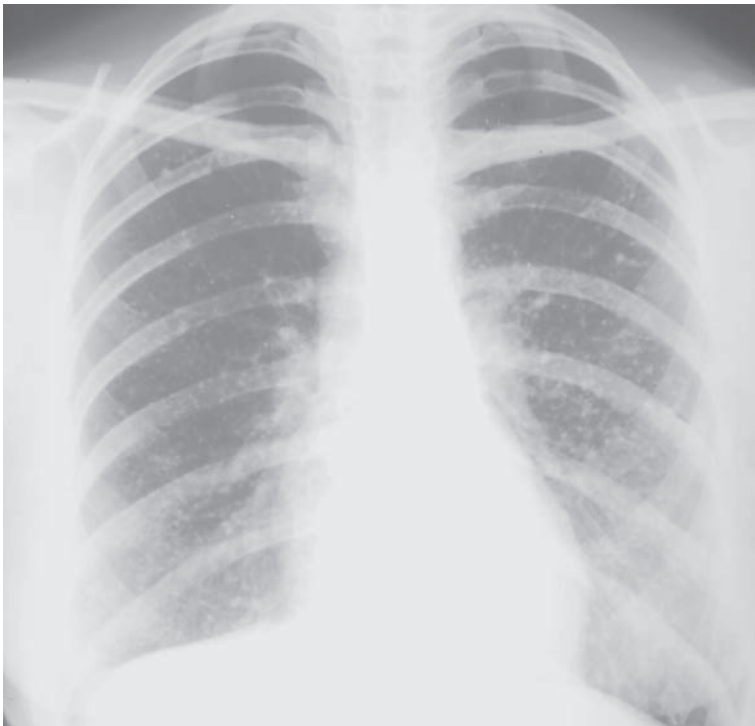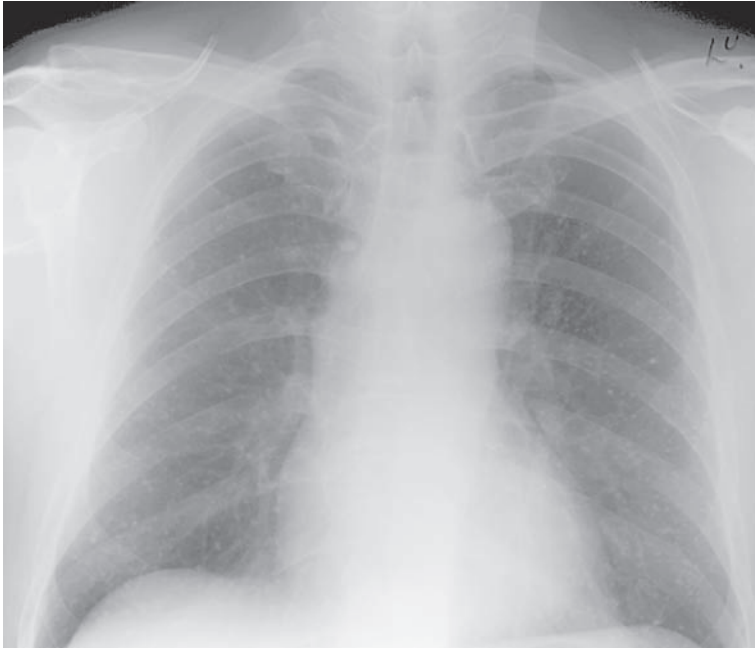
- **CXR**
  - Acute infection – patchy, diffuse consolidation often coalescing at the bases and hila. Lung nodules may be present in 30%.
  - Post infection – tiny discrete calcified granulomata throughout the lungs.

## Differential diagnosis

- Acutely – any bacterial or fungal pneumonia.
- Post infection – the appearances may rarely mimic miliary TB or calcified metastases (e.g. thyroid). Clinical correlation is diagnostic.

## Management

- Acute infection
  - ABC.
  - Oxygen.
  - May require antiviral therapy and occasionally steroids.
  - May require ventilatory support.
- Post infection
  - No active management.



**Previous varicella pneumonia – two cases.** Multiple calcified nodules scattered throughout both lungs.

# Wegener's granulomatosis

## Characteristics

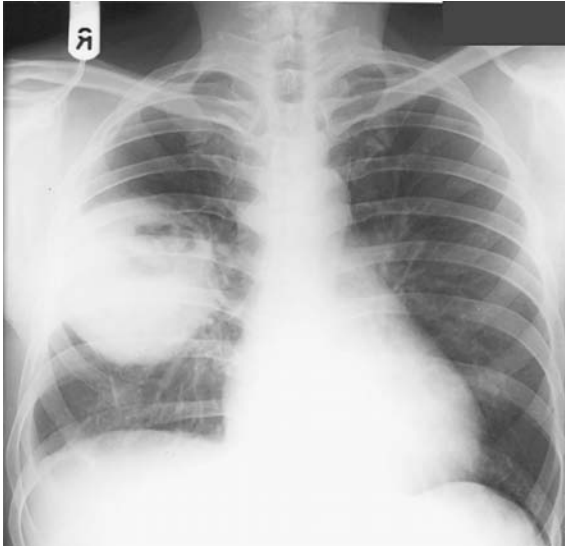
- This is a multisystem disease of unknown aetiology.
- Characterised by necrotising vasculitis of medium and small-sized vessels, tissue necrosis (which may be granulomatous) and inflammation which is both acute and chronic.
- Classically involves the lungs (95%), kidneys (85% – glomerulonephritis) and paranasal sinuses (90%).
- Other organs can be involved (eyes, skin, joints, CNS, GI tract and heart).
- M > F 2:1.
- Presents in childhood or old age (70s).
- c-ANCA positive (96% sensitive). Beware active TB infection, which can cause mild serum elevation of this antibody, sometimes making diagnosis difficult.

## Clinical features

- Variable presentation
- Stridor (tracheal inflammation).
- Cough, haemoptysis.
- SOB, fever, chest pain.
- Sinus pain and purulent sputum.
- Epistaxis, saddle-shaped nose (destruction of the nasal cartilage).
- Joint pains.
- Weight loss, abdominal pains, diarrhoea.
- Cutaneous rash and nodules.
- Proptosis.
- Peripheral and central neuropathies.

## Radiological features

- **CXR** – pulmonary nodules of varying size. They can cavitate and can occur anywhere in the lung. Patchy, sometimes extensive consolidation or ground glass change (which may reflect pulmonary haemorrhage). Pleural effusions in one-third.
- **CT** – confirms **CXR** appearances. The nodules may have a rim of ground glass around them (halo sign secondary to infarction). In addition there may be peripheral pleurally based wedge shaped infarcts. There may also be tracheobronchial narrowing due to inflammation. Lymphadenopathy is not a feature.



**Wegener's granulomatosis.** Large cavitating lung mass in the right mid zone.

## Differential diagnosis

- Churg–Strauss syndrome – this is asthma associated with a small vessel vasculitis, p-ANCA positive.
- Rheumatoid arthritis (RA) – some forms of RA can mimic Wegener's granulomatosis.
- Infection – particularly fungal infections, TB or septic emboli from disseminated infection.
- Cryptogenic organising pneumonia.
- Metastatic disease.

## Management

- Treatment with corticosteroids.
- Long-term therapy with cytotoxic drugs (e.g. cyclophosphamide).
- Renal disease may lead to renal failure requiring dialysis and ultimately consideration for renal transplantation.

# Westermarck's sign

## Characteristics

- This represents a focal area of oligoemia usually due to a distal pulmonary embolus. It is seen in 5% of pulmonary embolic patients.
- Rarer causes including tumour compression and inflammatory vasculitis can produce similar radiographic appearances.

## Clinical features

- SOB.
- Cough, haemoptysis.
- Pleuritic chest pain.
- Deep leg vein thrombus.
- Hypoxia.
- Hypotension.
- Collapse.

## Radiological features

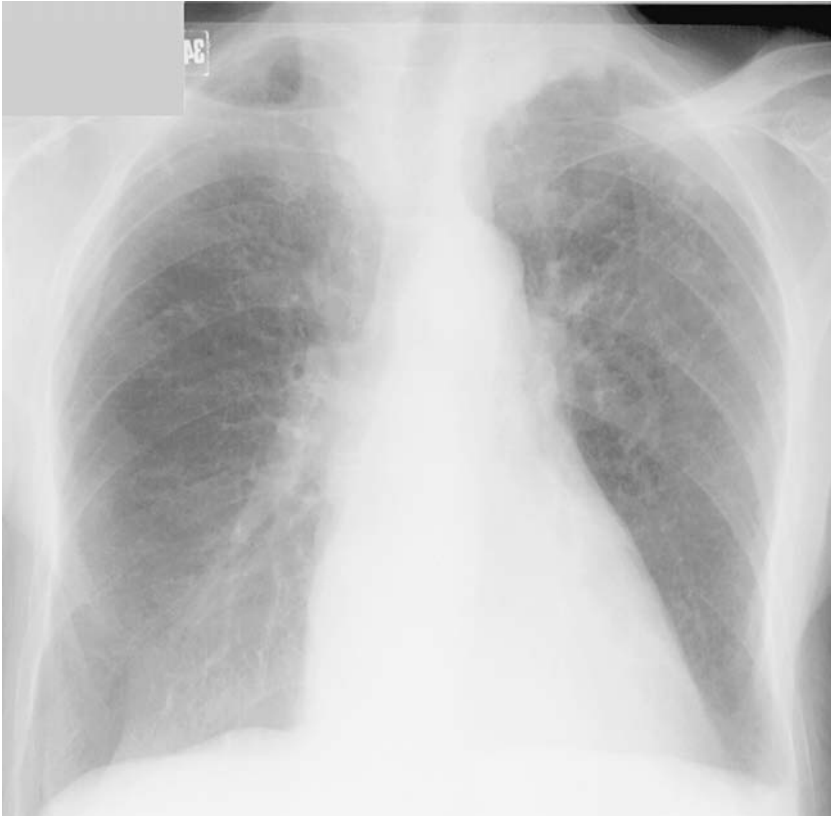- **CXR** – wedge shaped area of low attenuation
  - Other radiographic features of pulmonary embolic disease include:
    - Fleischner's sign – local widening of pulmonary artery due to distension from clot.
    - Hampton's hump – segmental pleurally based wedge shaped opacity representing a pulmonary infarct.
- **CT (CTPA)** – Filling defects within the pulmonary arteries.

## Differential diagnosis

- Occasionally focal areas of apparent lucency are demonstrated in areas adjacent to pulmonary consolidation or "ground glass" change. These areas of increased attenuation may represent infection, fluid or pulmonary haemorrhage and are abnormal. The apparent lucent area is spared lung and actually represents the normal lung.

## Management

- ABC.
- Oxygen.
- Anticoagulation if PE is confirmed.



**Westermark sign – Pulmonary embolus.** A large part of the right hemithorax is hypodense due to oligoemia, secondary to vasoconstriction distal to an embolus